

LONGTERM FOLLOW UP OF AN ARTIFICIAL ENDOTHELIAL LAYER FOR TREATMENT OF CHRONIC CORNEAL EDEMA

G. U. Auffarth ¹, H.-S. Son ¹, O. Daphna ²,
A. L. Marcovich ³, V. A. Augustin ¹



¹ International Vision Correction Research Centre (IVCRC),
The David J Apple International Laboratory for Ocular Pathology
University-Eye-Clinic Heidelberg, Germany, Chair: G.U. Auffarth, MD, PhD, FEBO

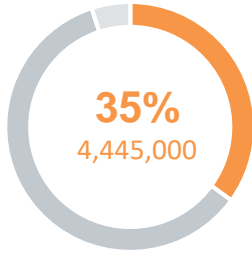
² EyeYon Medicals, EyeYon Medicals, Nes Ziona,

³ Dept. of Ophthalmology, Kaplan Medical Center, Rehovot, Israel

Financial Disclosures: Acufocus¹, Alcon^{1,2,3,4}, Alimera^{1,2,3}, J & J^{1,2,3,4}, Bausch+Lomb^{2,3}, Biotech^{1,3}, Carl Zeiss
Meditec^{1,2,3}, Contamac¹, Hoya^{1,2,3}, Kowa^{1,2,3}, Oculentis^{1,2,3}, **Oculus**^{1,2,3,4}, Physiol¹, Presbia^{2,3,4}, Rayner^{1,2,3}, Santen^{1,2,3}, SIFI^{1,2,3}, Ursapharm^{1,2,3}

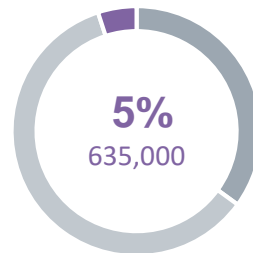
1 = Research Funds; 2 = Travel expenses; 3 = Lecture honorarium; 4 = Consulting

Synthetic Solutions for Corneal Tissue Replacement



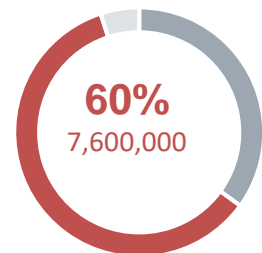
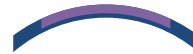Perforating Keratoplasty (PKP)

Complete Replacement of Corneal Tissue



Deep Anterior Lamellar Keratoplasty (DALK)

Replacement of Anterior Cornea



Endothelial Keratoplasty (EK)

Replacing endothelial Descement-Lamella



Product Description – EndoArt®

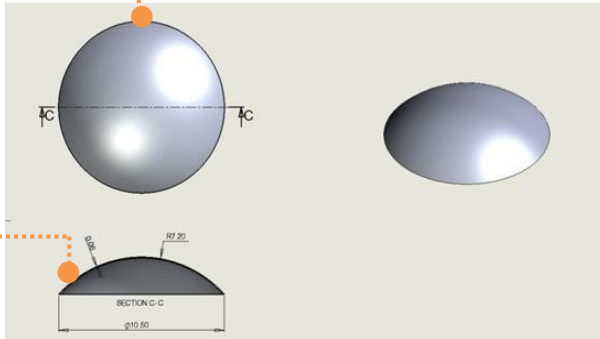
Artificial endothelial layer for treatment of chronic corneal edema

Working Principle

Impeding transfer of aqueous humor into the cornea and decreasing chronic corneal edema

6.00 mm in diameter

Dome Shaped



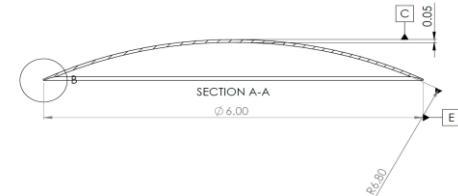
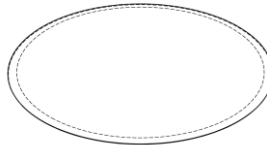
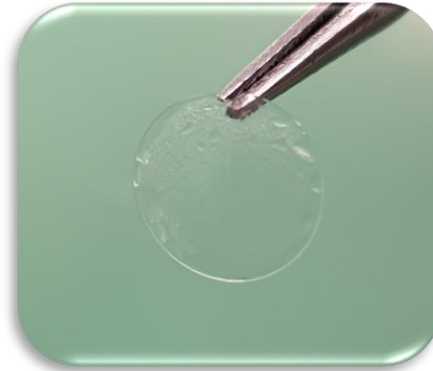
Optically clear

Flexible

Artificial Endothelial Layer - EndoArt®

Main Characteristics

- Dome shaped, flexible
- Diameter: 6.0 mm
- Curvature: 6.8 mm
- Thickness: 50 μm
- Optically clear
- Made of Contamac™ Ci26 copolymer (hydrophilic material)
- Bio-compatible and bio-stable
- Manufactured using a lathe cut machinery
- Moist Heat sterilization (supplied sterile)



The EndoArt®

Artificial endothelial Layer - EndoArt®

Case 1: Date of Implantation 18.06.2019

58-years-old female patient:

OD:

Status after Phako and IOL(extern)

Status after Endophthalmitis

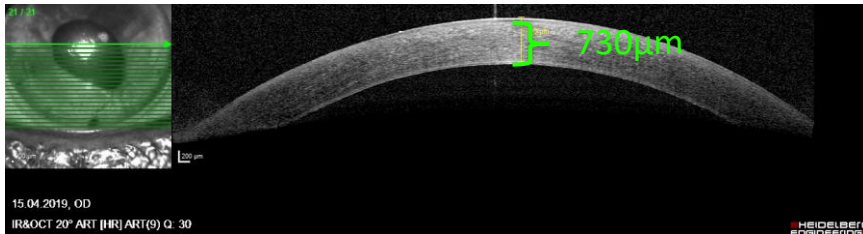
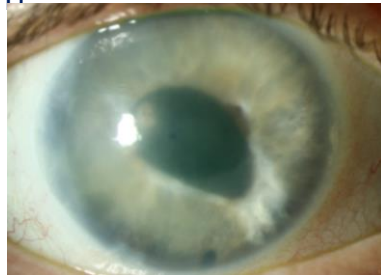Status after ppVE

CE Decompensation

Optic atrophy, Status after DMEK

incl. Multiple Rebubbling

Bullous Keratopathy



Case 2: Date of Implantation 18.06.2019

80-years-old male Patient:

OD:

Fuchs corneal Dystrophy

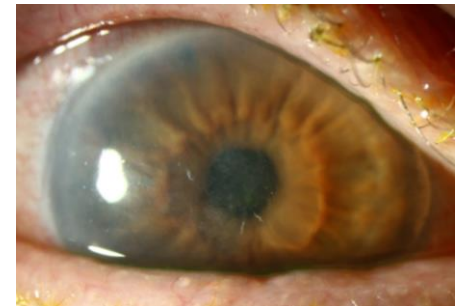
Status after Phako and IOL

Status after DMEK

incl. multiple Rebubbling

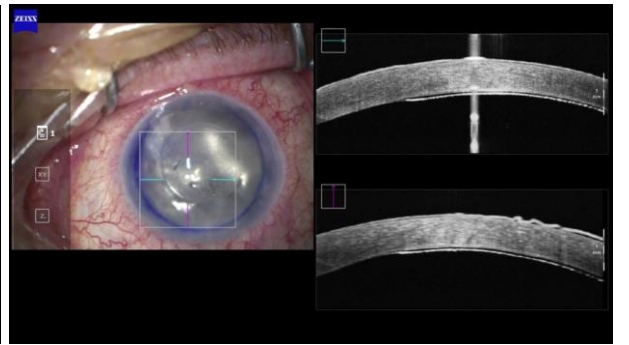
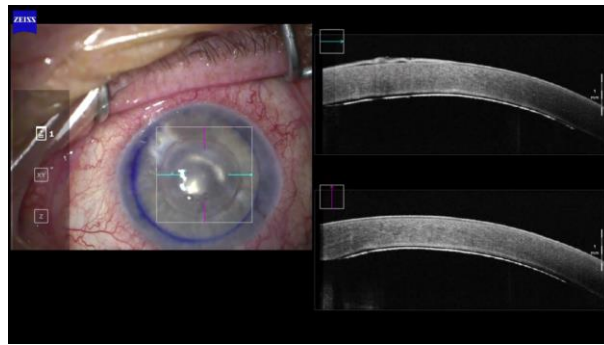
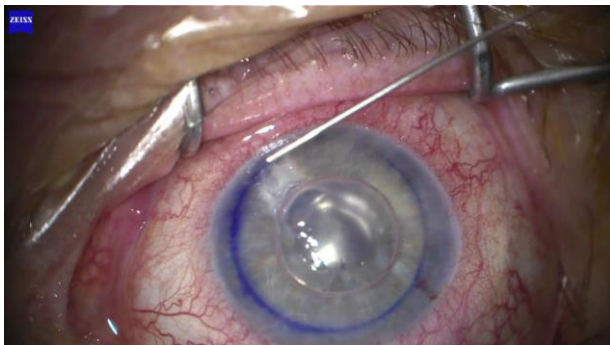
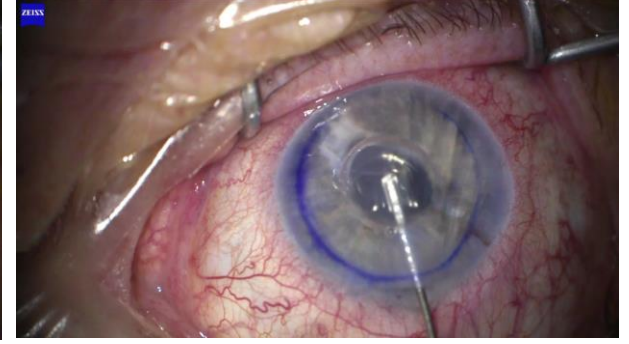
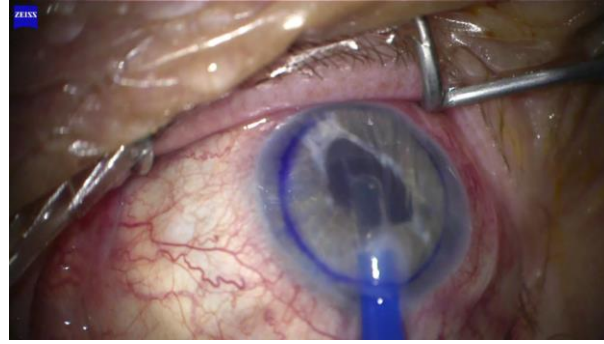
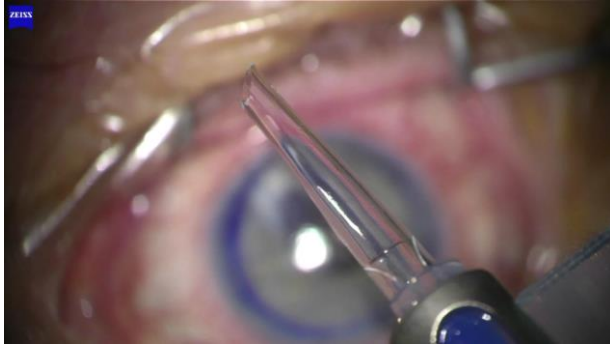
Transplant decompensation

Bullous keratopathy





Implantation: EndoArt® Artificial Endothelial Layer

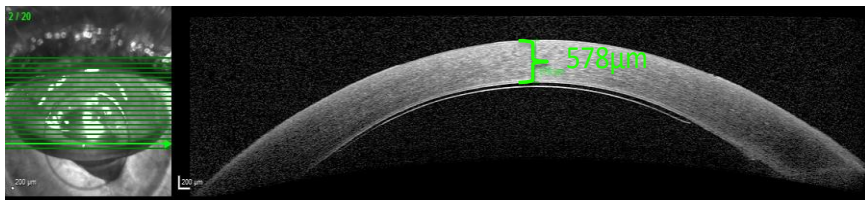
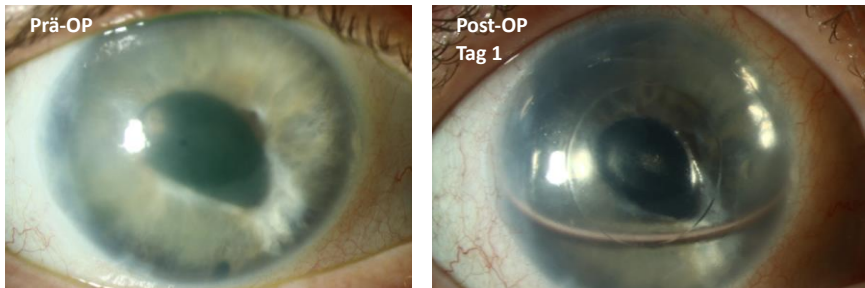


Artificial endothelial Layer - EndoArt®

Case 1:

58-years-old patient:

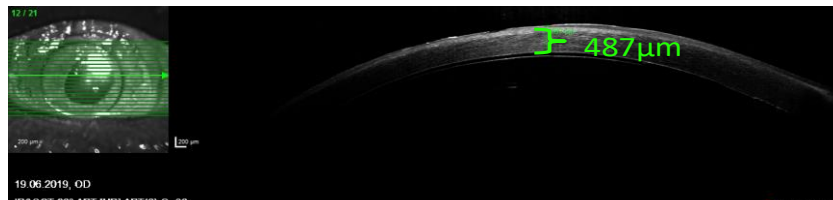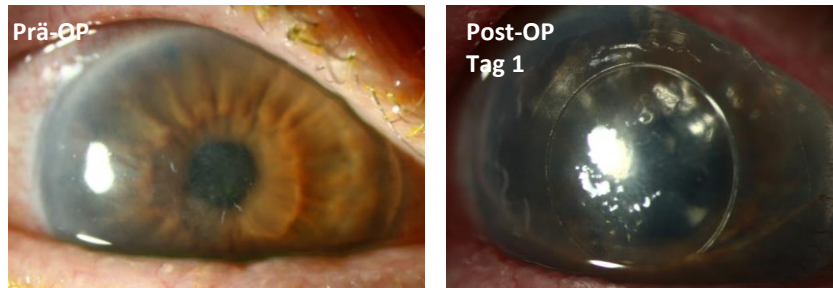
OD: Post-OP Day 1



Case 2:

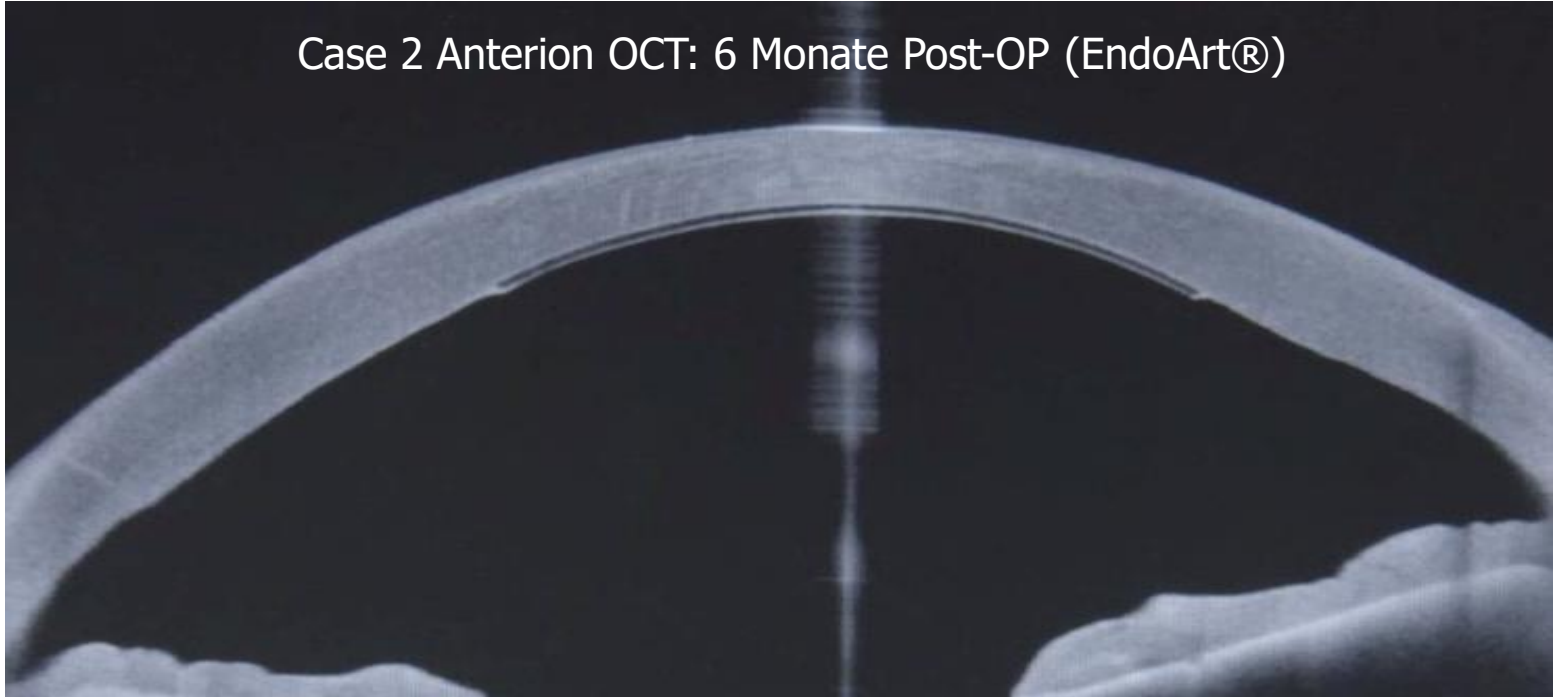
80-years-old patient:

OD: Post-OP Day 1



Artificial endothelial Layer - EndoArt®

Case 2 Anterior OCT: 6 Monate Post-OP (EndoArt®)

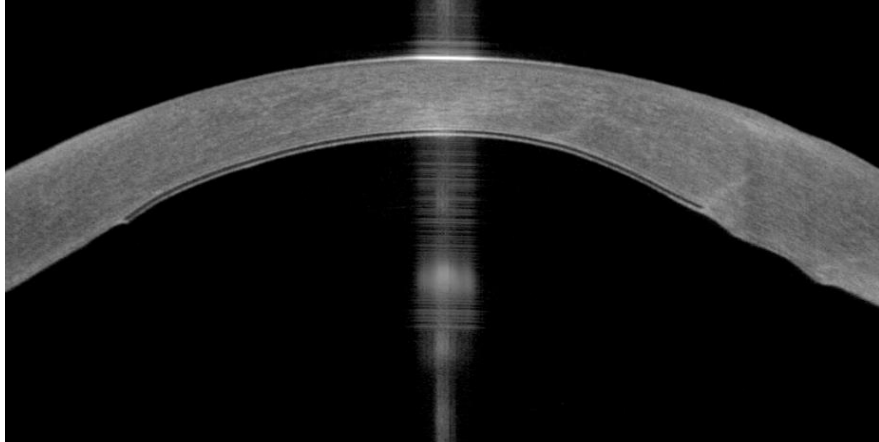


Artificial endothelial Layer - EndoArt®

Case 1:

58-years-old patient


OD: Post-OP 17 Months



Case 2:

80-years-old patient:

OD: Post-OP 13 Months

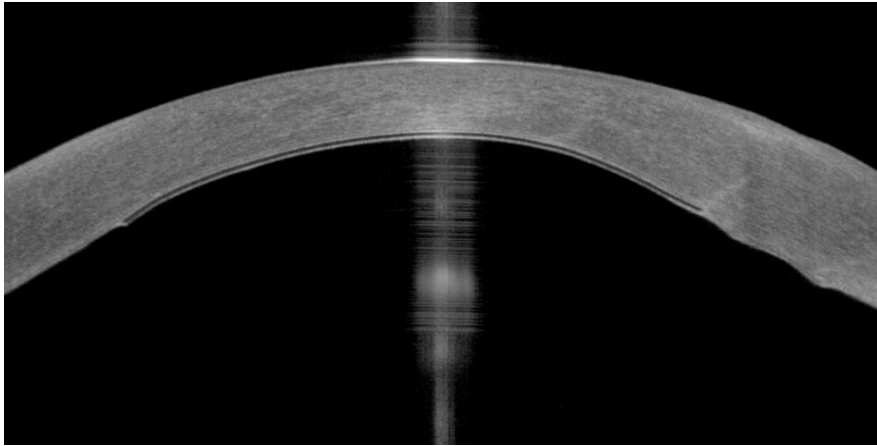


Artificial endothelial Layer - EndoArt®

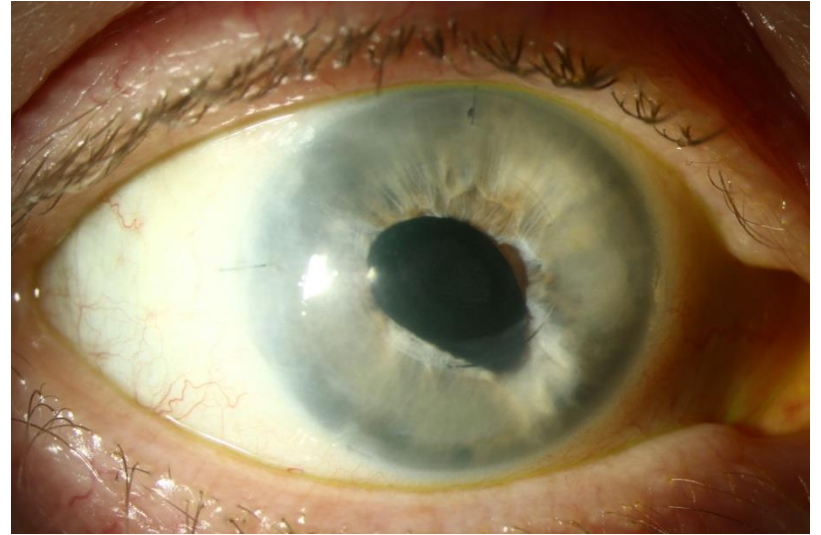
Case 1:

58-years-old patient

OD: Post-OP 30 Months



2,5 Years Post-OP, CCT = 547 μm



2,5 years Post-OP



Conclusion: EndoArt Artificial DMEK Lamella

2+ years Follow up Cases

- Surgery easier than conventional DMEK
- Implant very forgiving in terms of intraoperative handling
- Surgical techniques have been improved and fine tuned
- No implant material degradation
- No immunosuppression therapy necessary
- Corneal swelling effectively reduced
- Pain from bullous keratopathy resolved

General Aspects:

- No waiting list for patient for human tissue
- Removability/Exchangeability
- Lower cost
- Less traumatic surgery
- Ambulatory day case scenario
- Expanding indications for surgery



UNIVERSITY
EYE CLINIC
154 Years
Since 1868



Zertifiziert für
DIN EN ISO
9001:2015



Thank you



Steinbeis-Research Center
The David J. Apple Center
for Vision Research



IVCRC.net
International Vision Correction
Research Center Network