



**2023 ASCRS & OPHTHALMIC
PHOTOGRAPHERS' SOCIETY
(OPS) EXHIBIT**

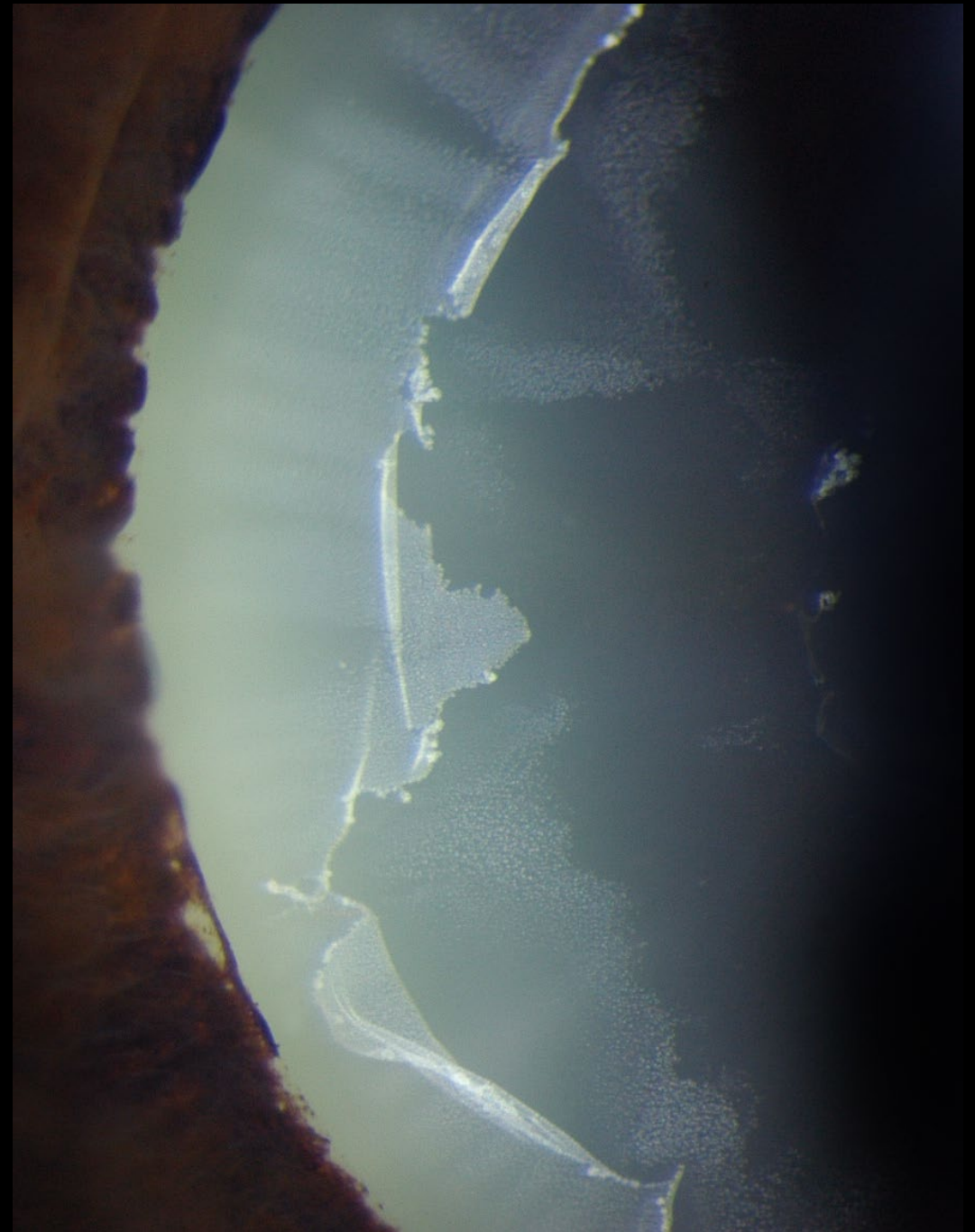
Presented at the 2023 ASCRS Annual Meeting



Best of Show



Pseudoexfoliation of Lens Capsule
Gary Miller CRA, OCT-C

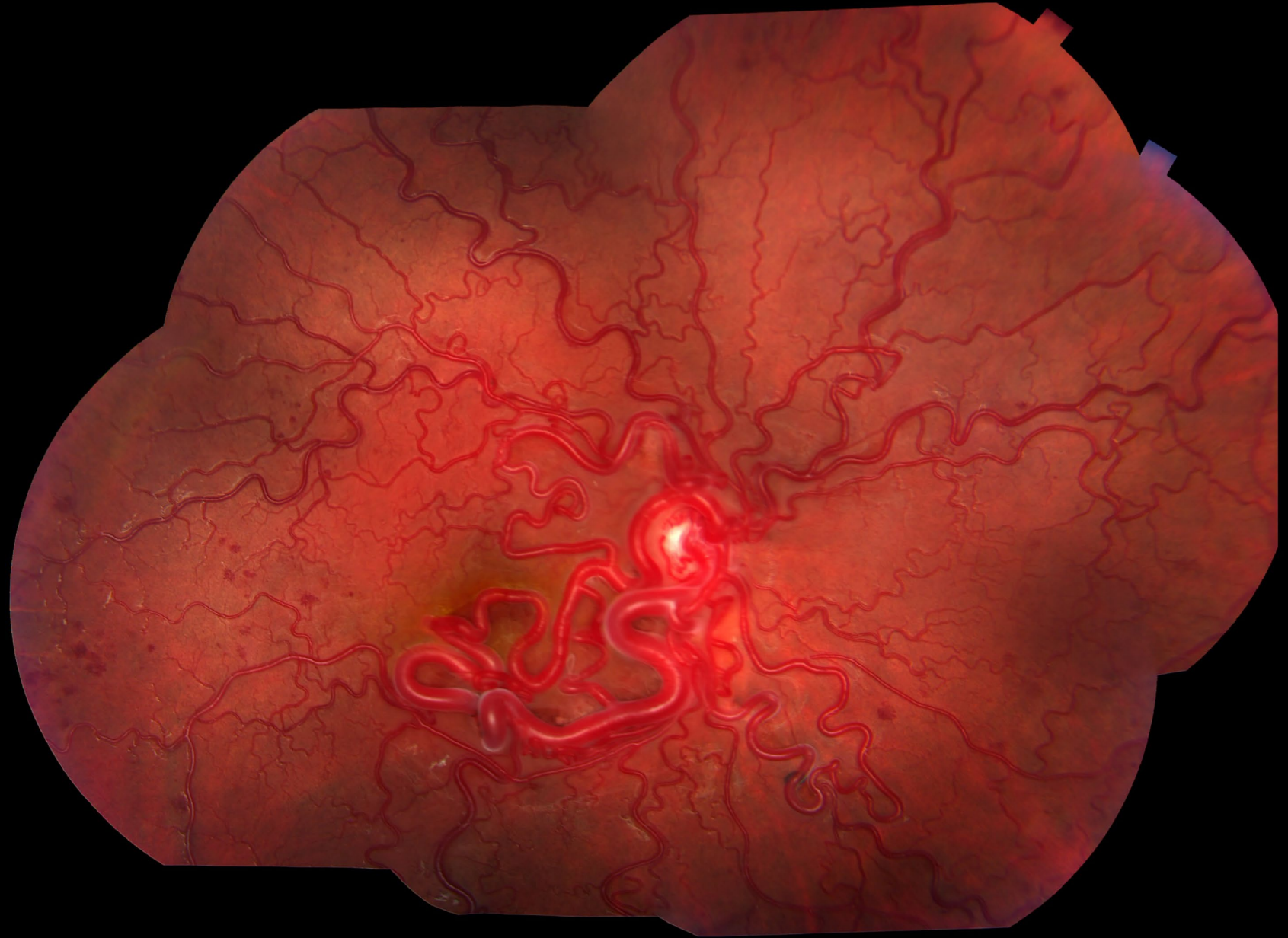



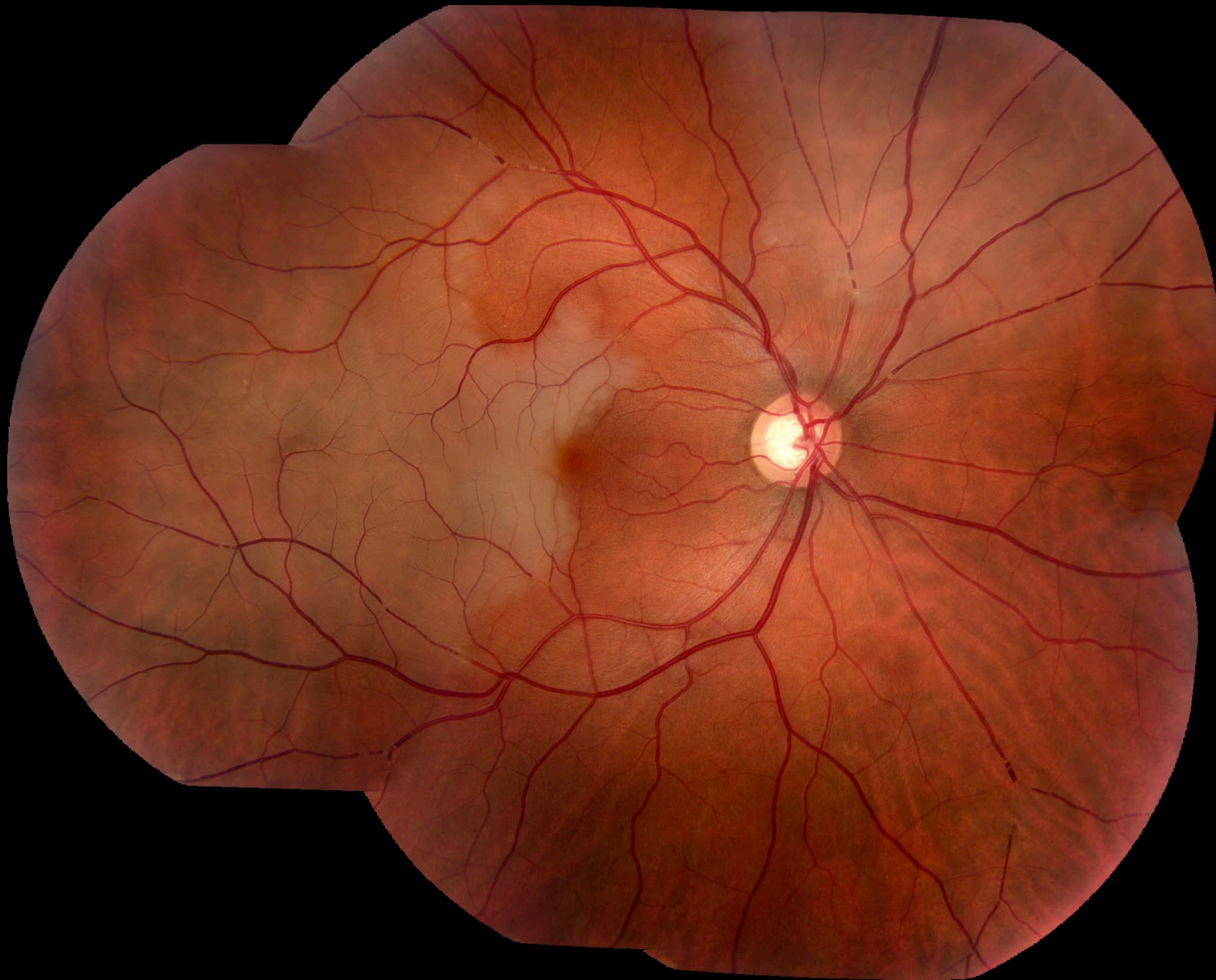
Composite



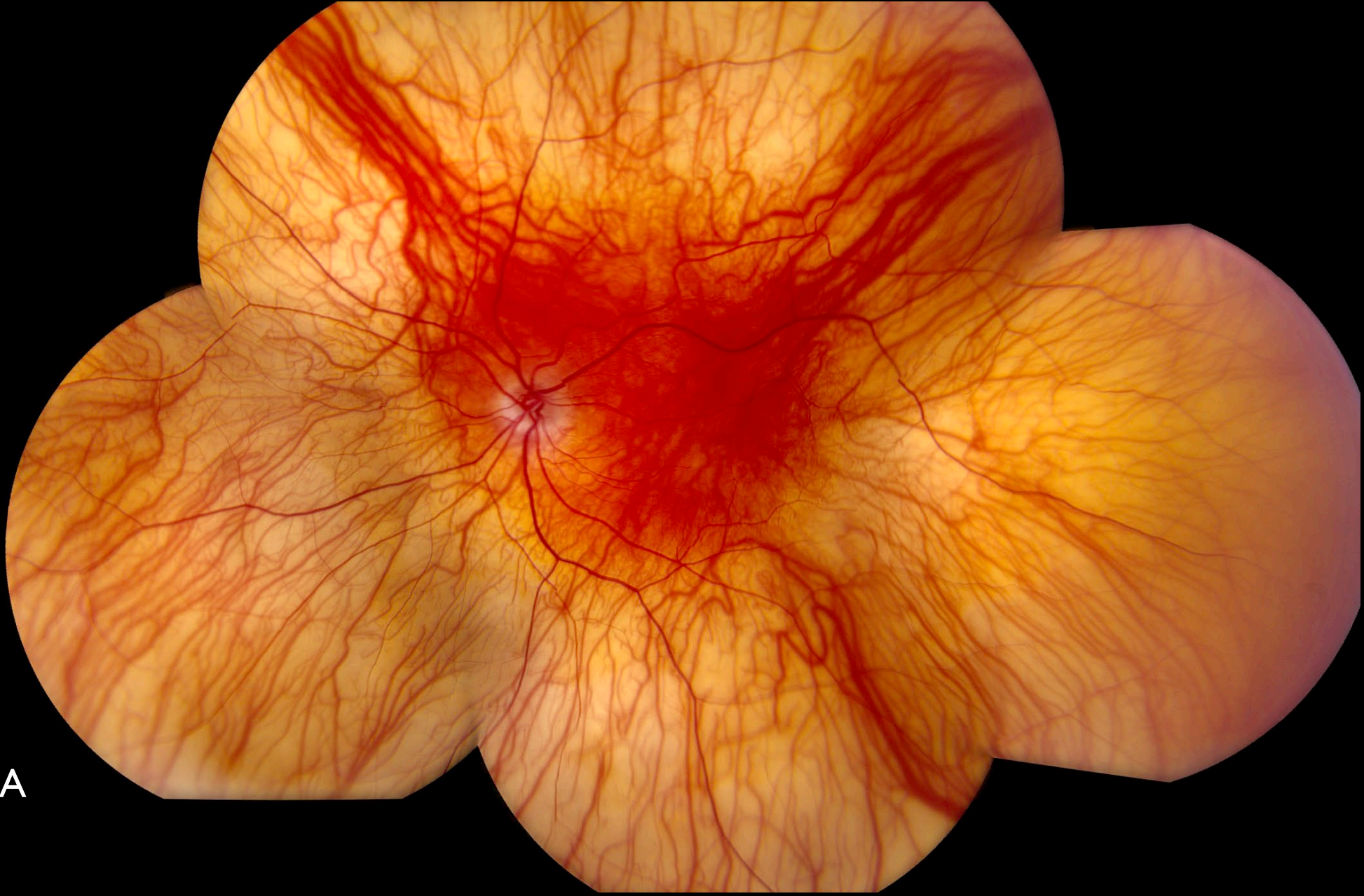
Retinal Detachment
Sousa Jefferson, BEng, COMT



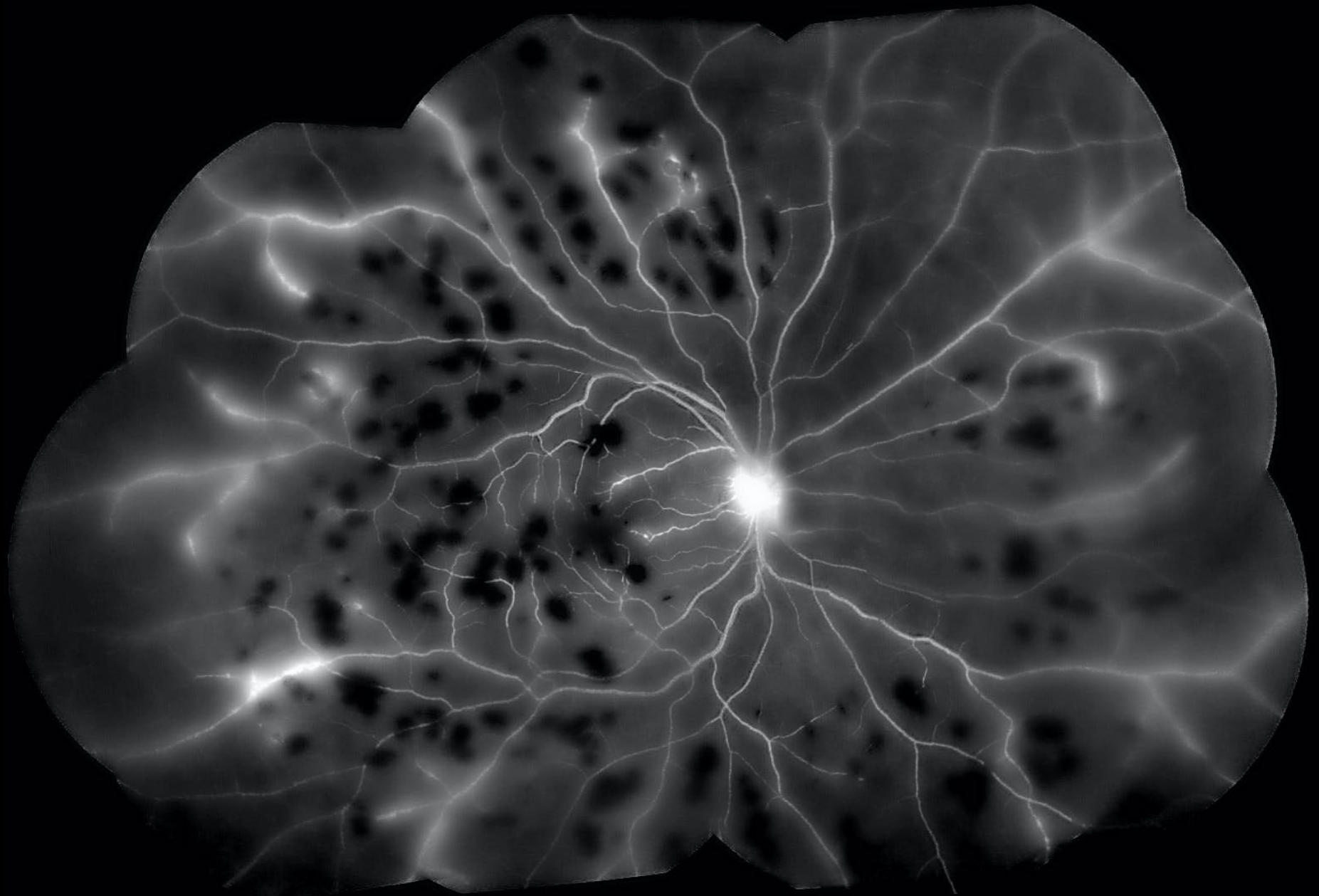
Racemose Angiomatosis
Olivia Rainey, BA, COA, OCT-C



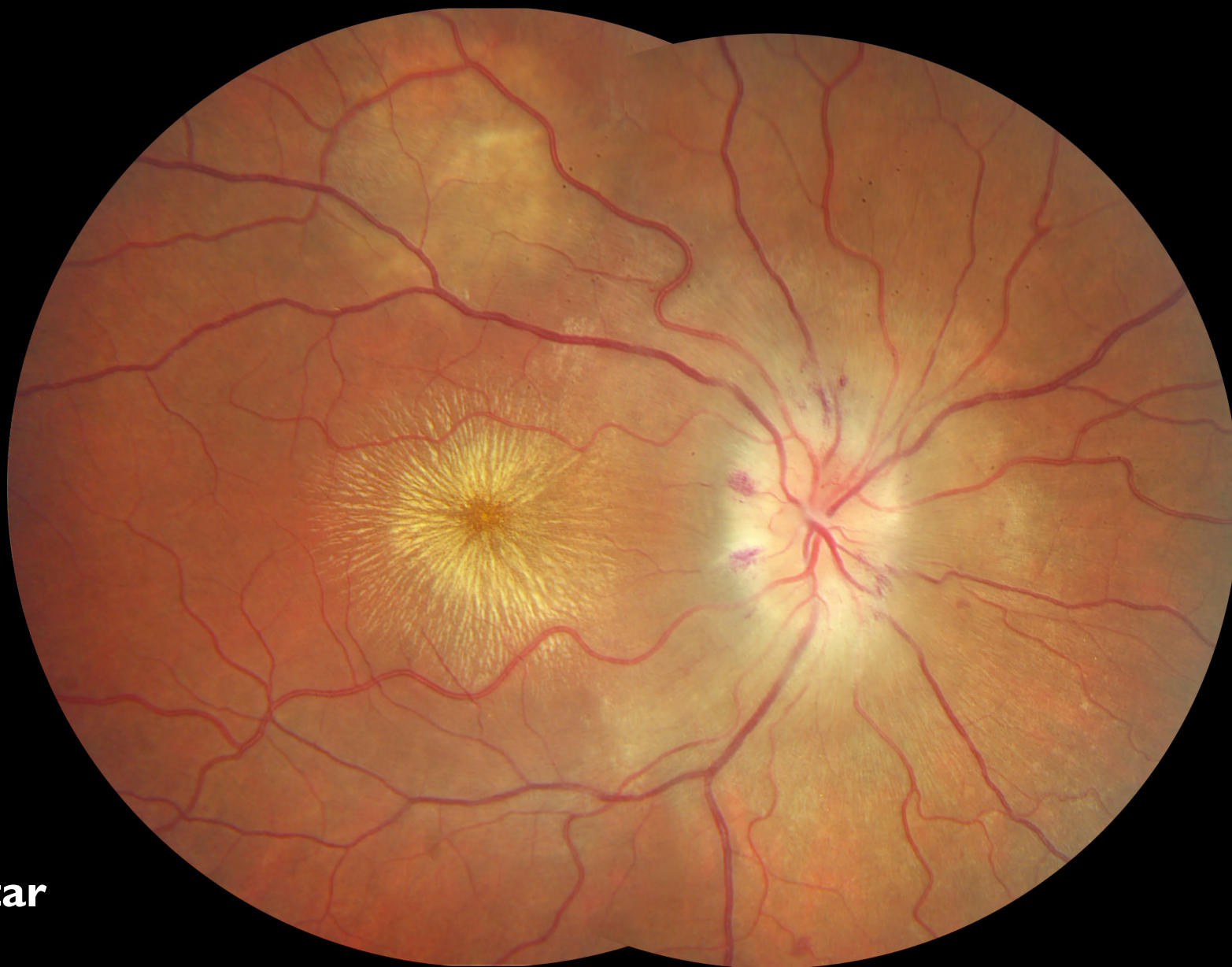Artery Occlusion
Jason Calhoun, COA



Albinism
Jason Calhoun, COA



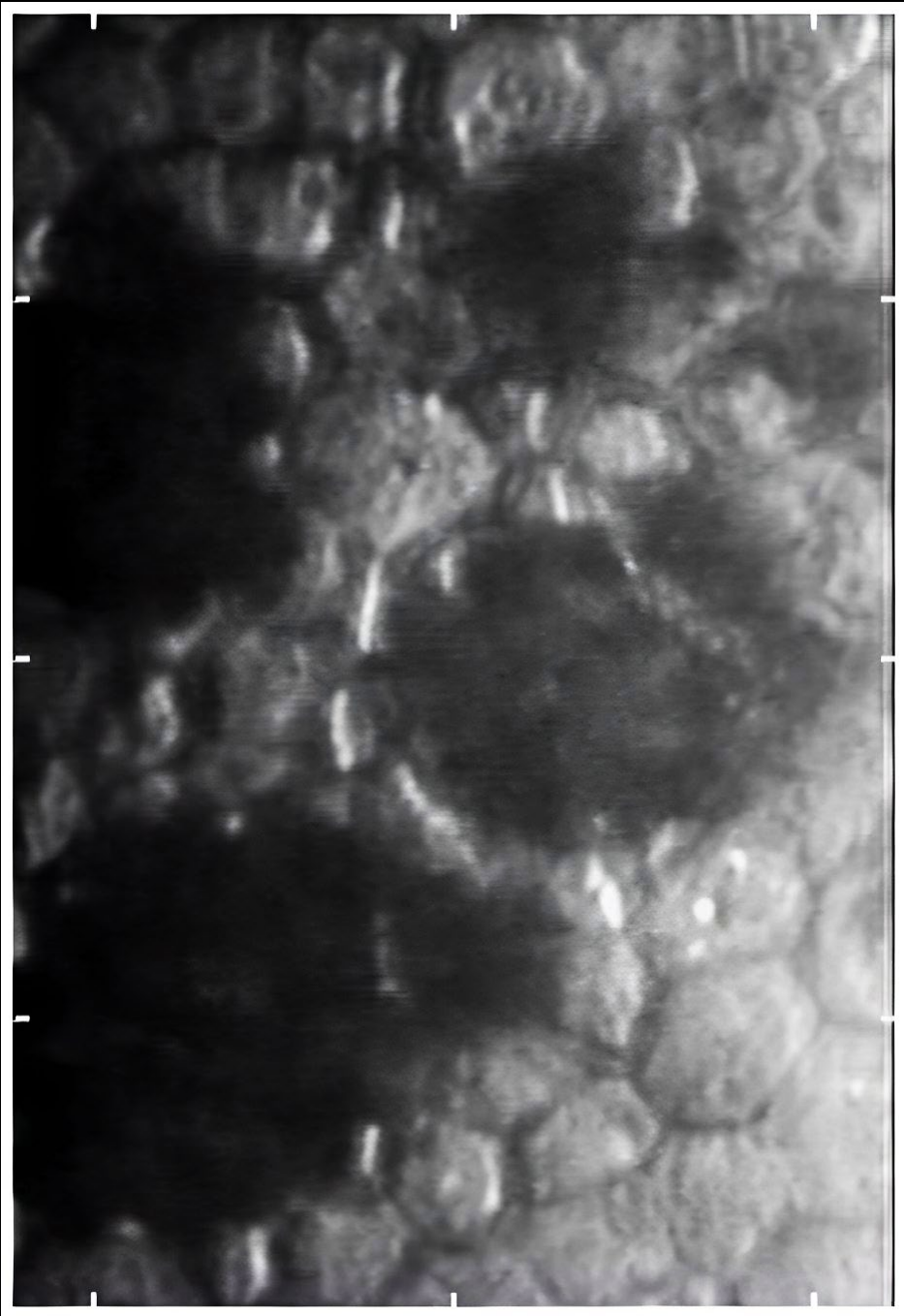
Retinal Vasculitis
Jason Calhoun, COA



Neuroretinitis w/ Macular Star
Sean Grout, OCT-C

A microscopic image of a corneal endothelium, showing a dense, regular arrangement of hexagonal cells. The cells are arranged in a honeycomb pattern, with each cell having a distinct hexagonal shape. The cells are colored in shades of blue and green, with some yellowish-orange spots scattered throughout. The overall appearance is that of a highly organized, single layer of cells.

Corneal Endothelial Photography



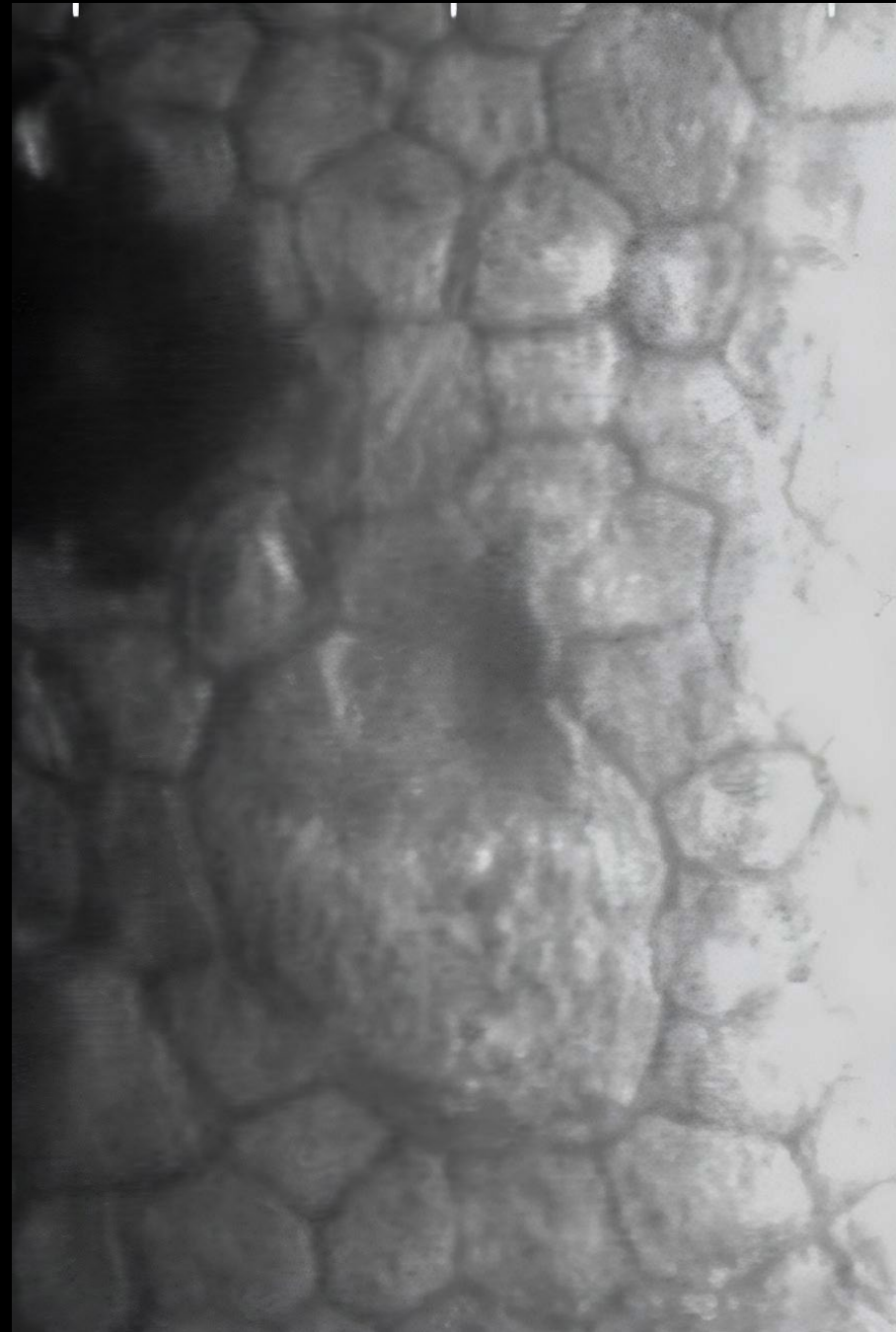Corneal Guttata
Anugraha Balamurugan, MS
Prasanna Ramesh, MS, DNB

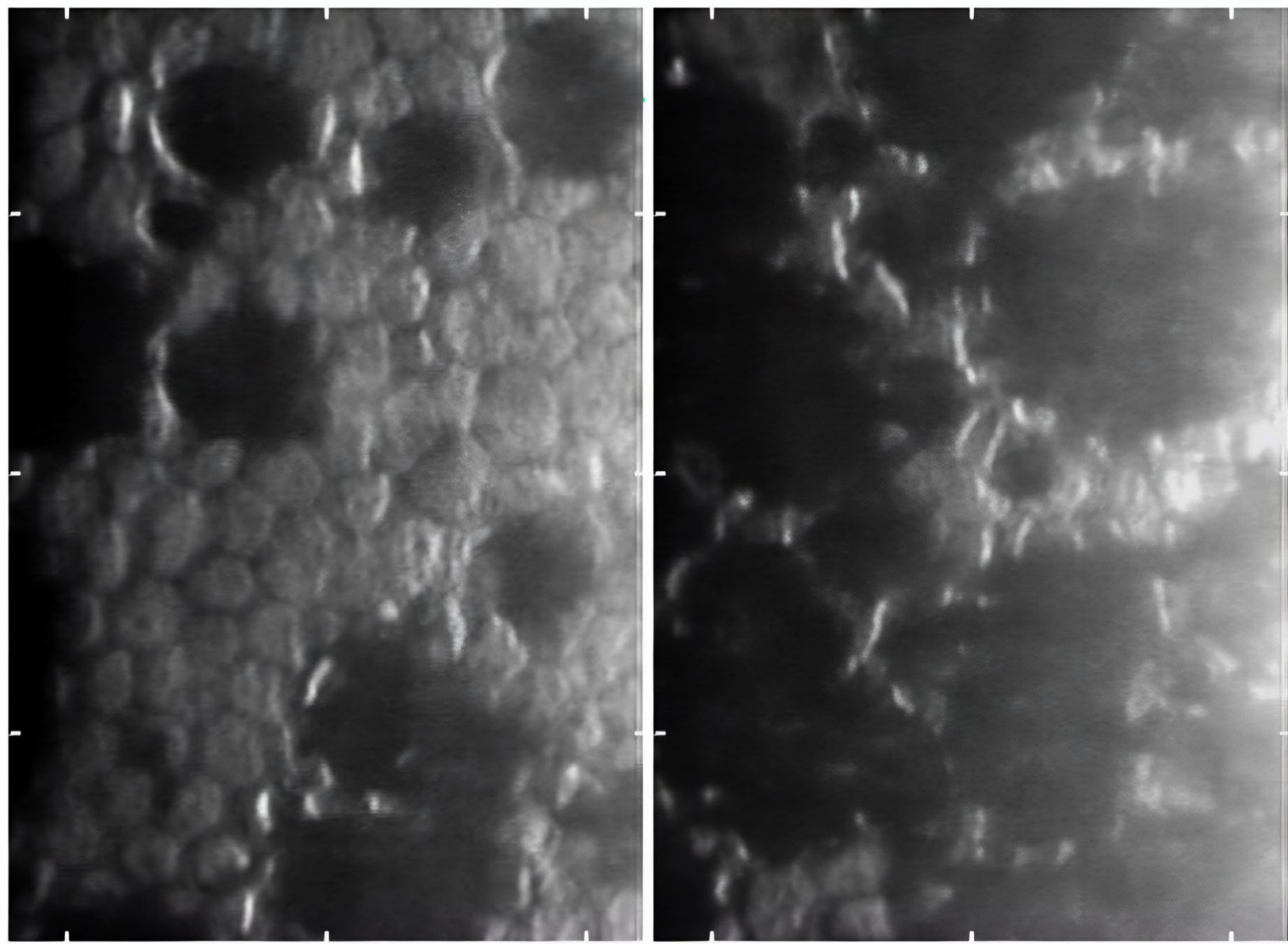


Polymegathism

Prasanna Ramesh, MS, DNB

Shruthy Ramesh, DNB, MS





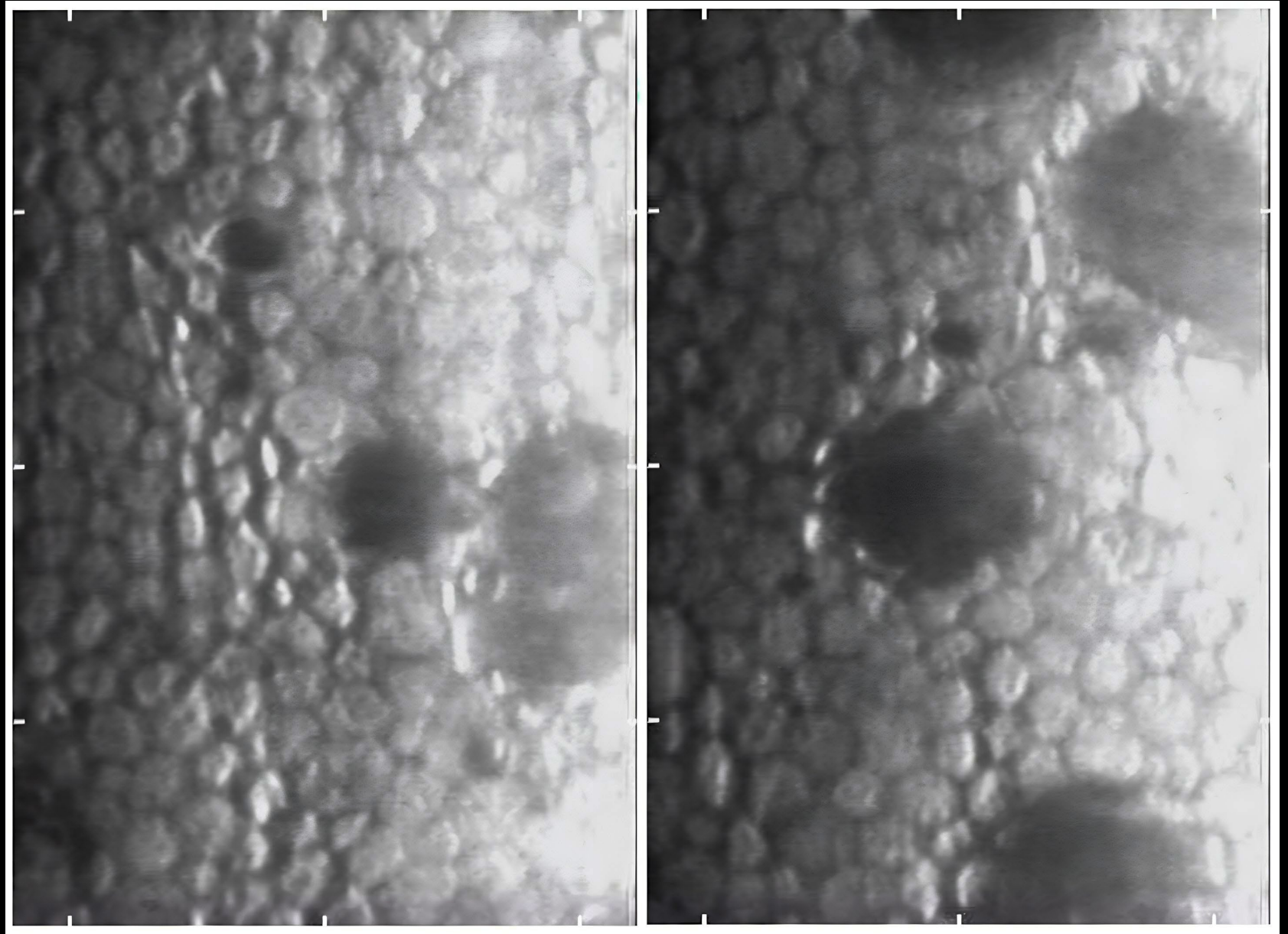
**Extracellular Matrix in
Descemet's Membrane**
Prasanna Ramesh, MS, DNB



Corneal Endothelium

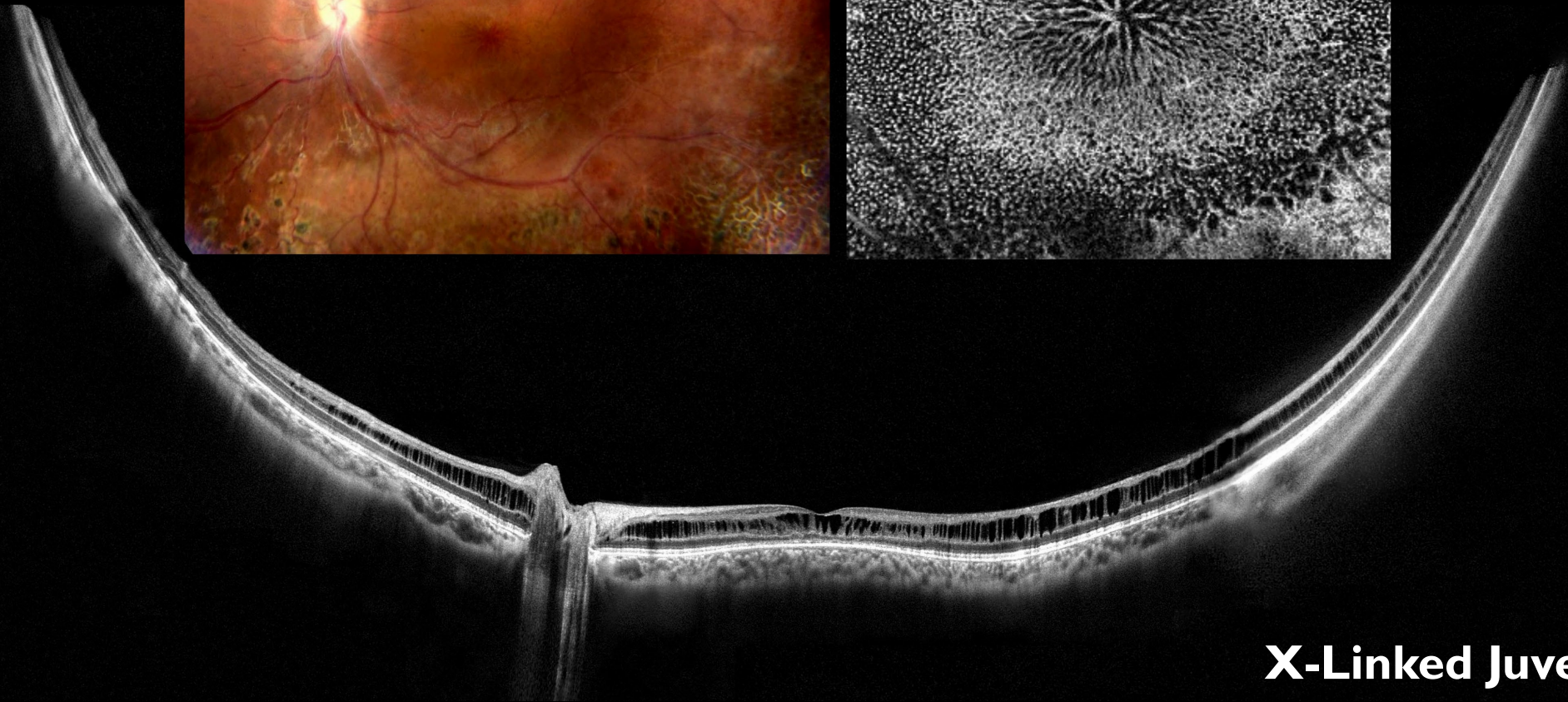
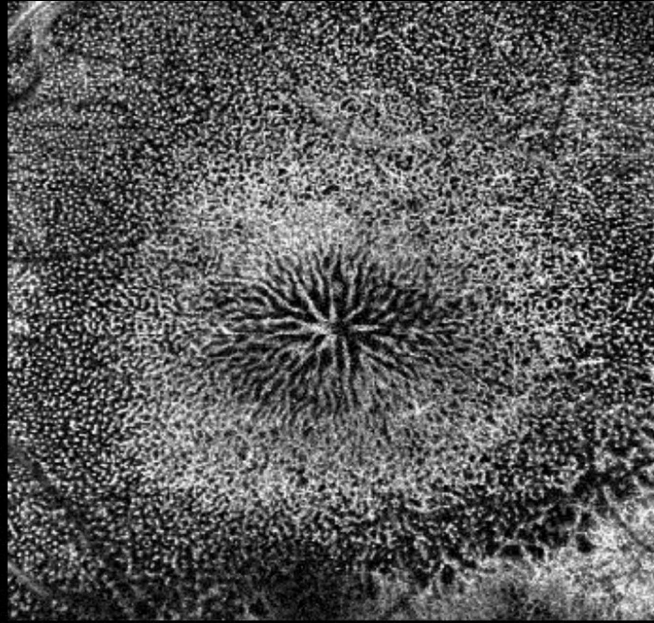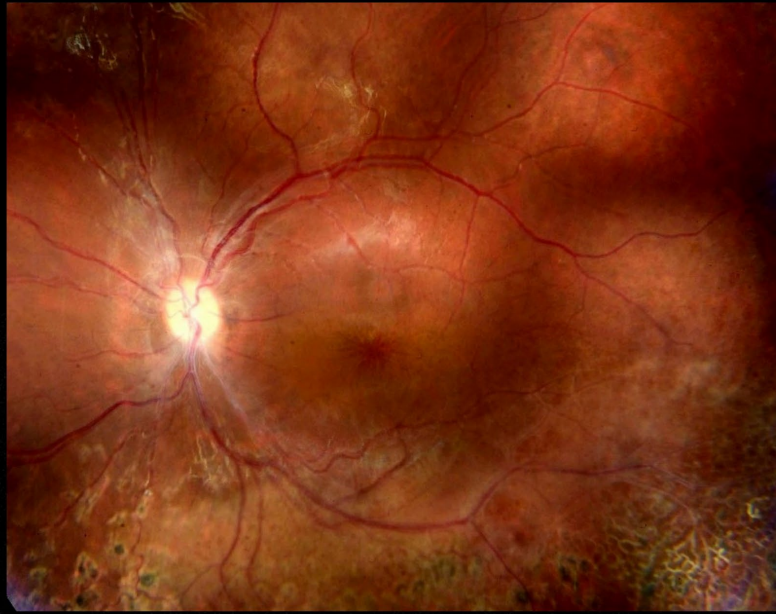
Prasanna Ramesh, MS, DNB

Shruthy Ramesh, DNB, MS





Cross Categories



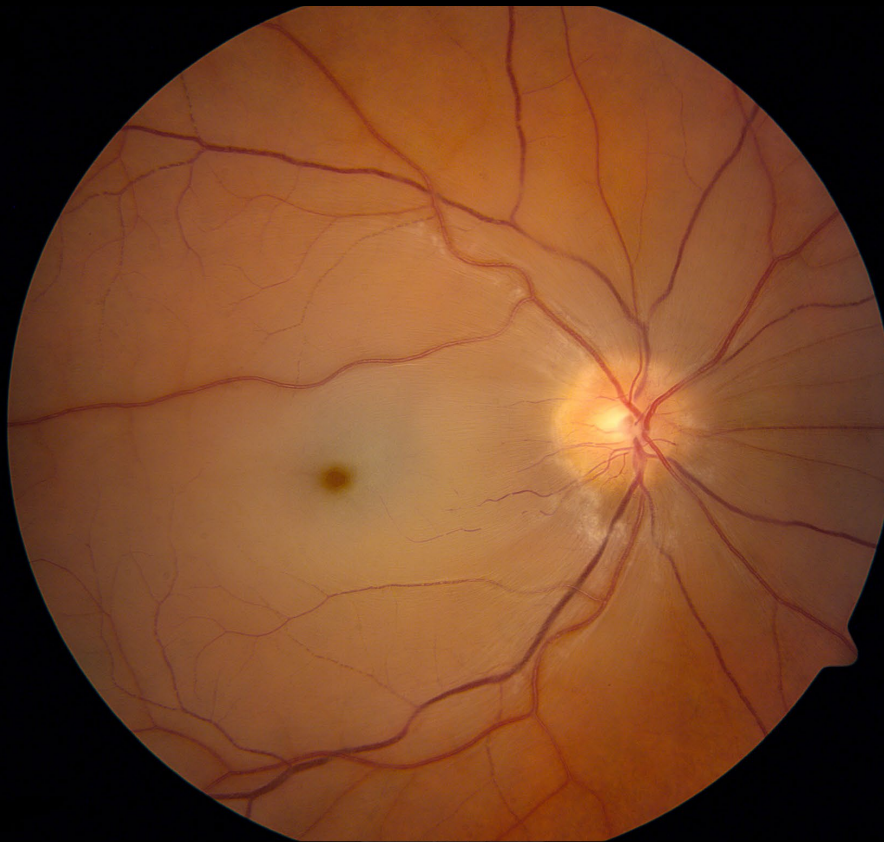X-Linked Juvenile Retinoschisis

Sousa Jefferson, BEng, COMT

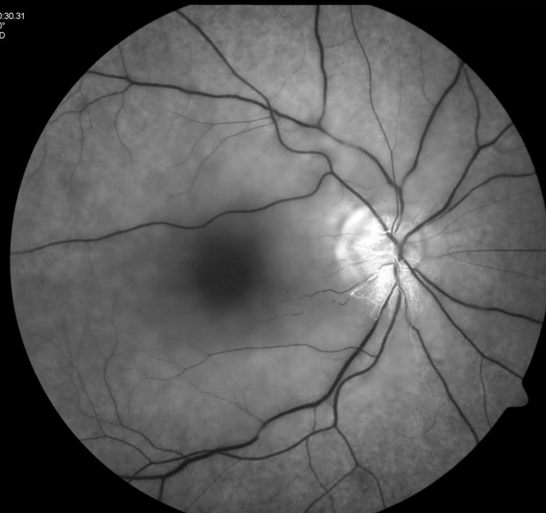

Central Retinal Artery Occlusion

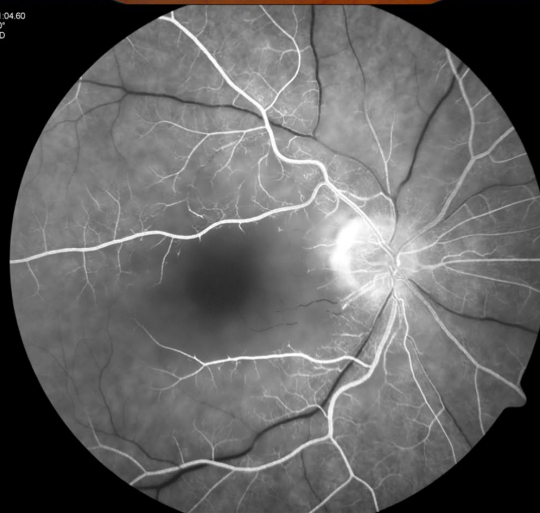
Gary Miller, CRA



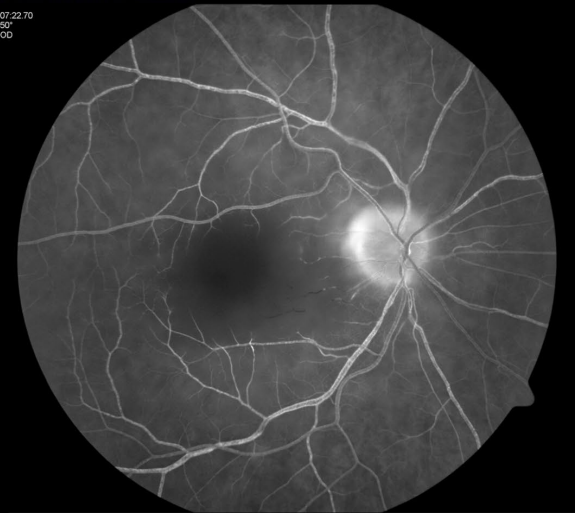00:30:31
50"
OD

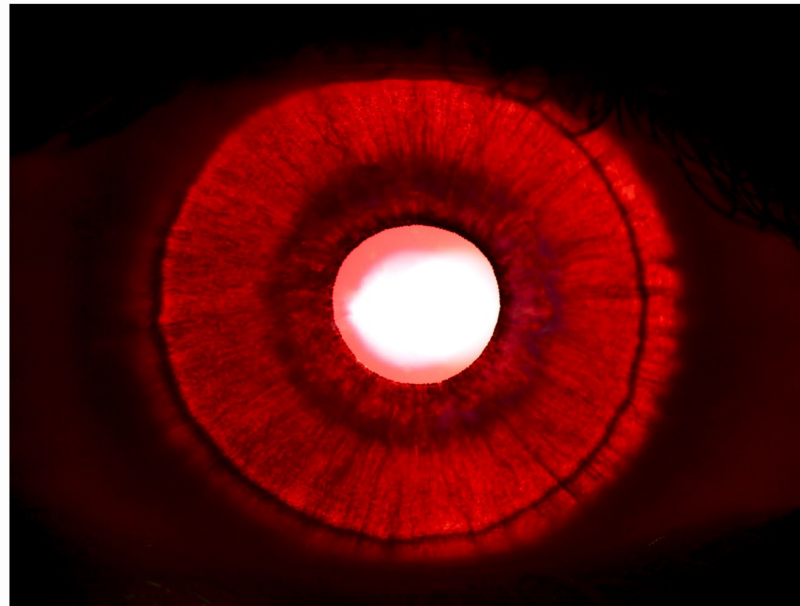
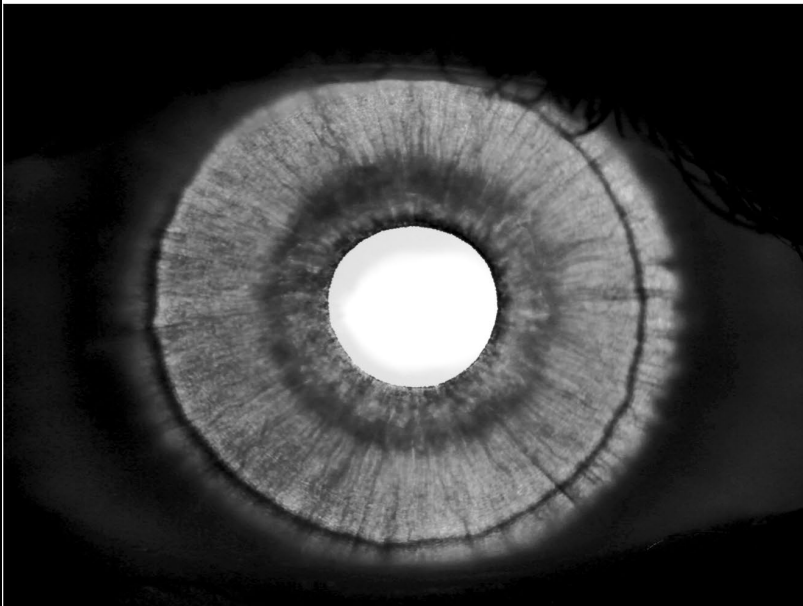
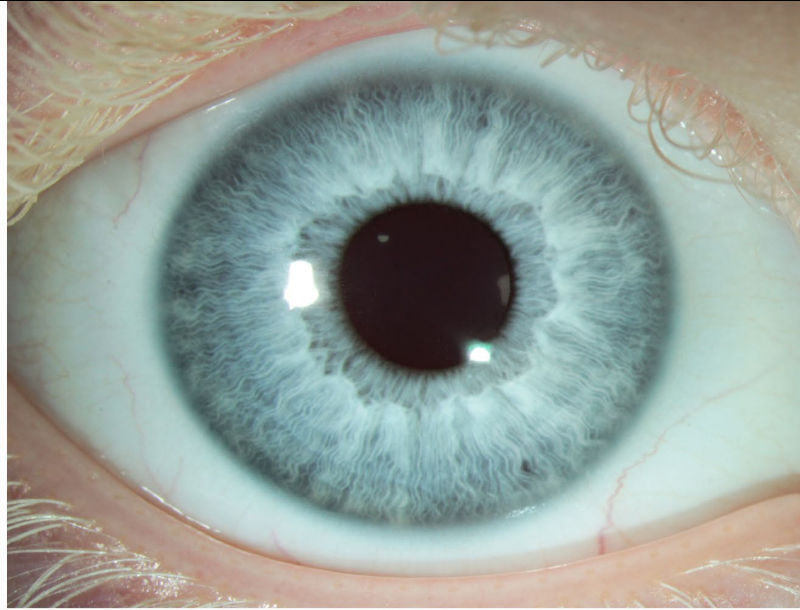
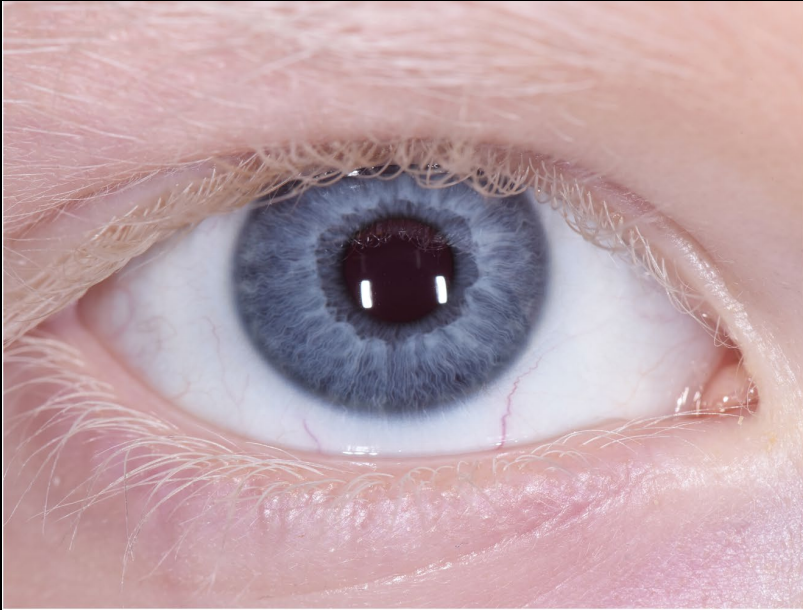


01:04:60
50"
OD

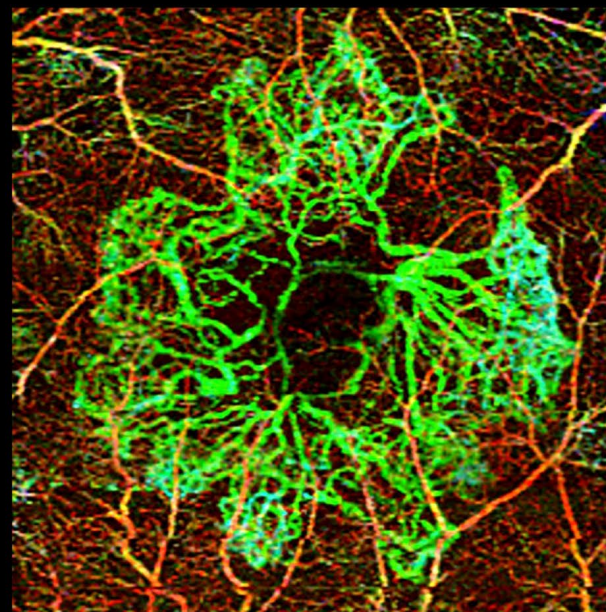
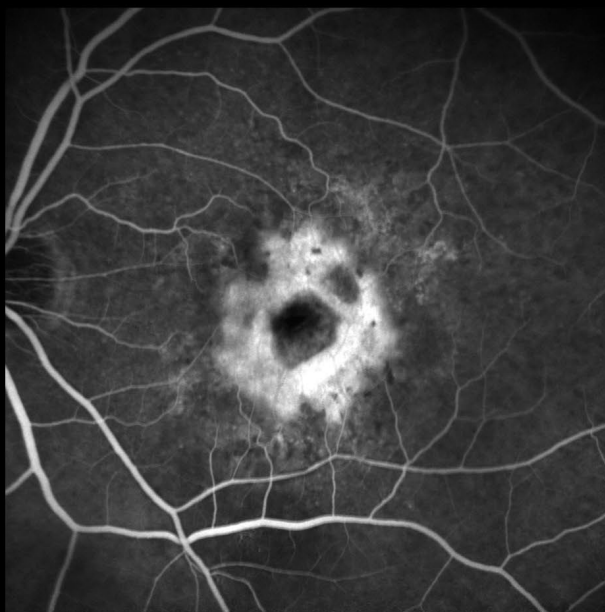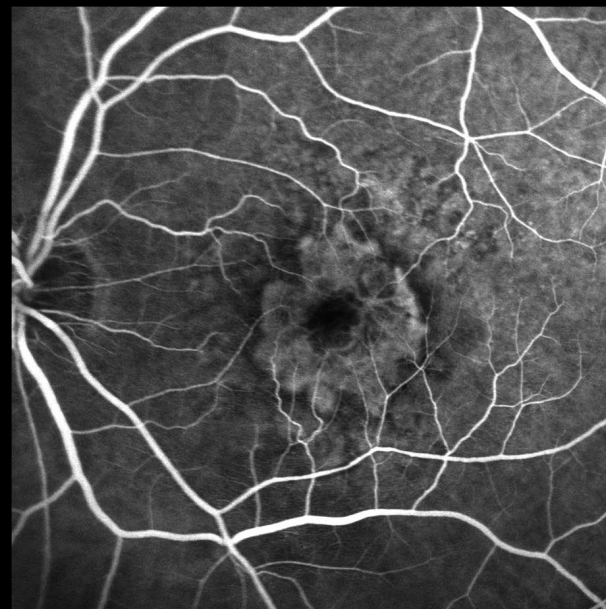
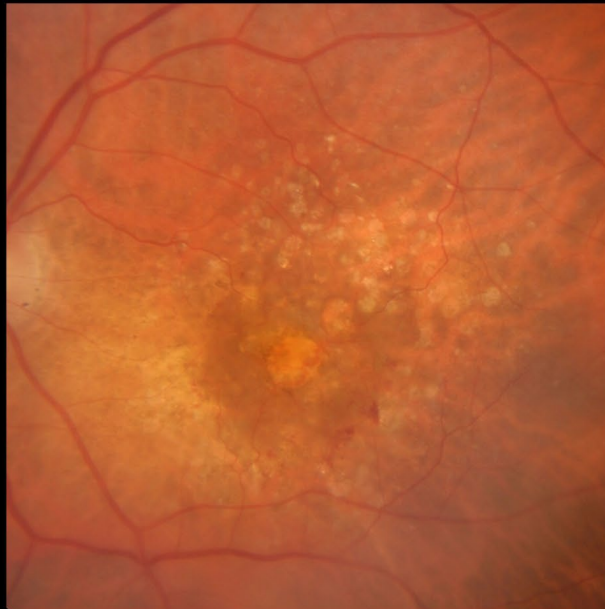


07:22:70
50"
OD





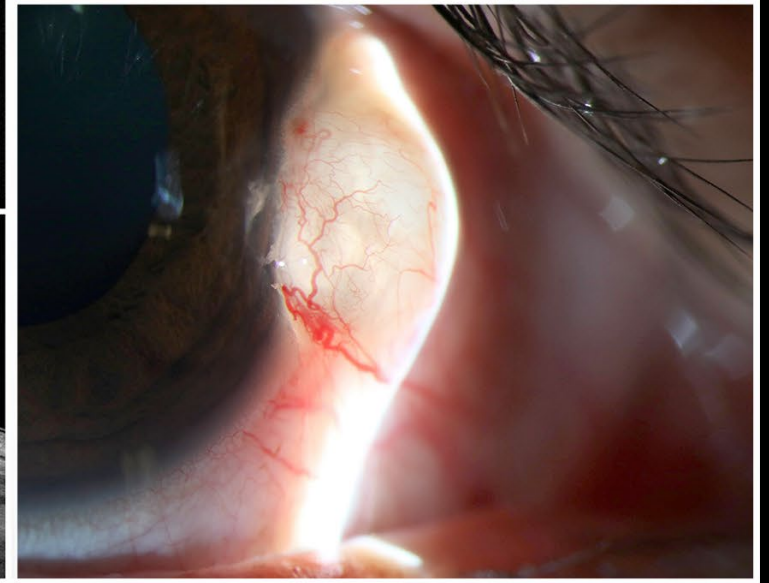
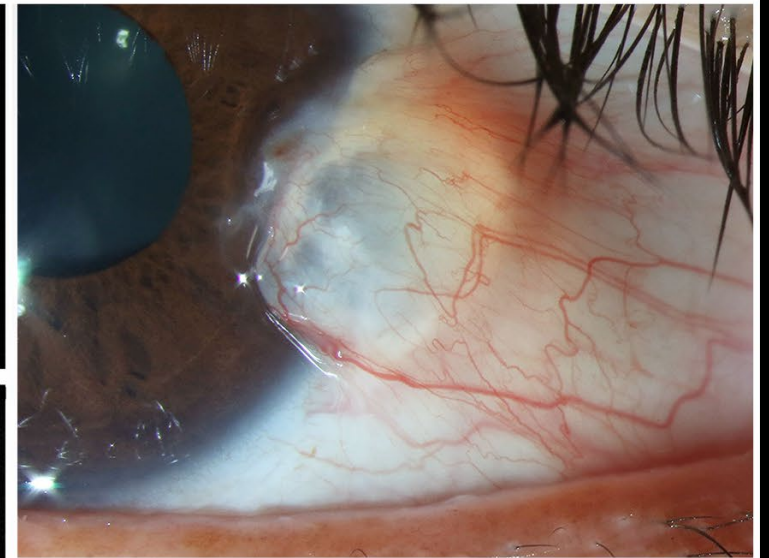
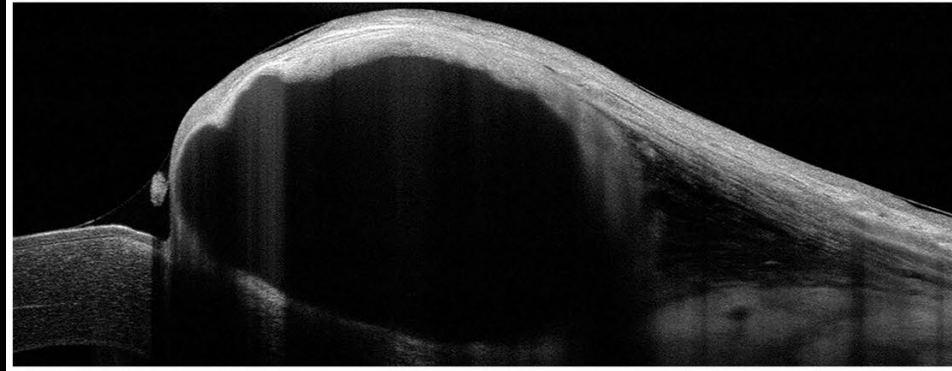
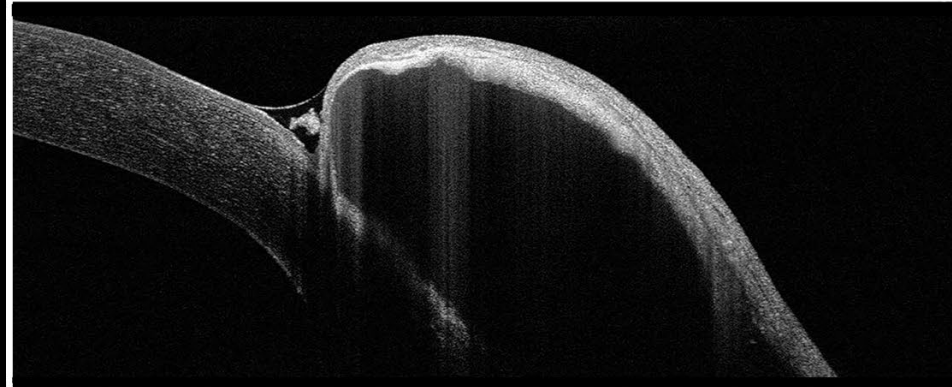
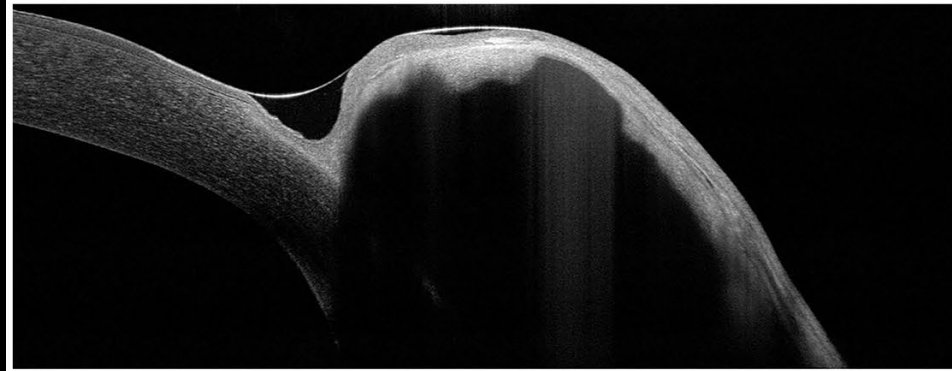**Oculocutaneous
Albinism w/ Iris
Transillumination 4x
Nicole Mantel**

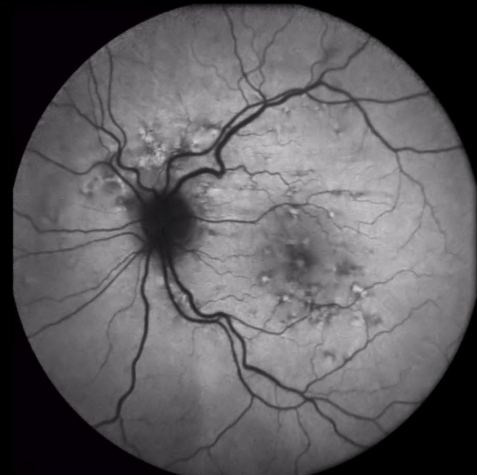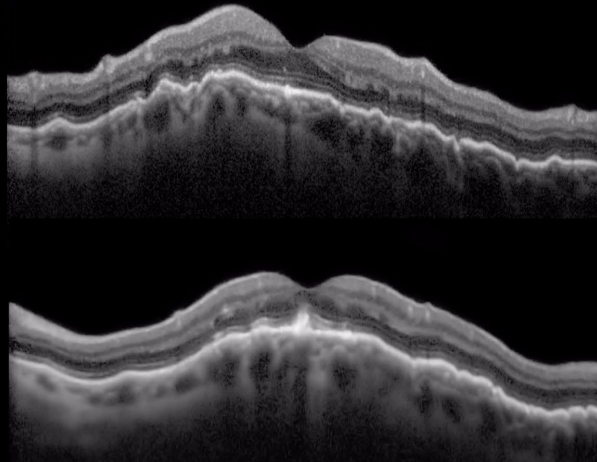
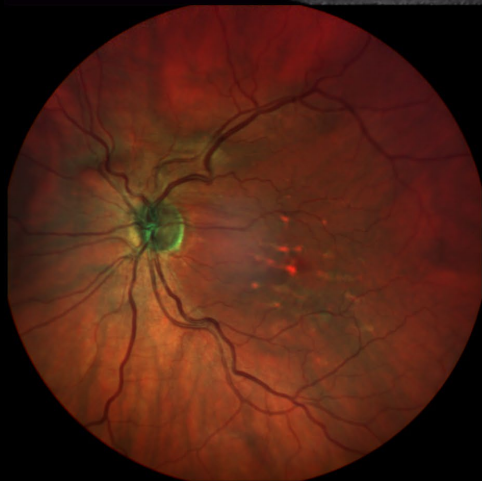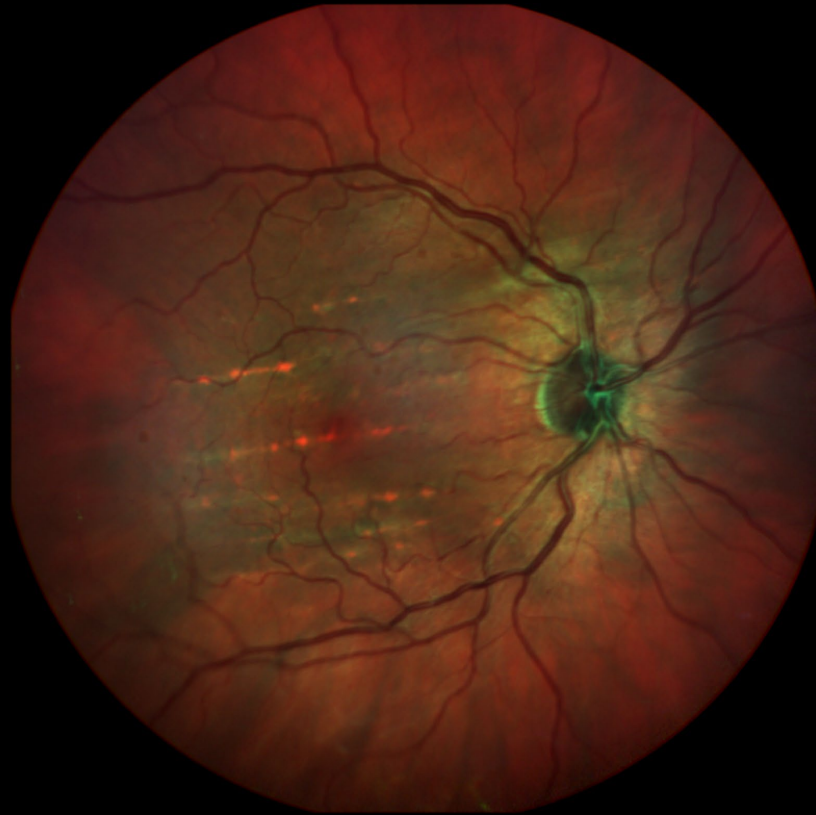
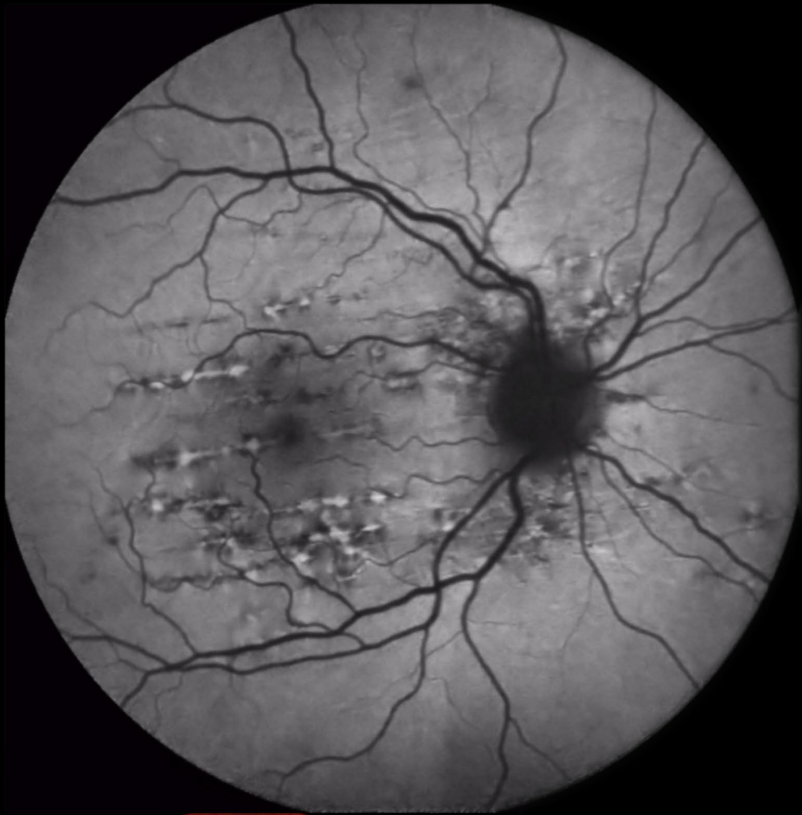


**Choroidal Neovascular
Membrane**
Megan Walsh, BSc, CRA



Pterygium Cyst
Sean Grout, OCT-C



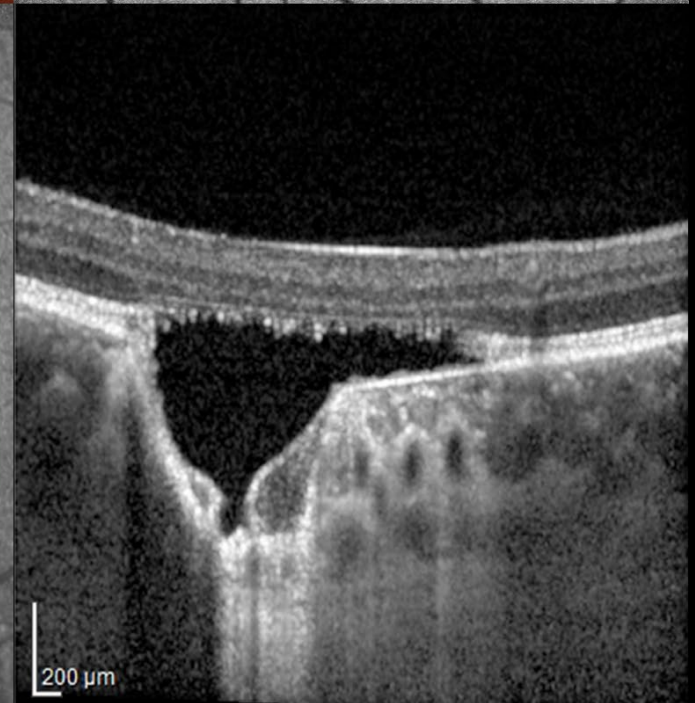
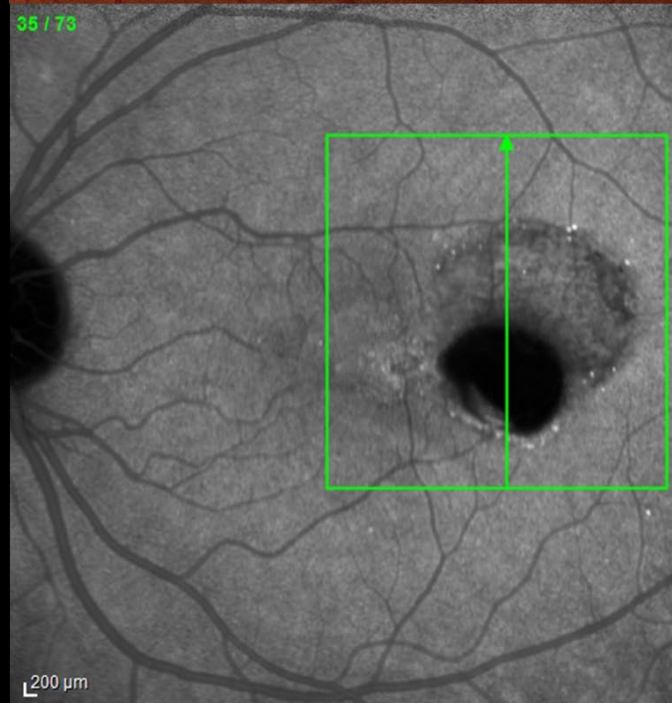
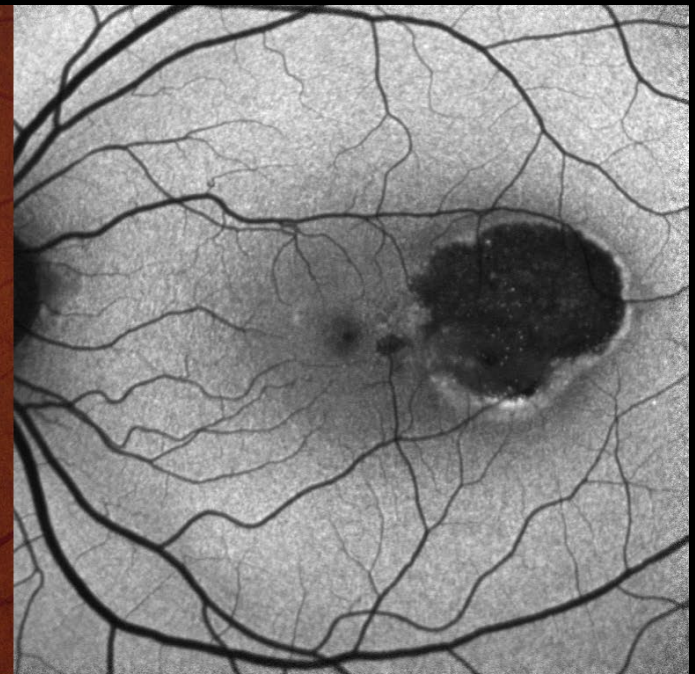
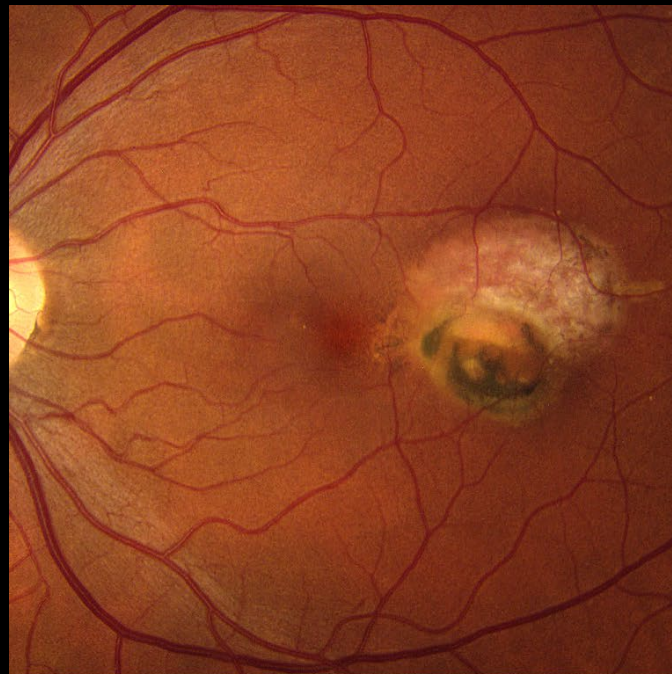

**Choroidal Folds
Secondary to Grave's
Disease**
Bryan Carmichael, BSc,
OSA, CST, COT



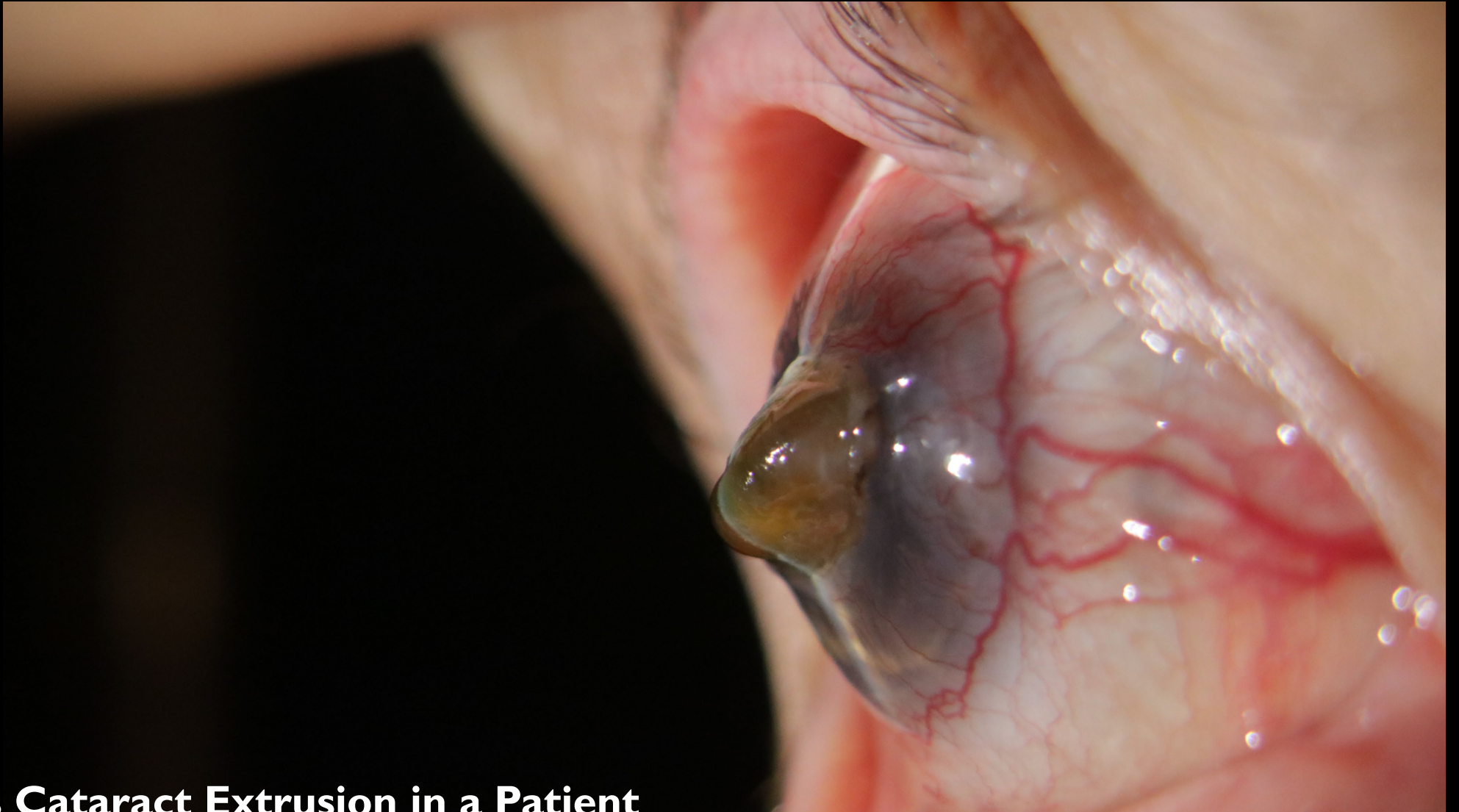Focal Choroidal Excavation

Hailey Litzer, OCT-C, CPSS



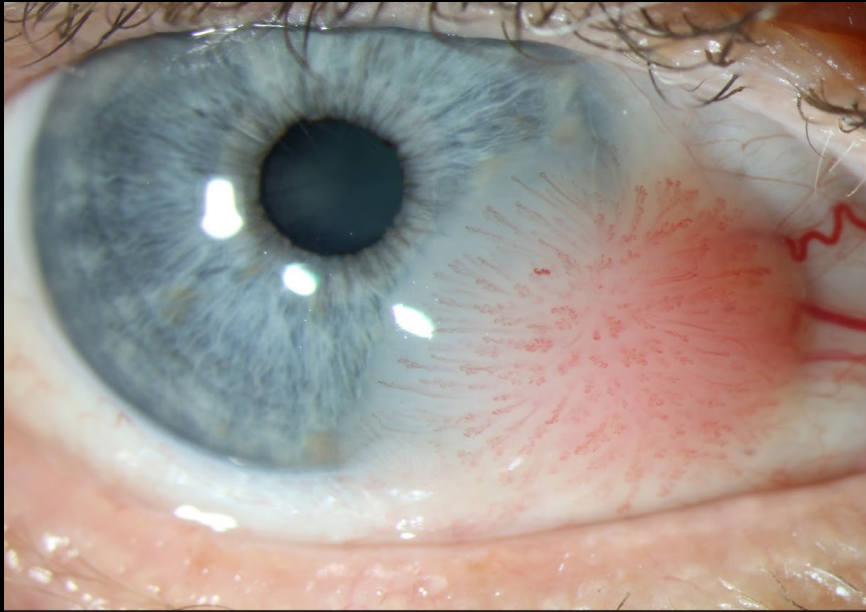


External Photography

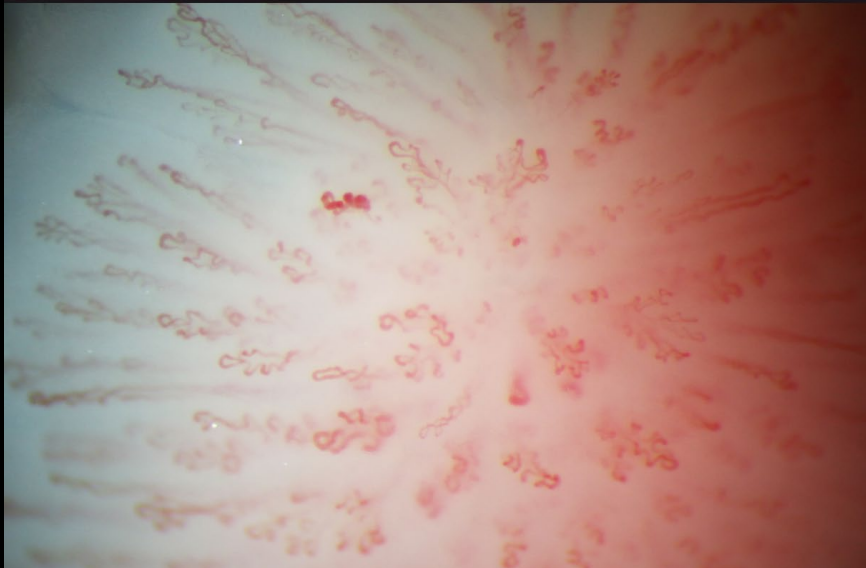


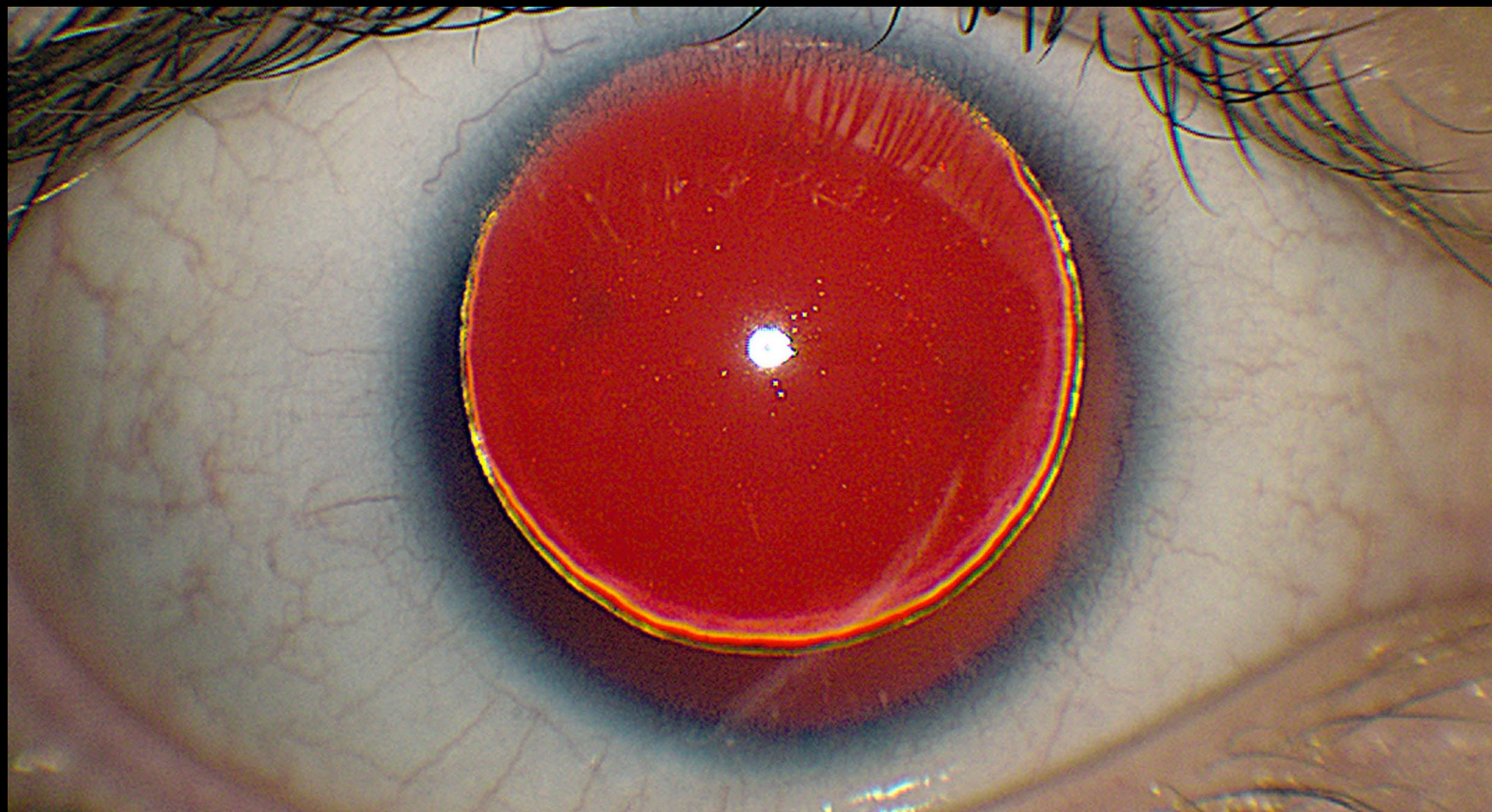
**Spontaneous Cataract Extrusion in a Patient
with Corneal Melting**

Gustavo Moreira Madeira



Conjunctival Papilloma
Kathleen Warren, OCT-C



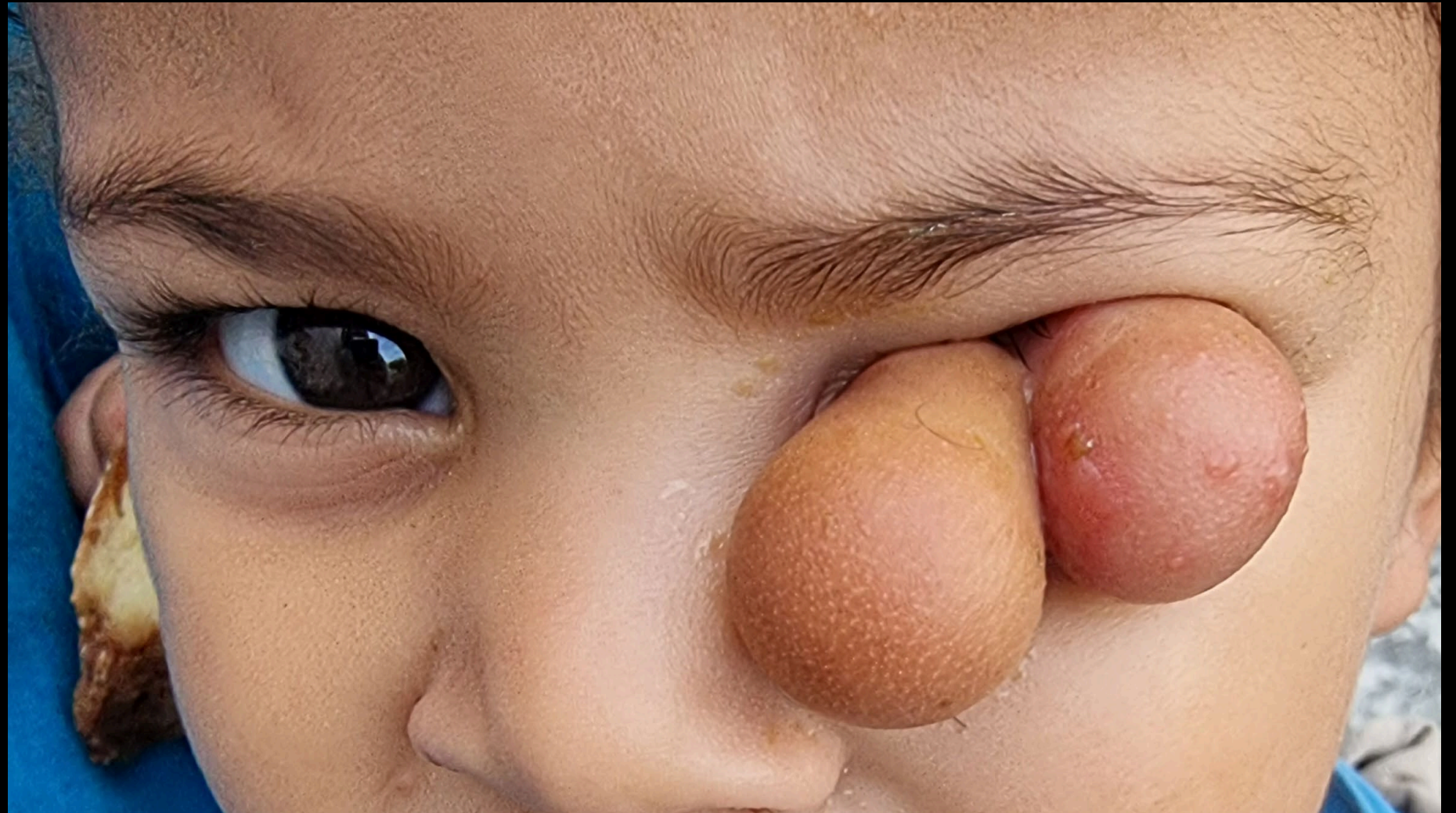

Aniridia

Sarah Skiles, MA, BA, CRA

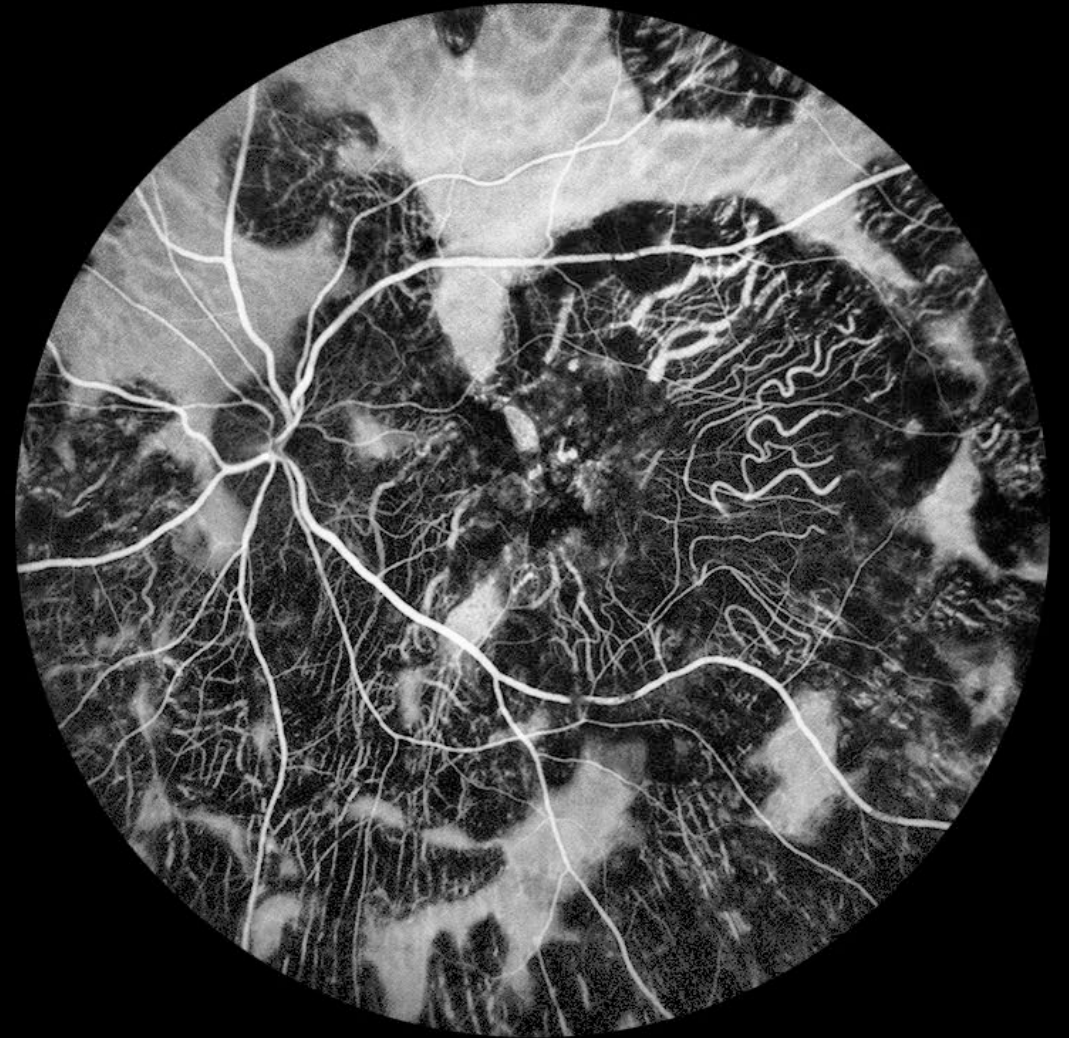
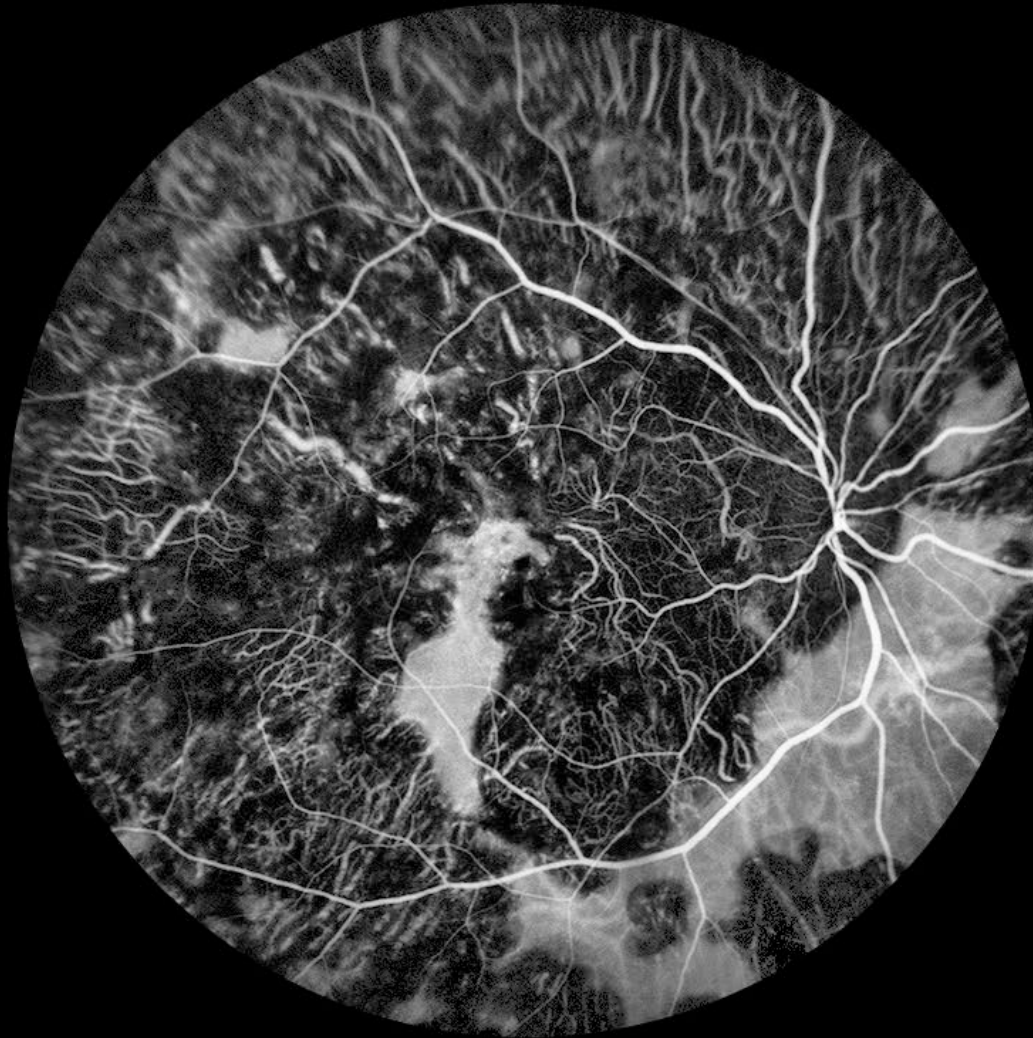

**Eyeball Replaced
w/ a Dermolipoma**
Sara Ettouri, PhD

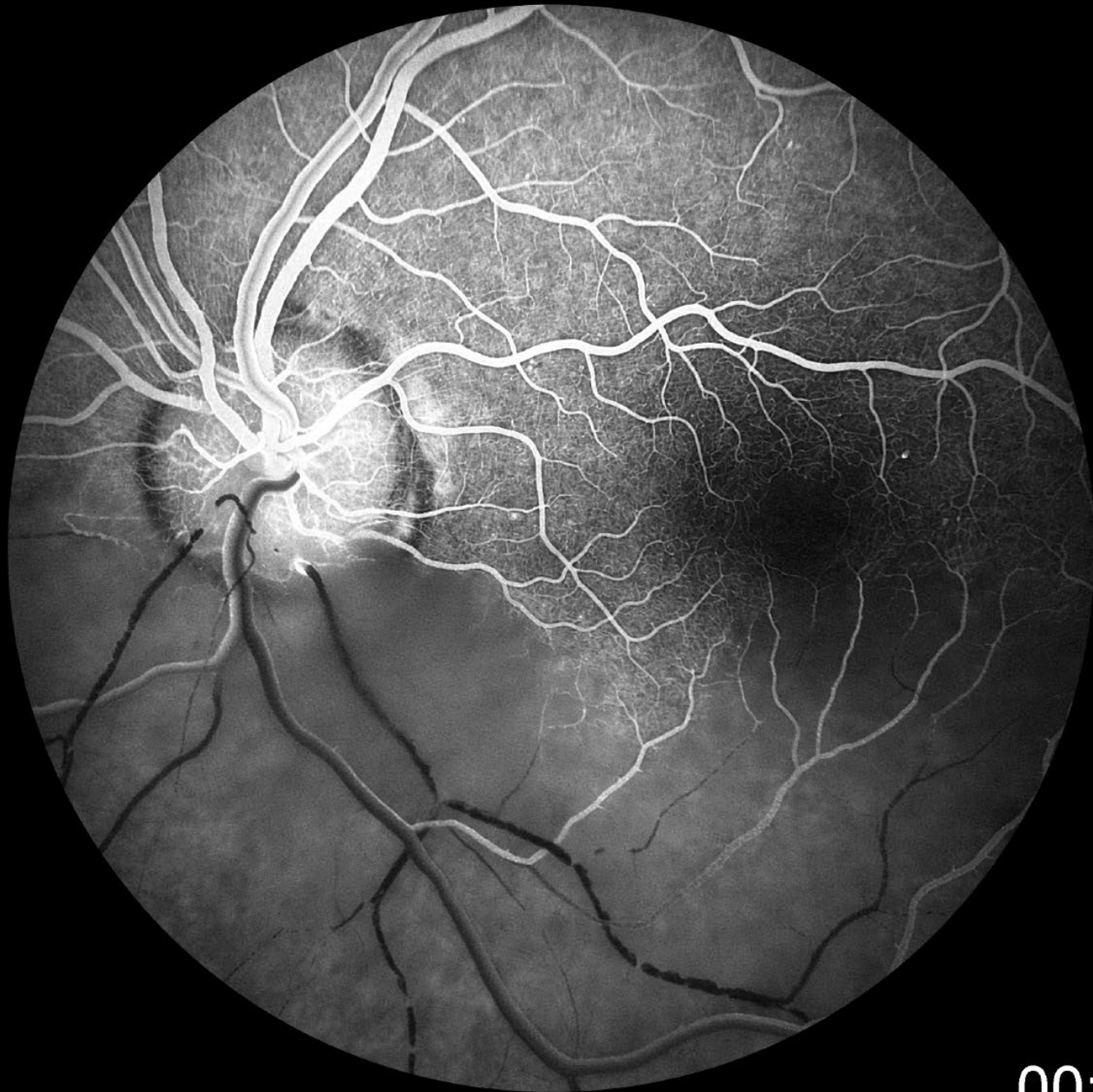


The background of the slide is a dark, teal-colored image showing a cross-section of a blood vessel. The vessel lumen is filled with numerous small, bright, multi-colored spots (yellow, orange, and green) that represent fluorescein dye circulating through the bloodstream. The vessel wall is visible as a dark, textured boundary.

Fluorescein Angiography

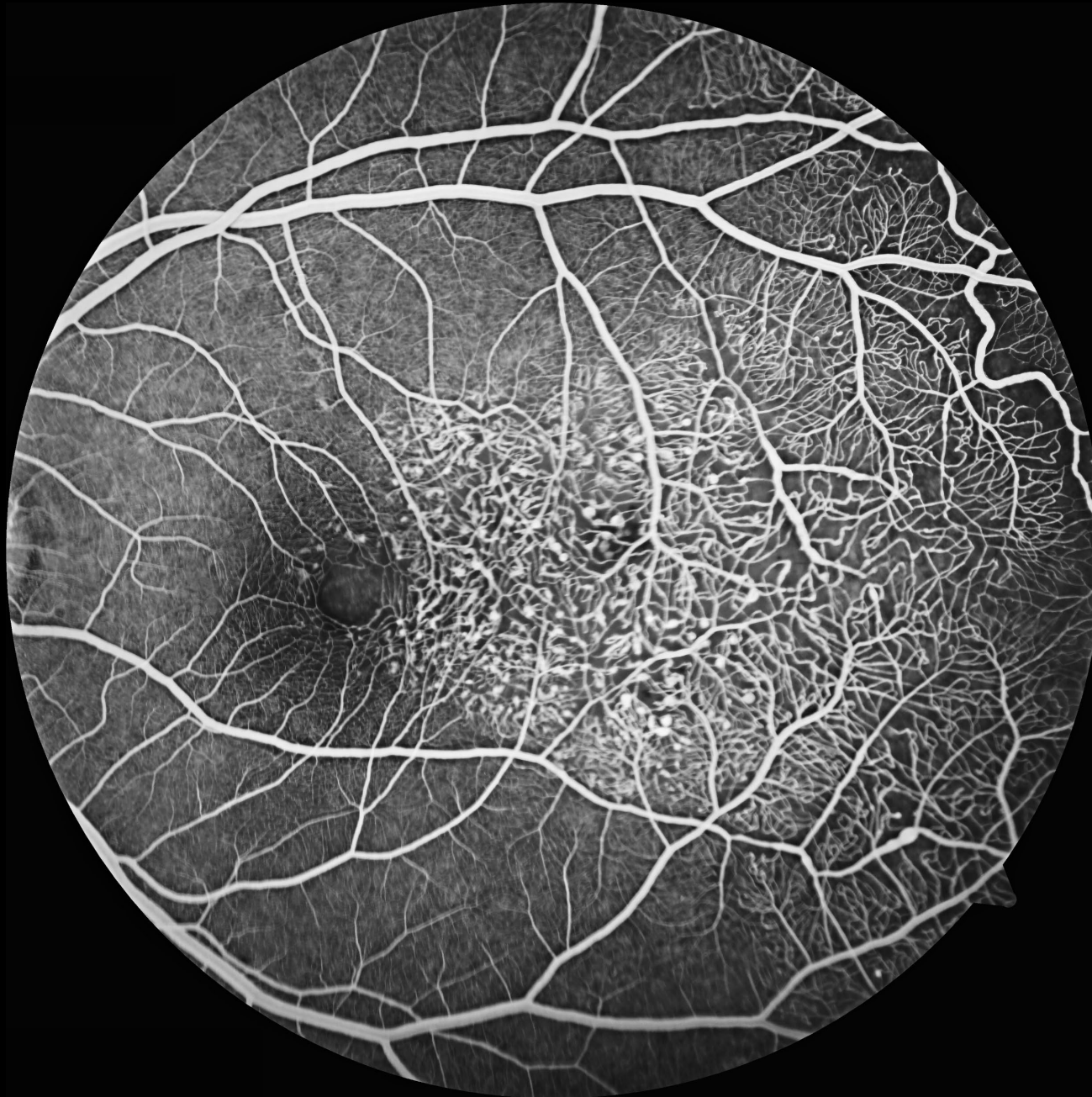


Choroiditis
Sean Grout, OCT-C

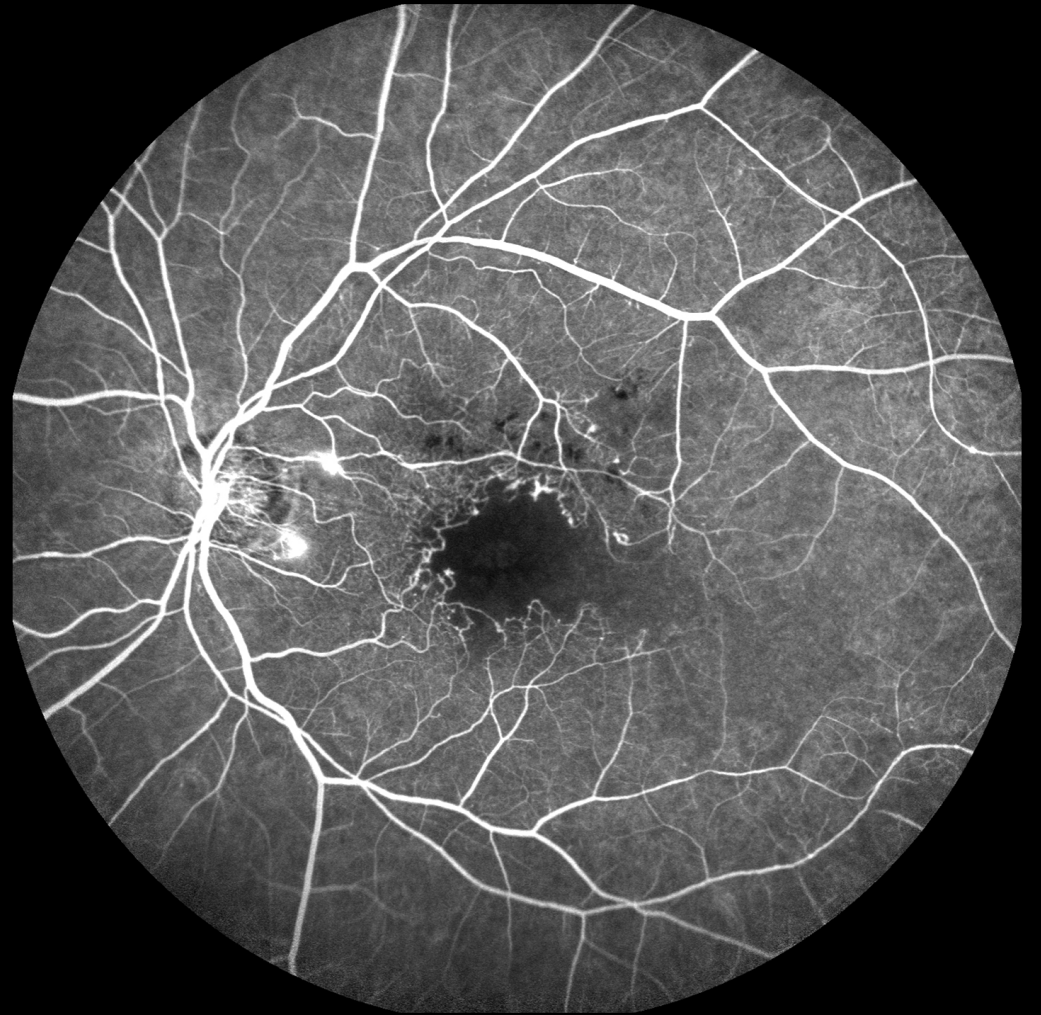
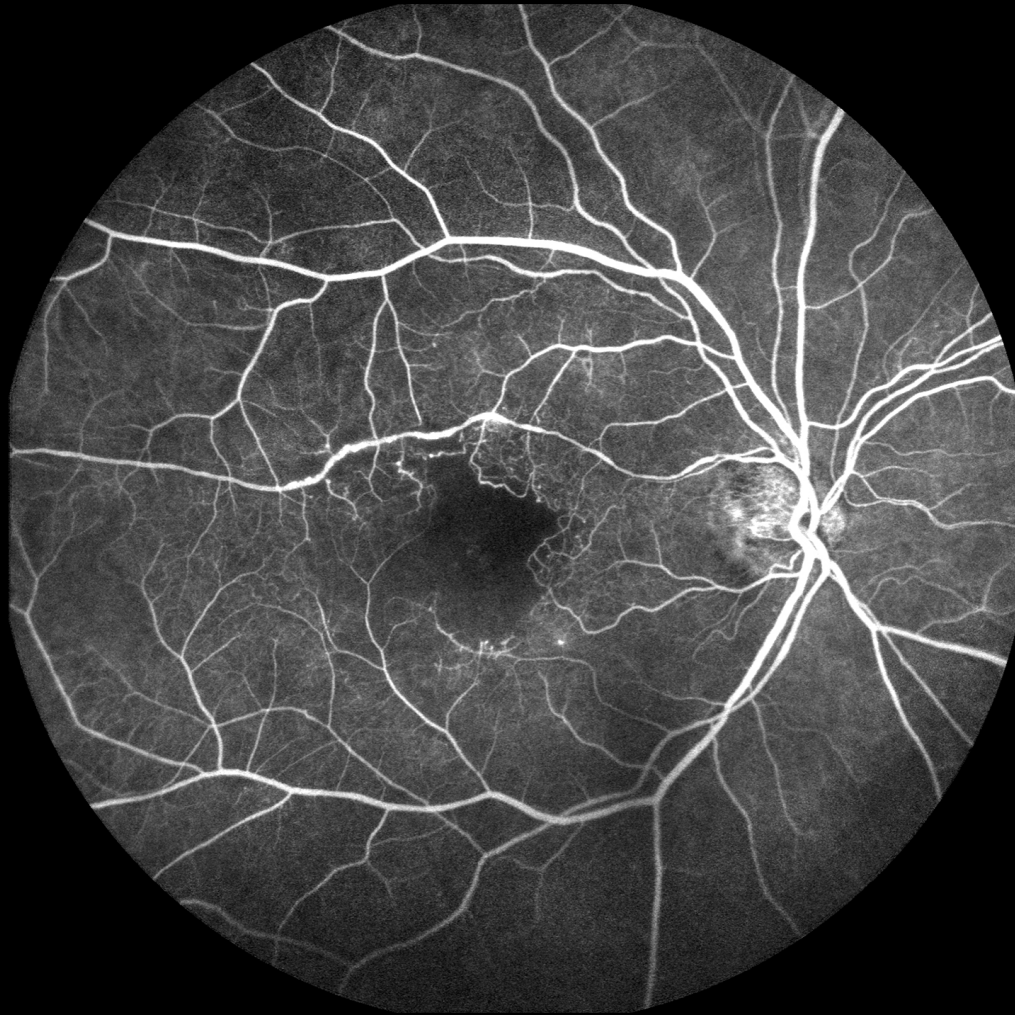


Branch Retinal Artery Occlusion
Ben Serar, MA, CRA

00:28.9



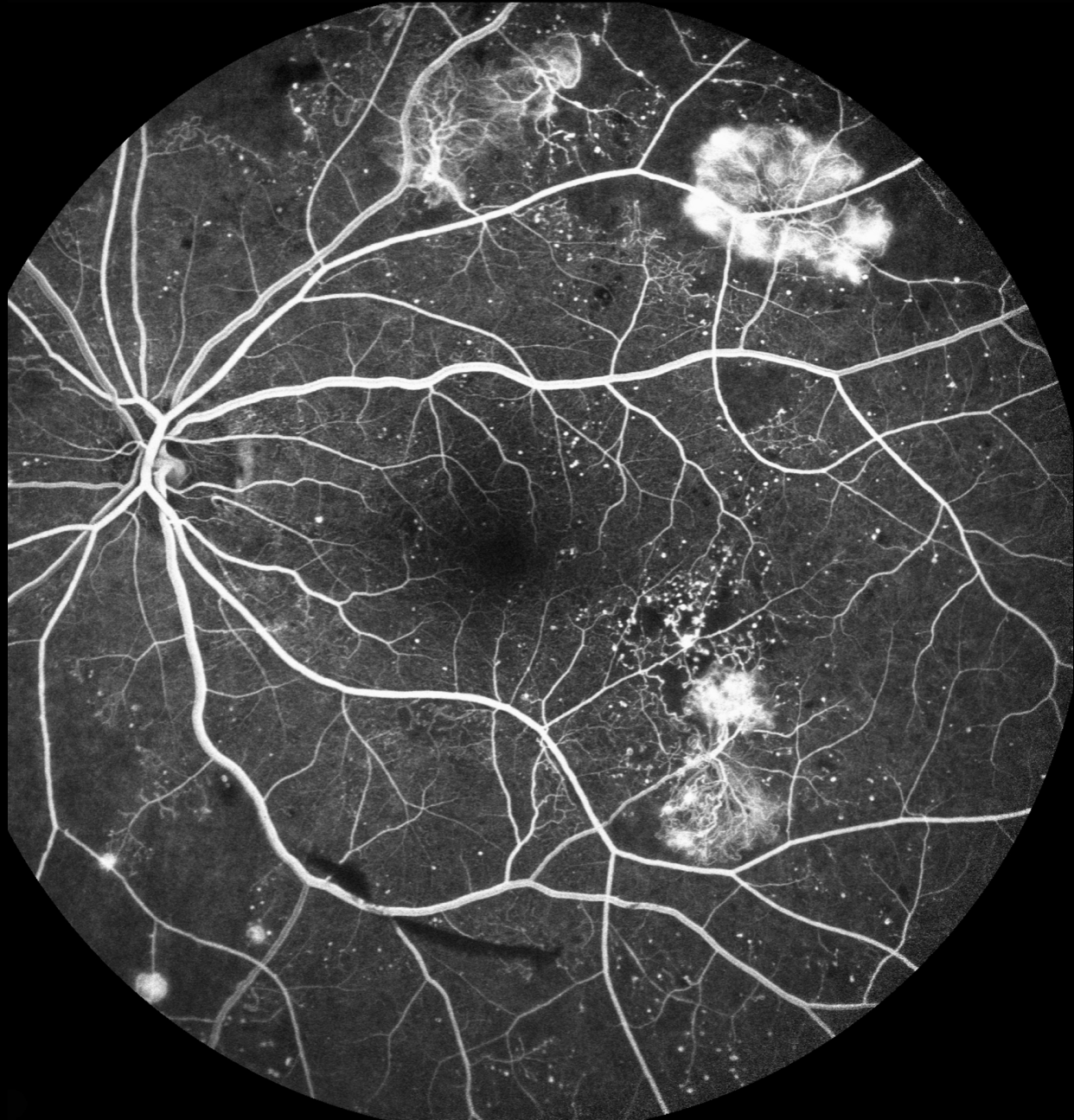
Telengectasia
John Leo, BSc

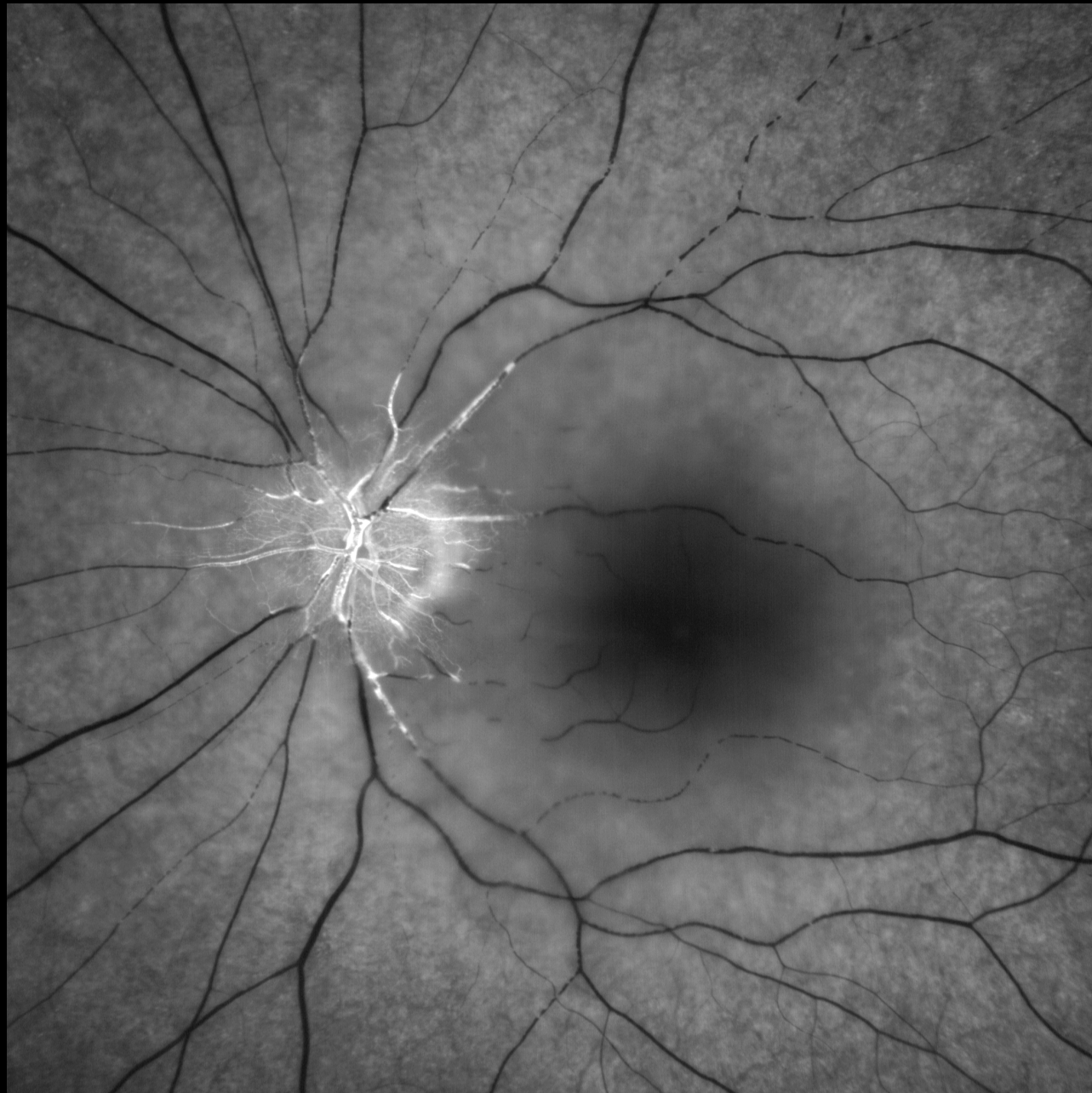

**Atypical Macular
Telangiectasia**
Megan Walsh, BSc, CRA



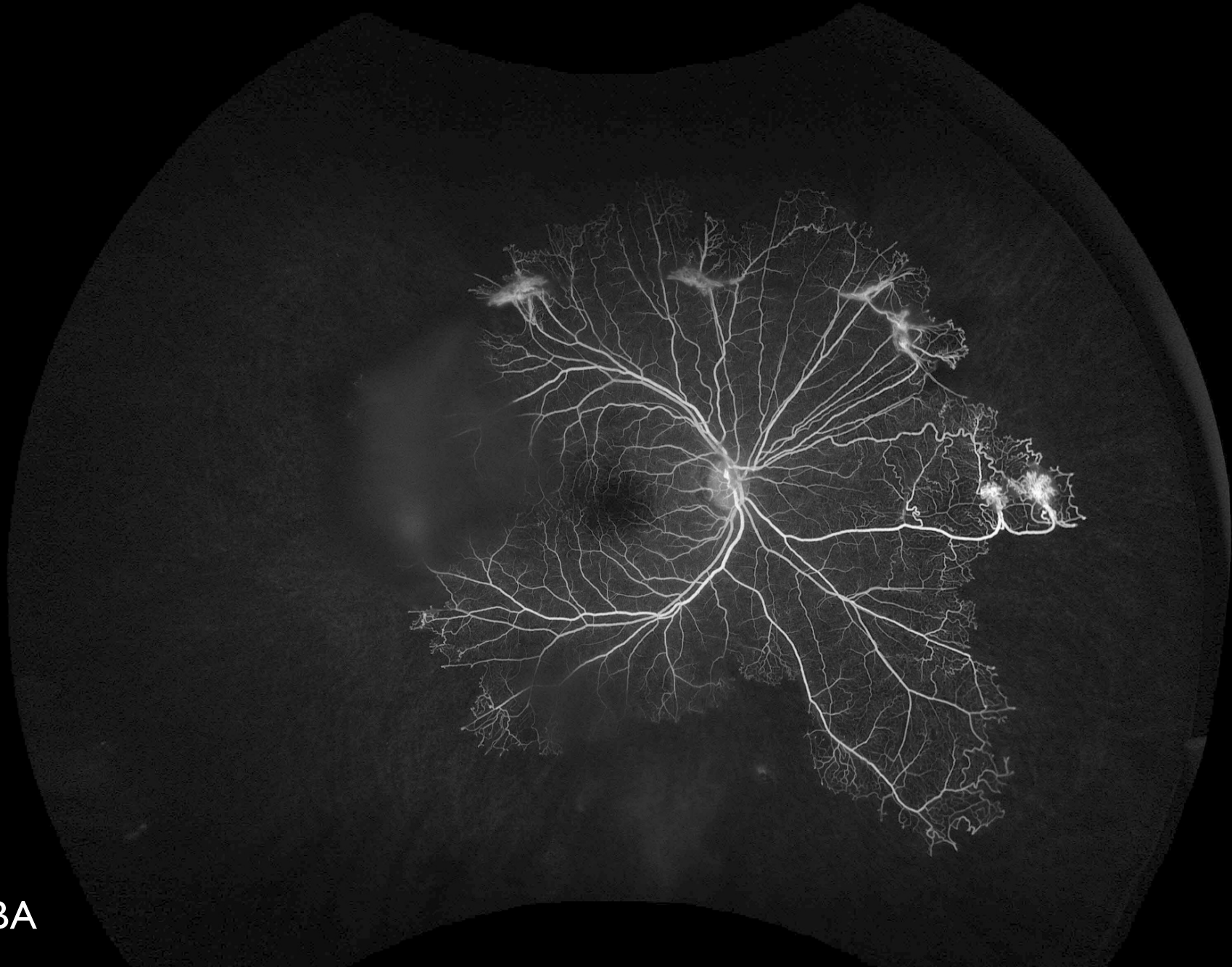**Proliferative Diabetic
Retinopathy**
Darrin Landry, CRA





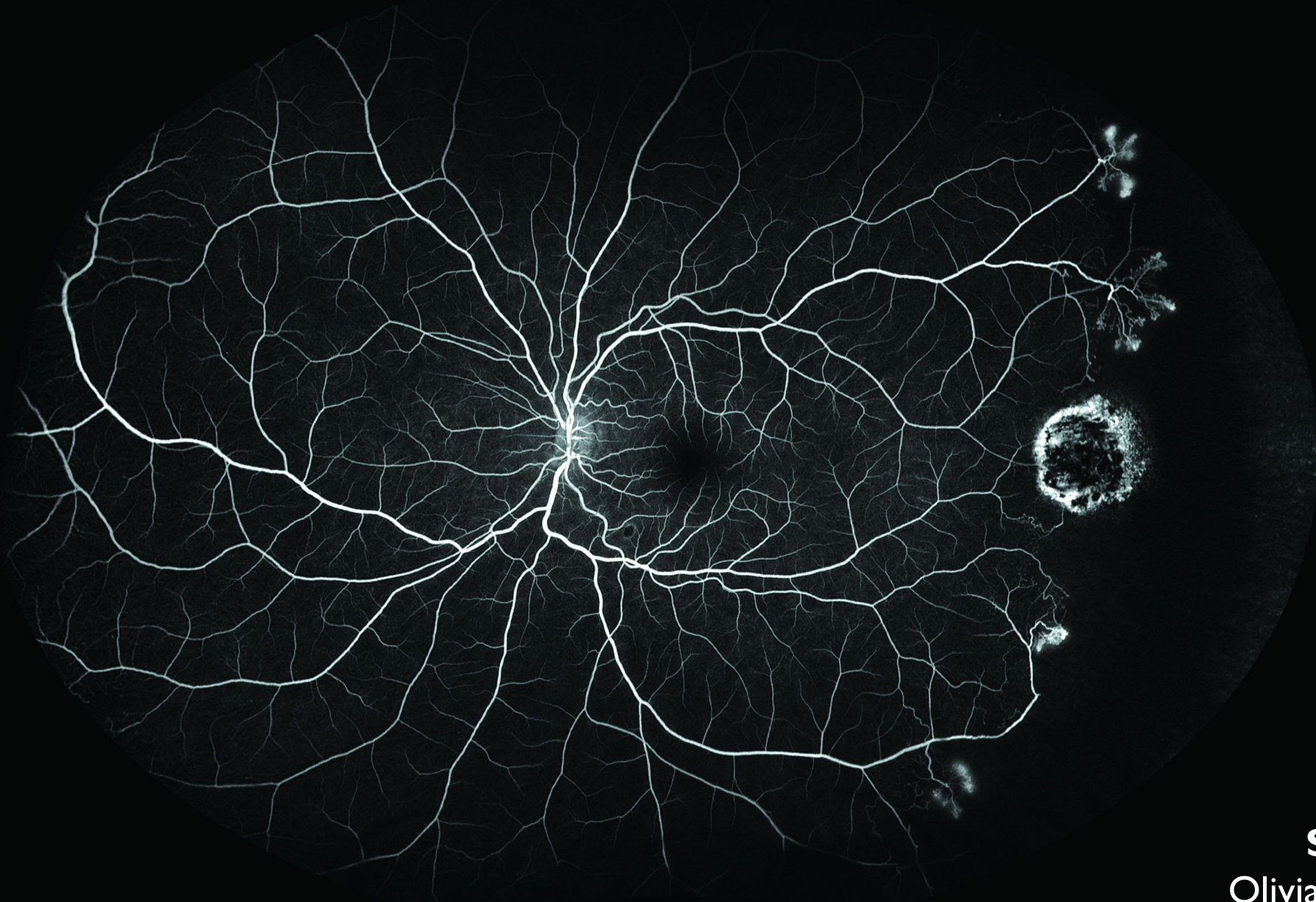
**Central Retinal Artery
Occlusion**

Noelle Pensec Rovensky, BSc, CRA



Sickle Cell

Christiaan Lopez-Miro, BA



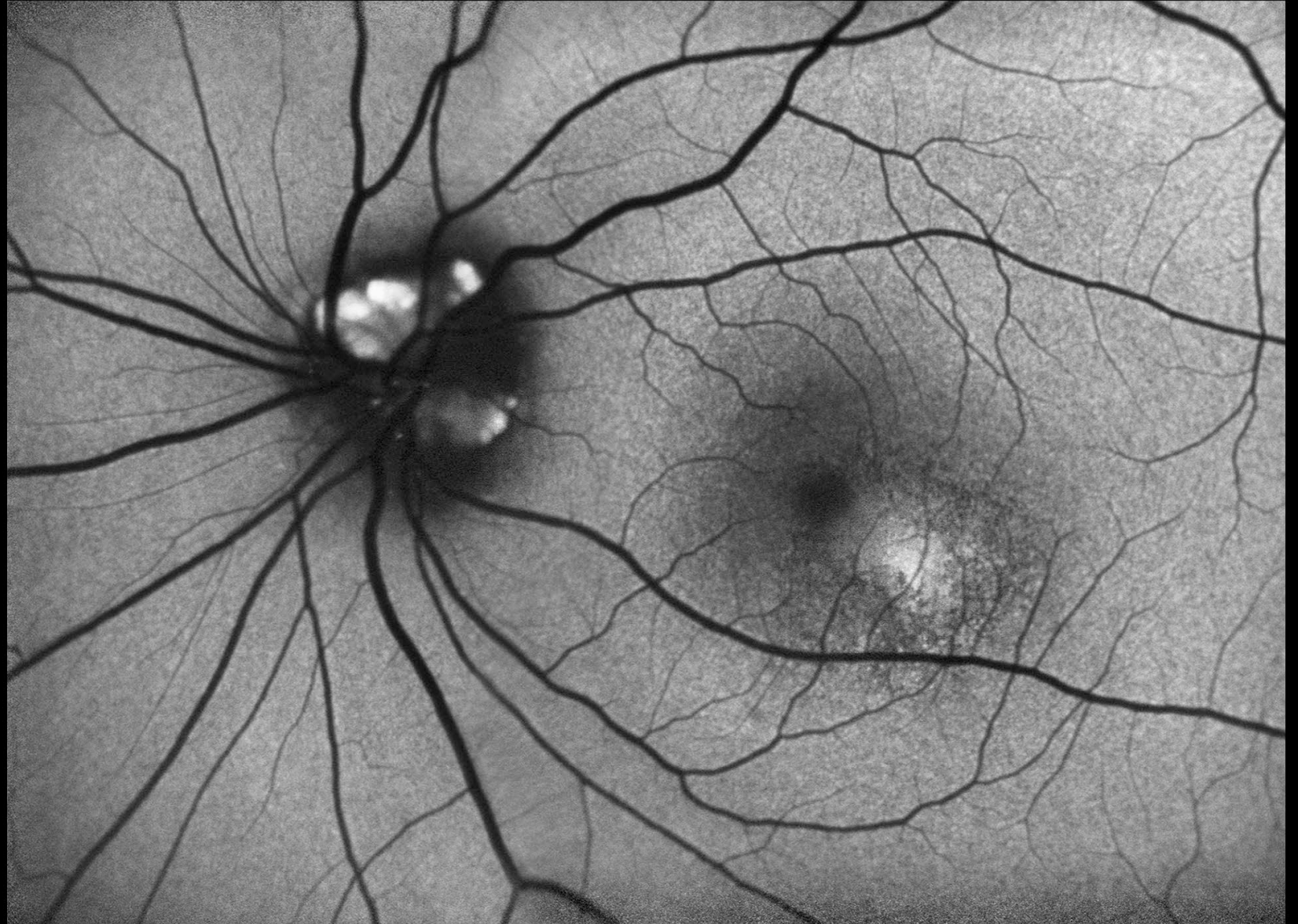
Sickle Cell Retinopathy
Olivia Rainey, BA, COA, OCT-C

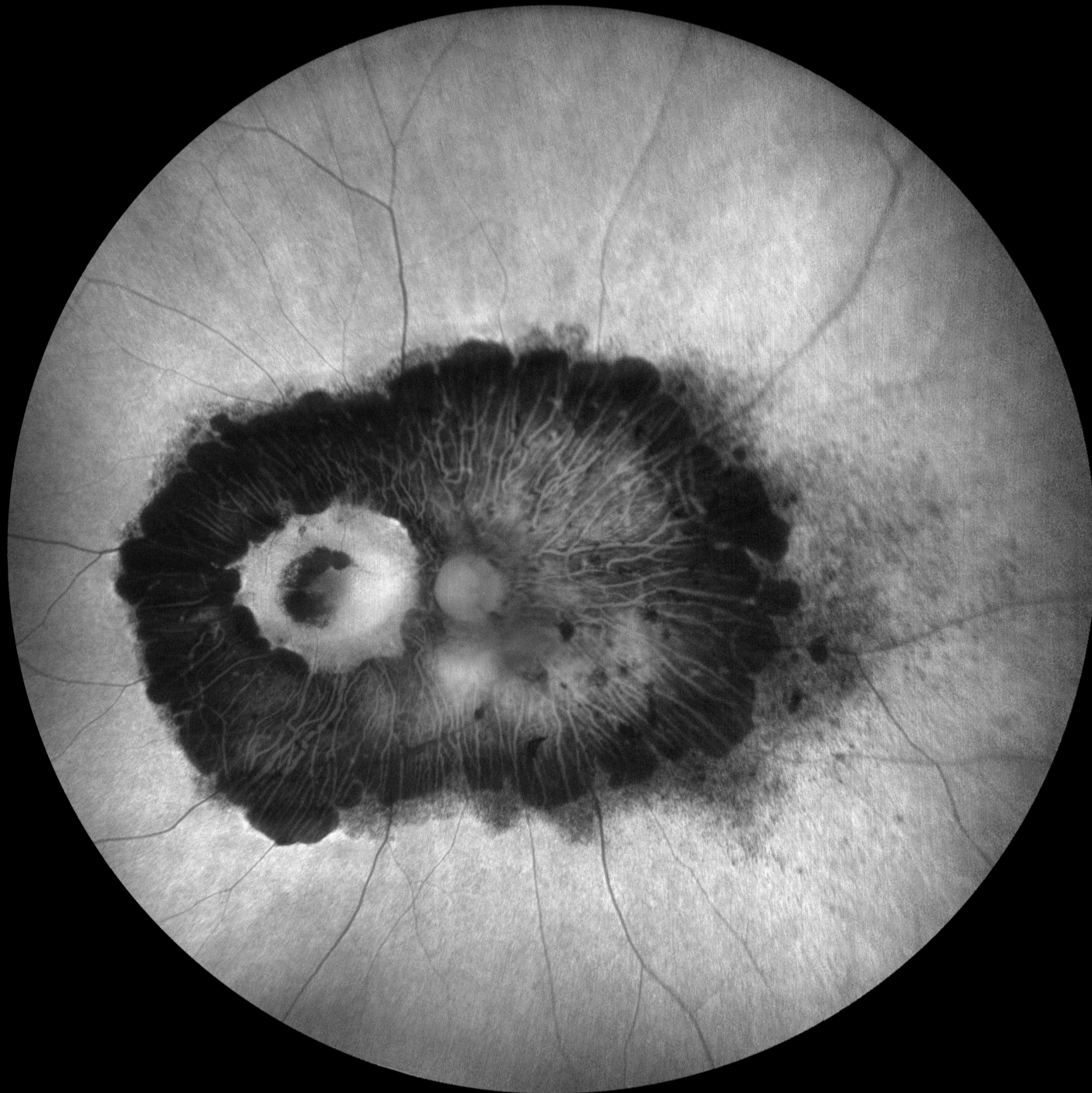The background image is a fundus autofluorescence (FAF) scan. It shows a circular field of view with a central area containing numerous small, bright, multi-colored spots (yellow, orange, and green) arranged in a roughly circular pattern. The surrounding areas are darker, with some faint, larger spots. The overall color palette is dominated by dark blues and greens, with the bright spots providing high contrast.

Fundus Autofluorescence

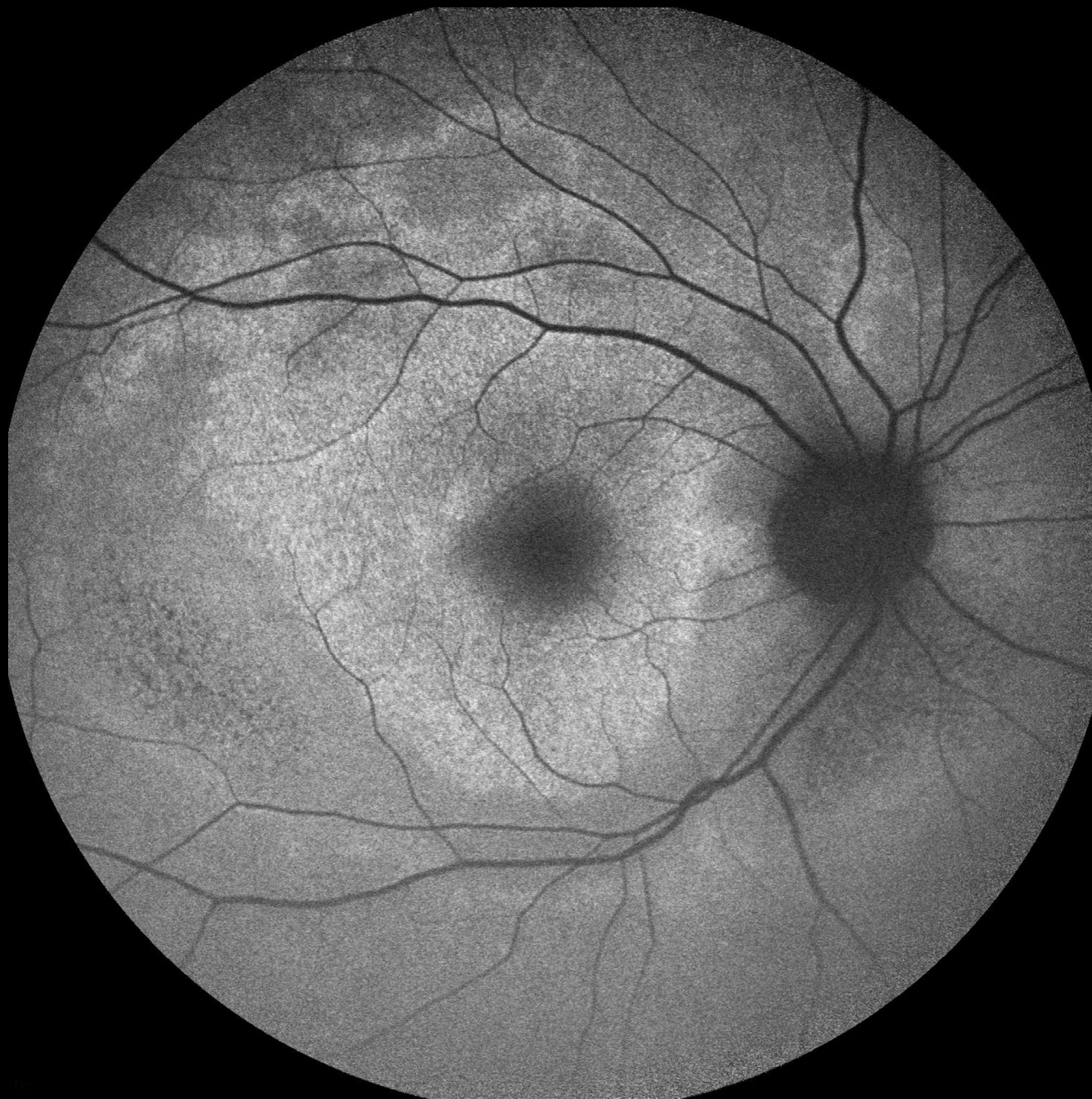

**Coxsackievirus-
Associated Unilateral
Acute Idiopathic
Maculopathy, Optic
Nerve Drusen**
Sean Grout, OCT-C

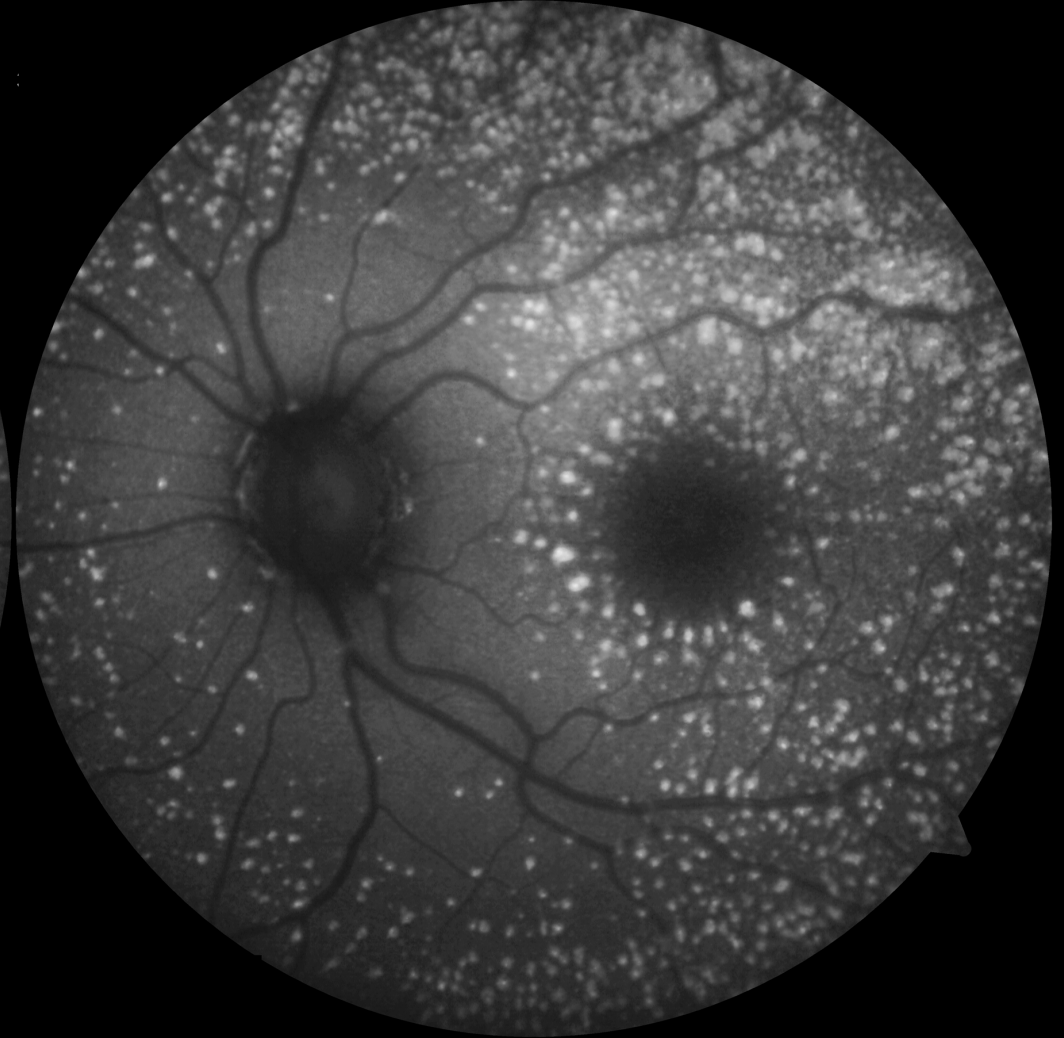
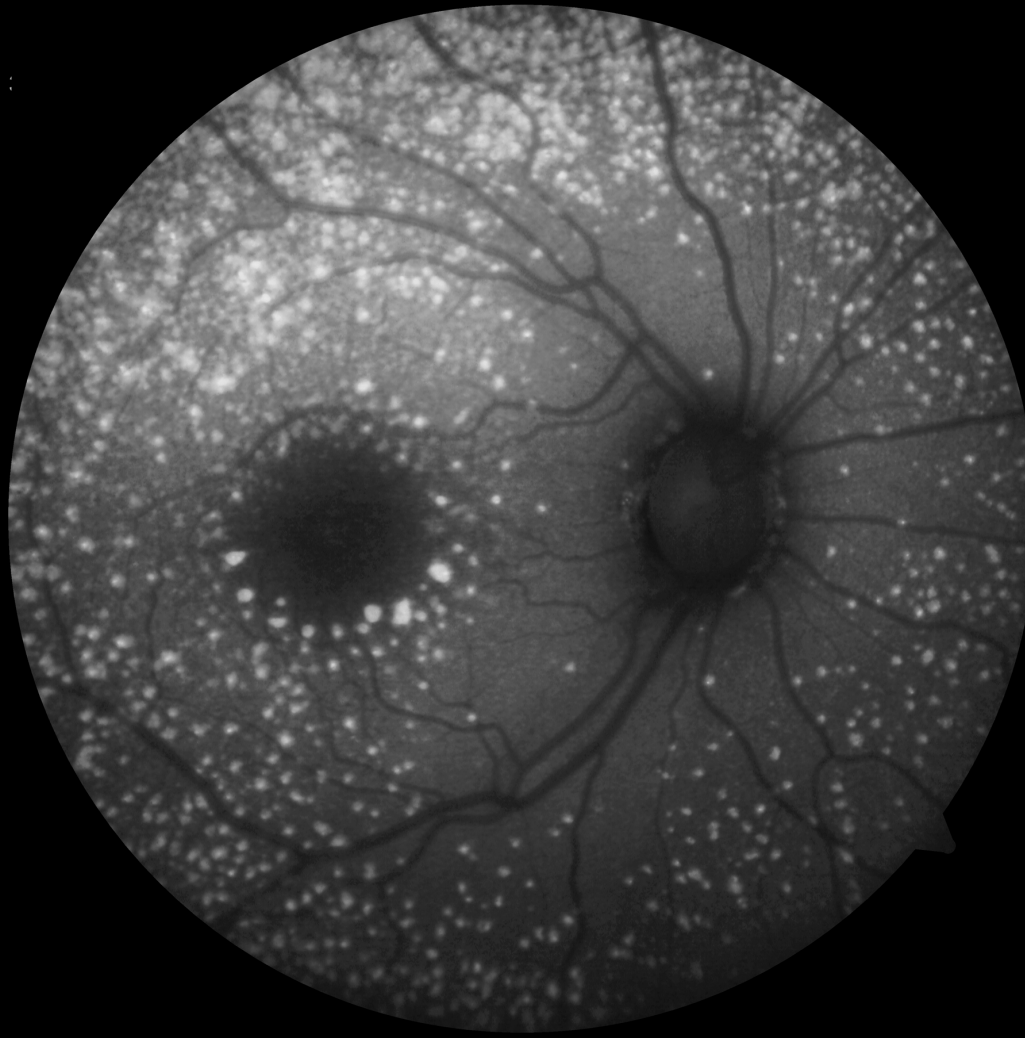




Geographic Atrophy
Tracey Troszak, CRA

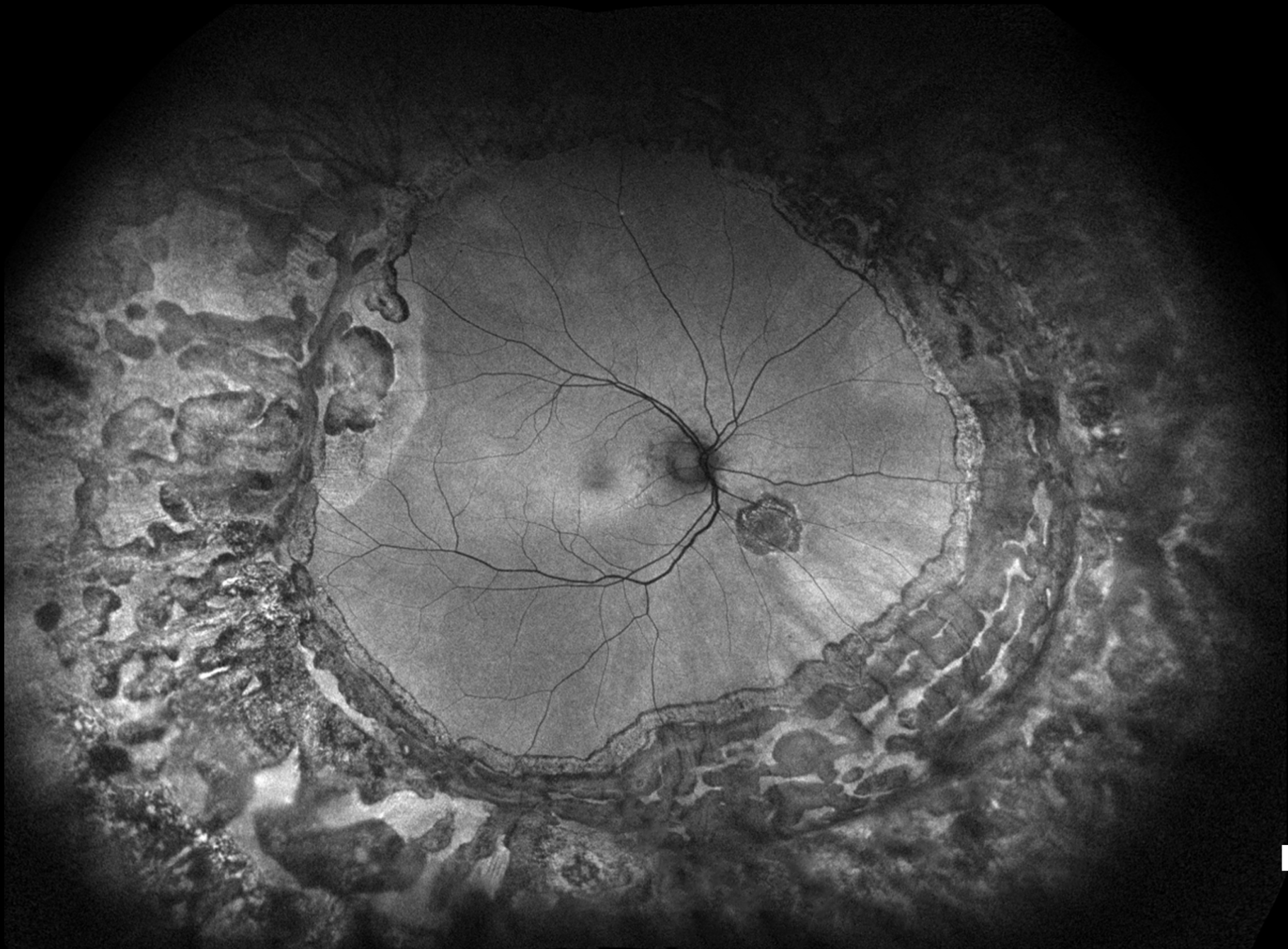

Rhodopsin Dominant RP
Darrin Landry, CRA



Benign Flecked Retina

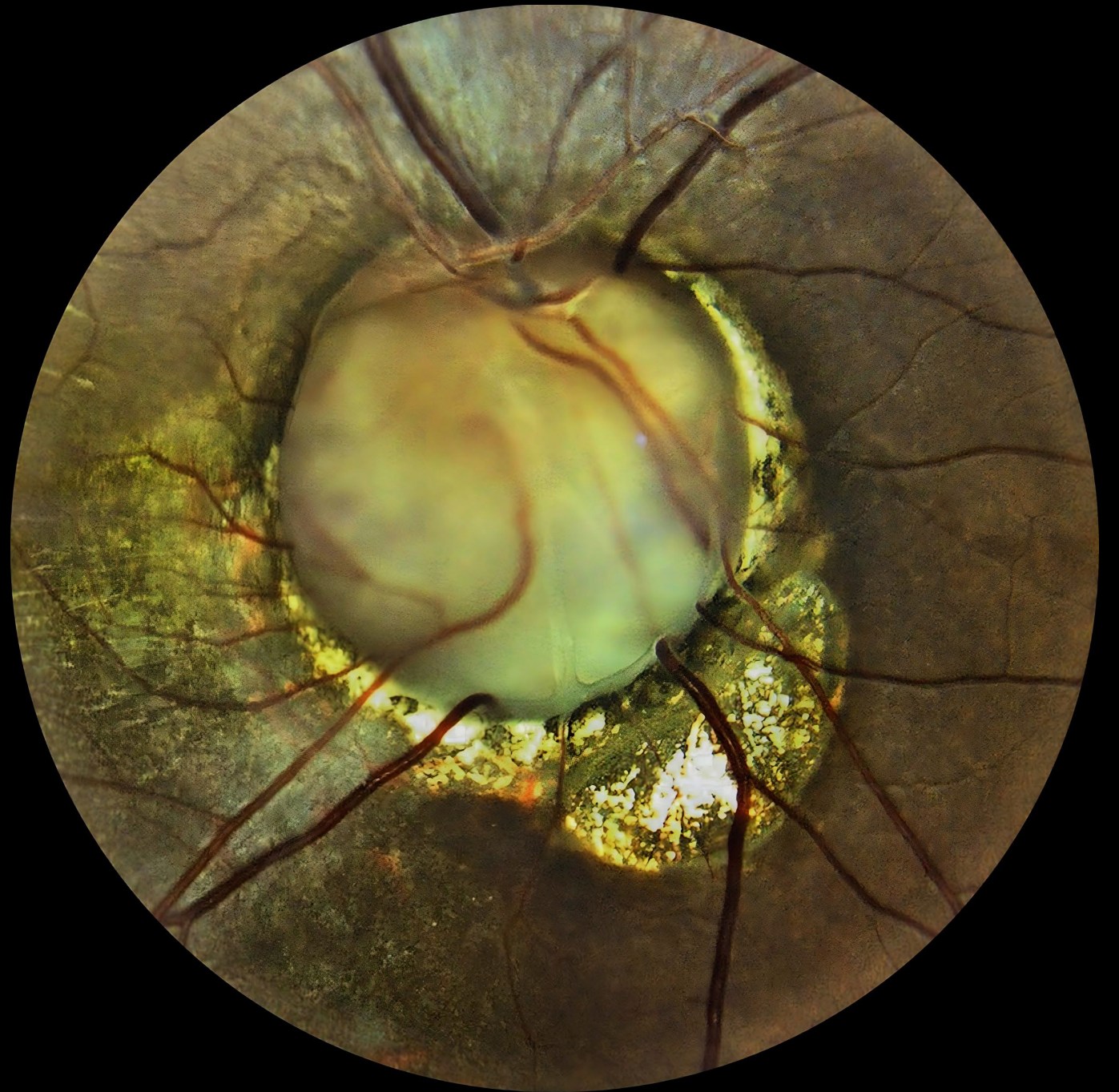
John Leo, BSc



Retinal Detachment
Jack Rodriguez

A fundus photograph showing the interior of the eye, including the retina and optic disc. The image is dark with a blue-green tint and contains numerous small, bright, circular spots of light, likely representing retinal lesions or artifacts from the imaging process. The text is overlaid on the left side of the image.

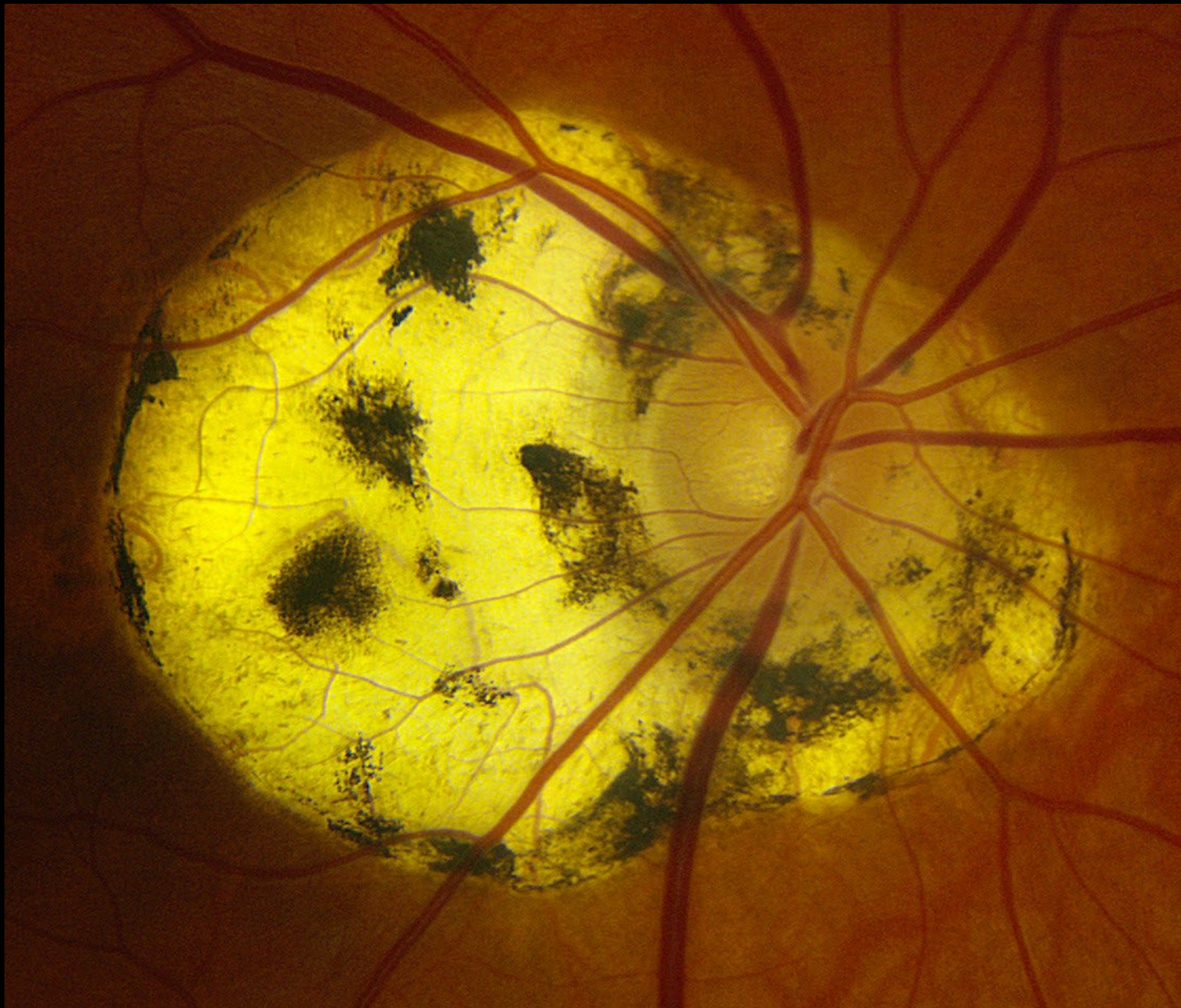
**Fundus Photography, High
Magnification, 20°**



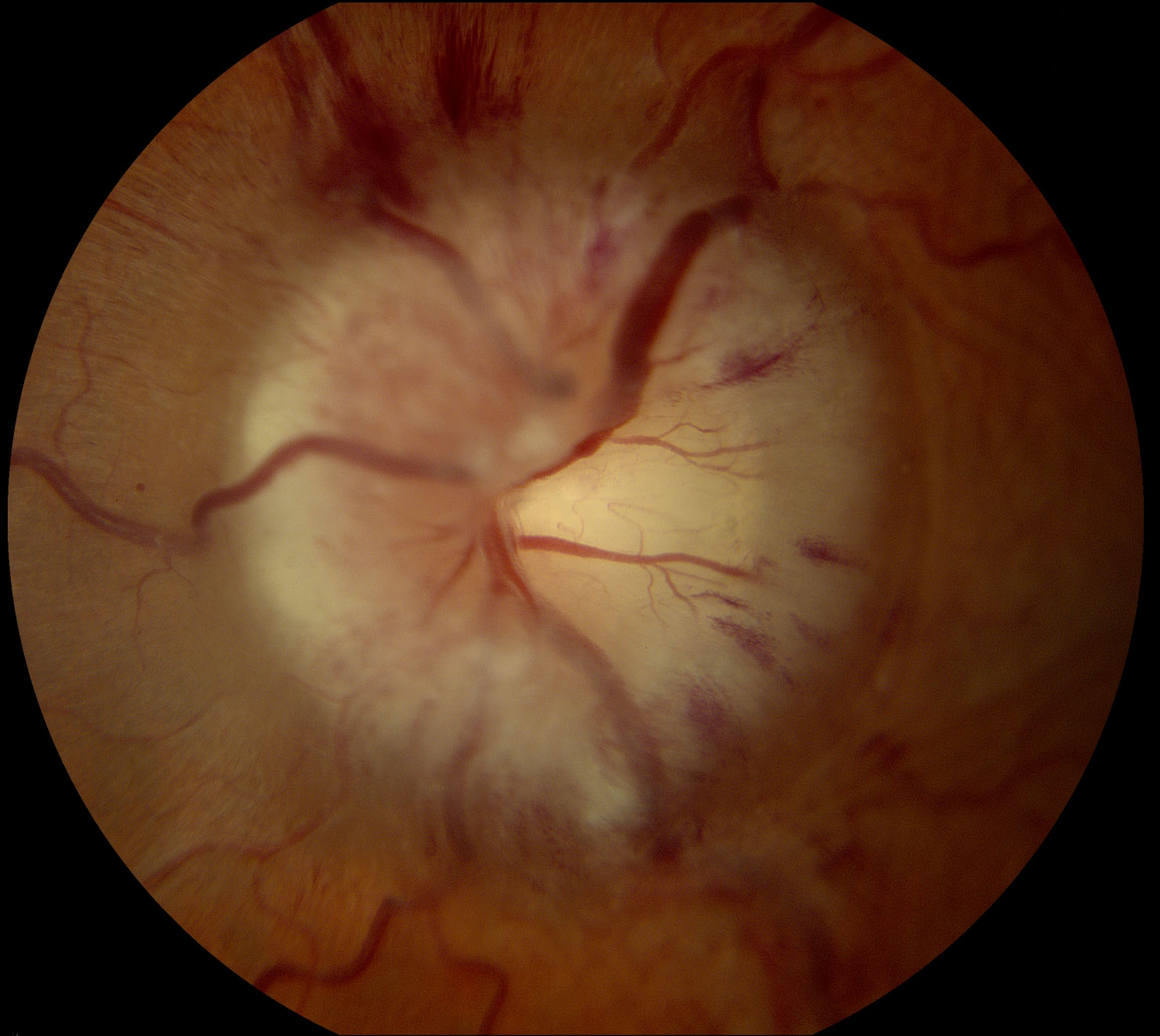
Fuchs Coloboma

Prasanna Ramesh, MS, DNB

Shruthy Ramesh, DNB, MS



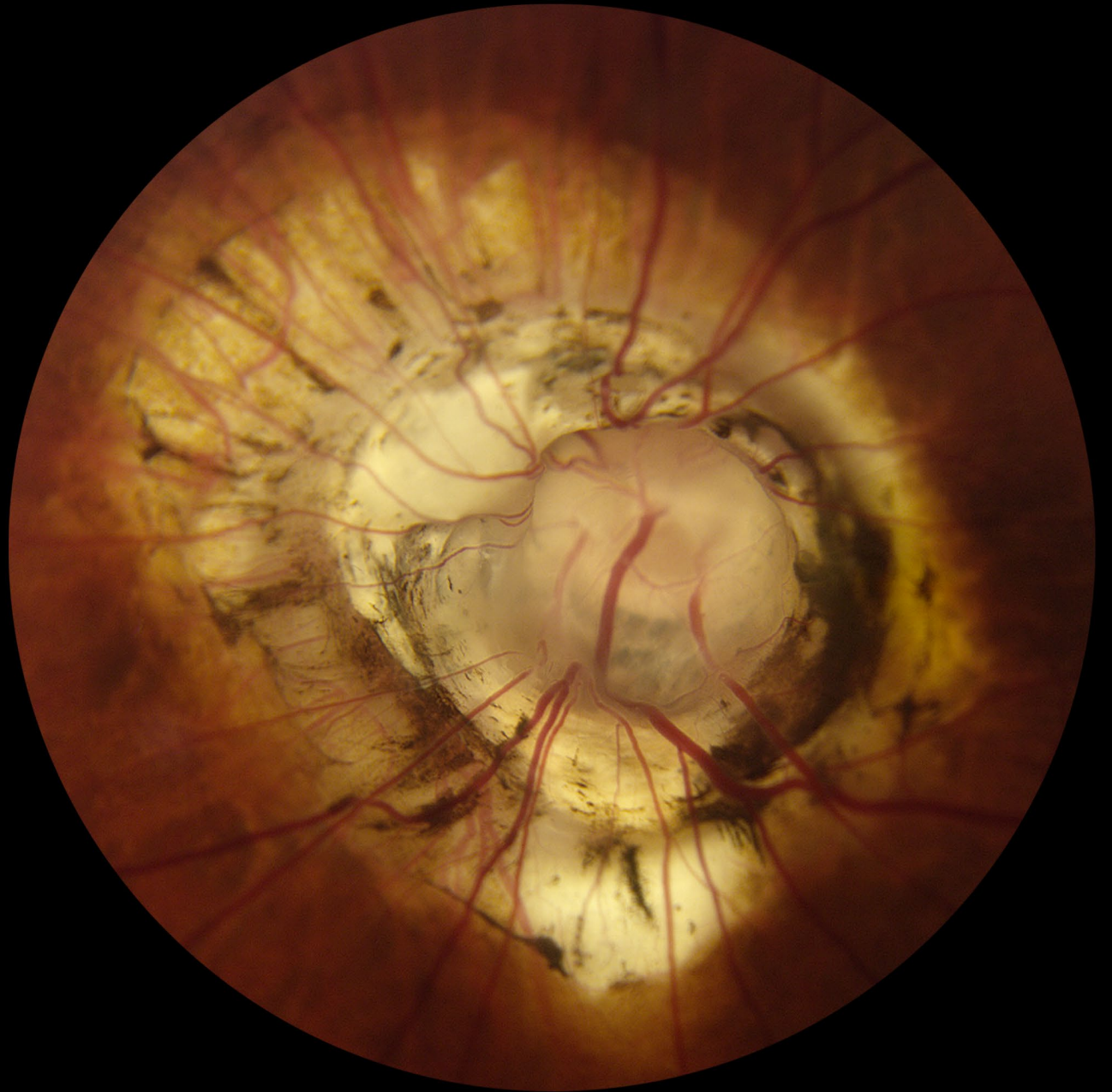
Optic Atrophy
Tracey Troszak, CRA



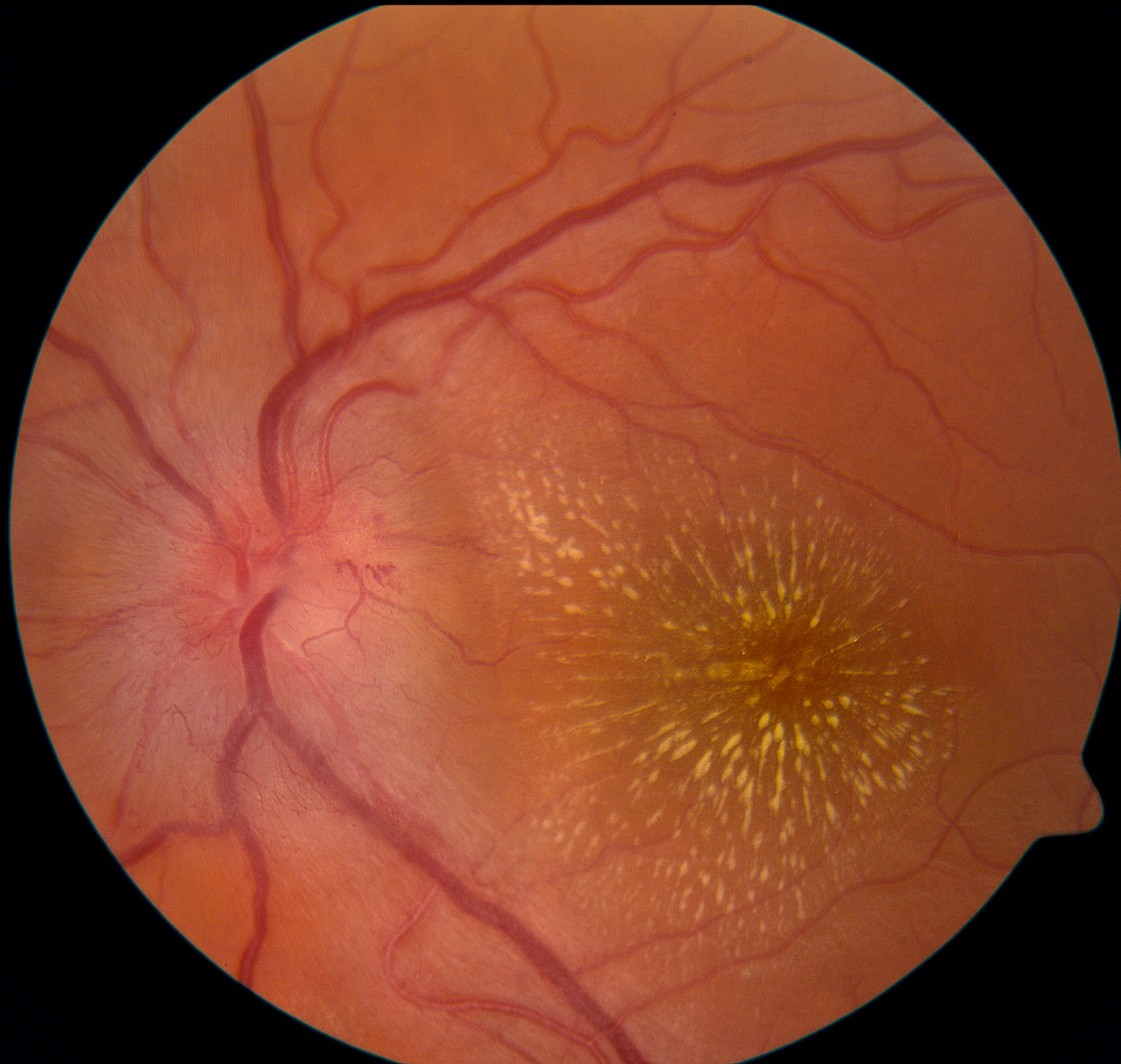
Abducens Nerve Palsy
Nicole Radunzel, BA, CRA

A fundus photograph of a normal eye, showing the retina and optic disc. The image is taken at a 30-40 degree angle, providing a clear view of the central retina. The optic disc is visible on the right side, and the macula is in the center. The retinal vessels are clearly visible, branching out from the optic disc. The overall appearance is normal, with no signs of pathology.

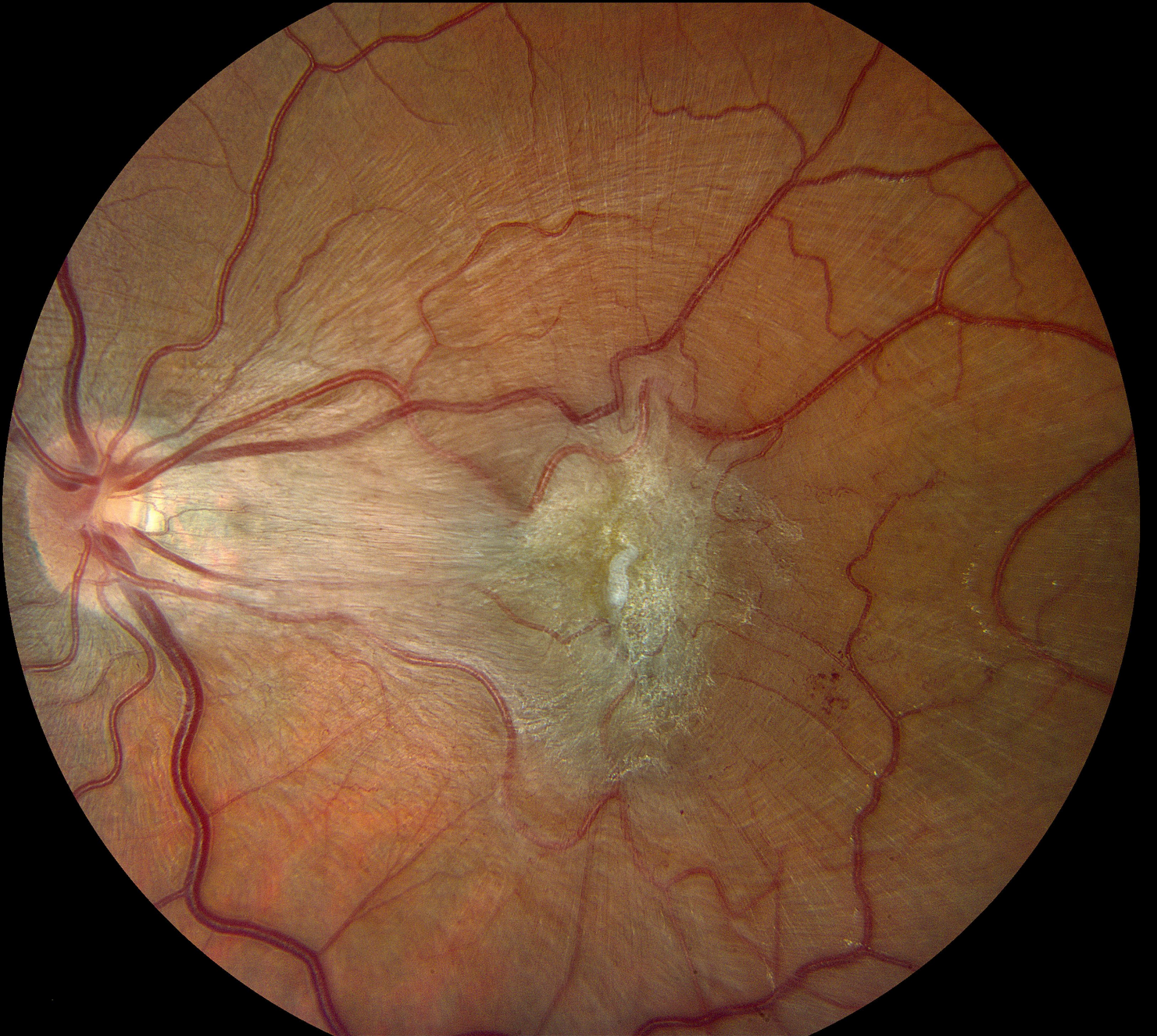
**Fundus Photography, Normal,
30°-40°**



Staphyloma of the Left Eye
Anahli Vazquez-Galvan, OCT-C



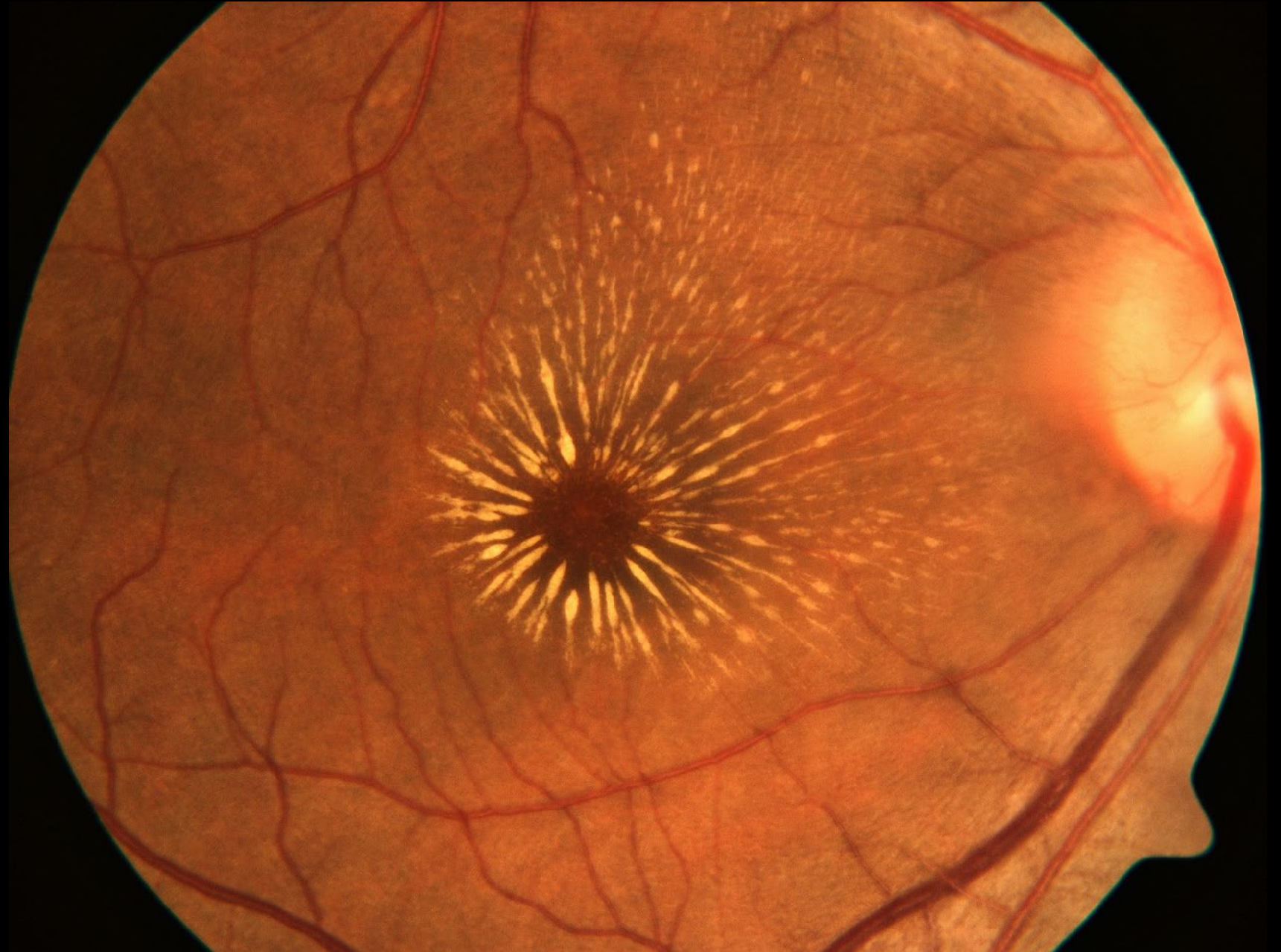
Neuroretinitis with Macular Star
Karla Woods, COA

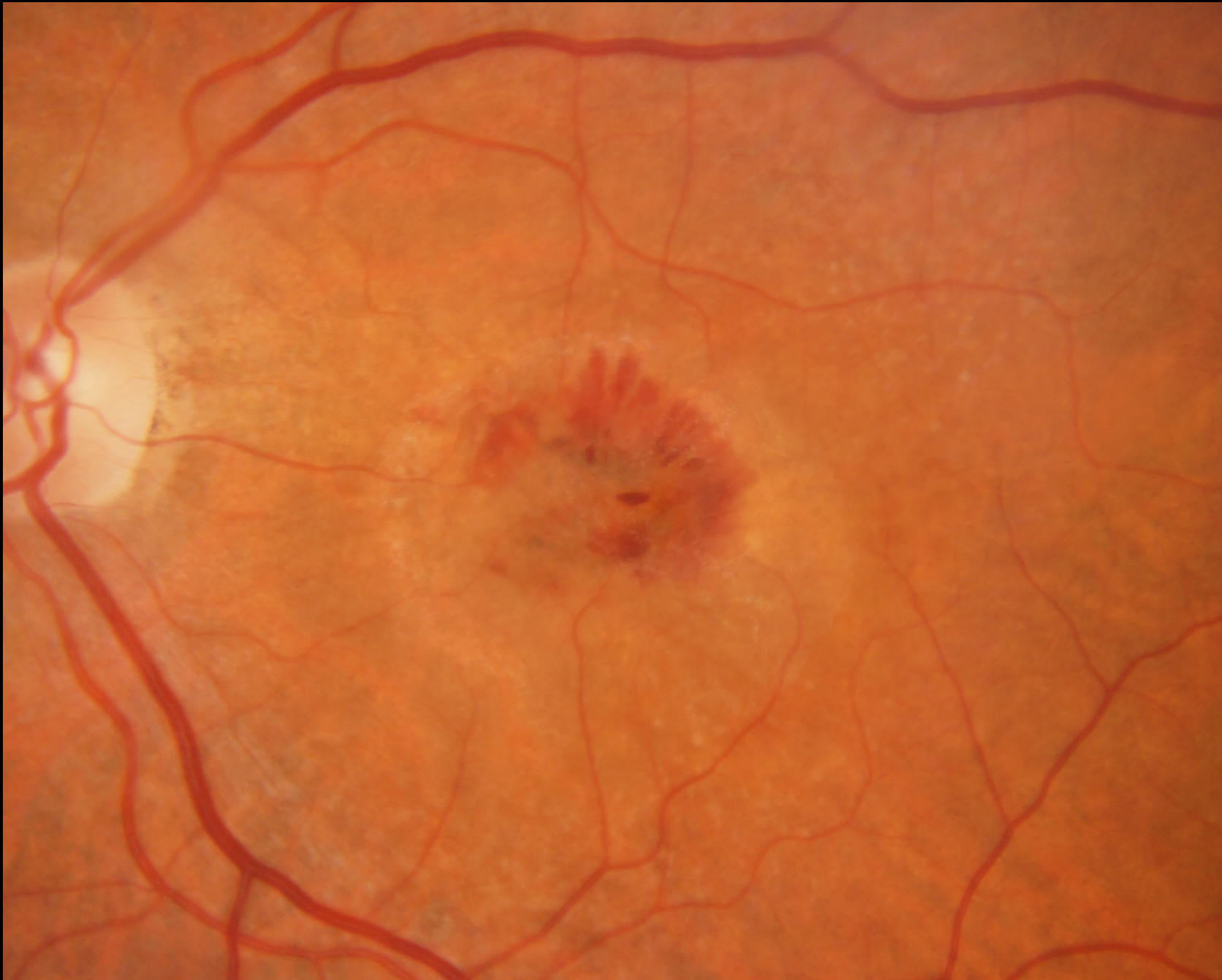

Vitreoretinal Tuft
Sarah Skiles, MA, BA, CRA

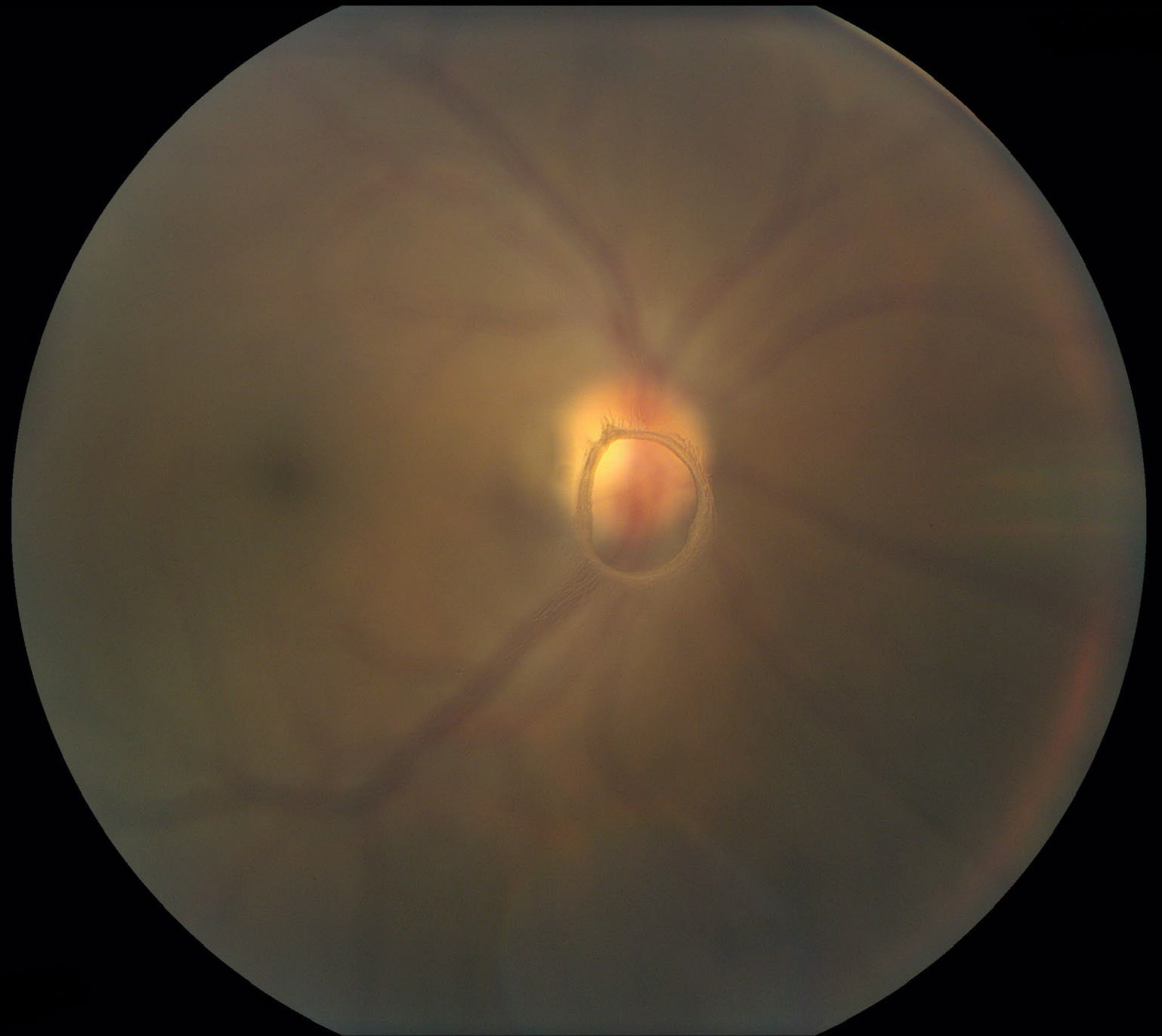


Macular Star
John Leo, BSc

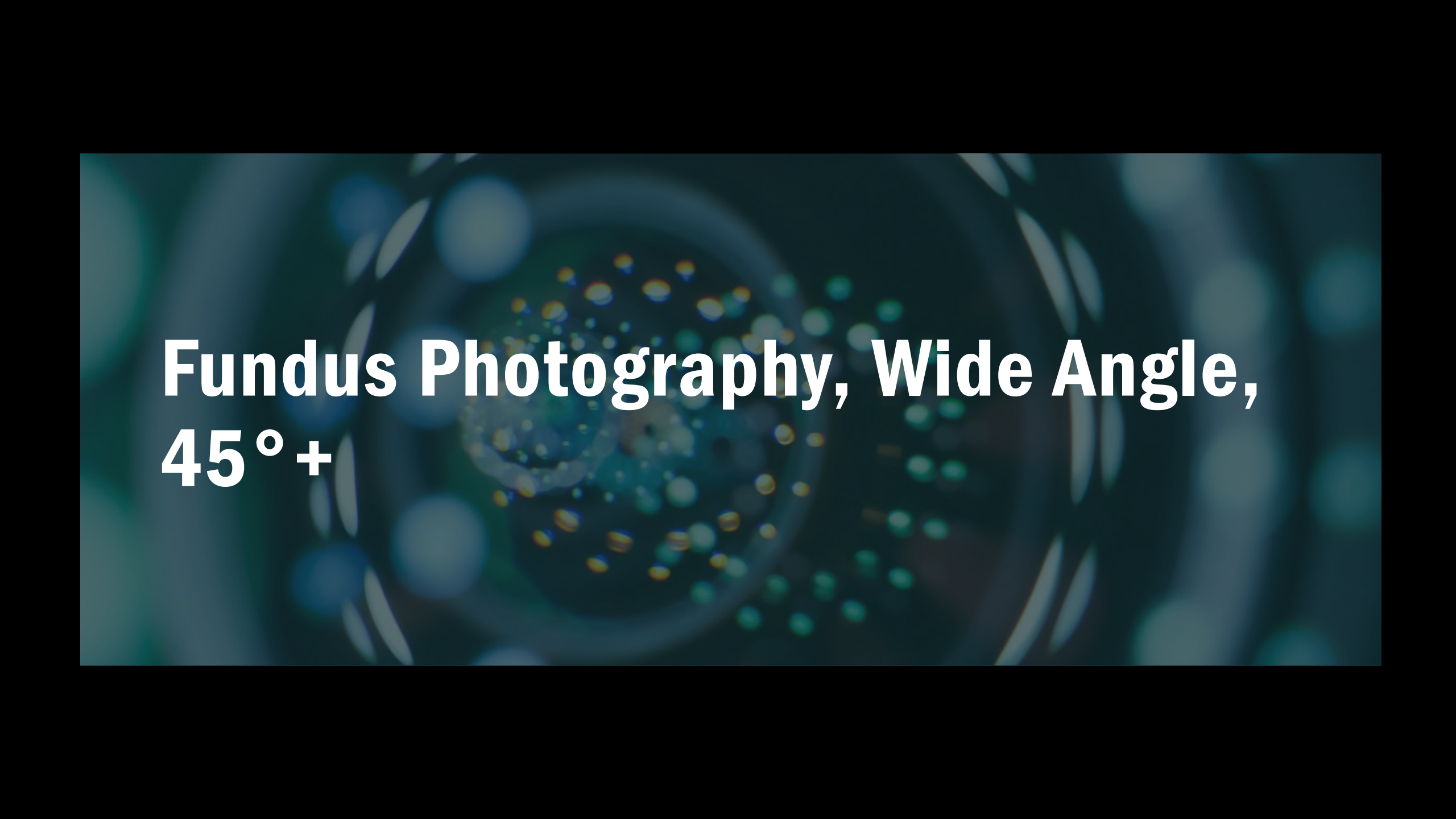




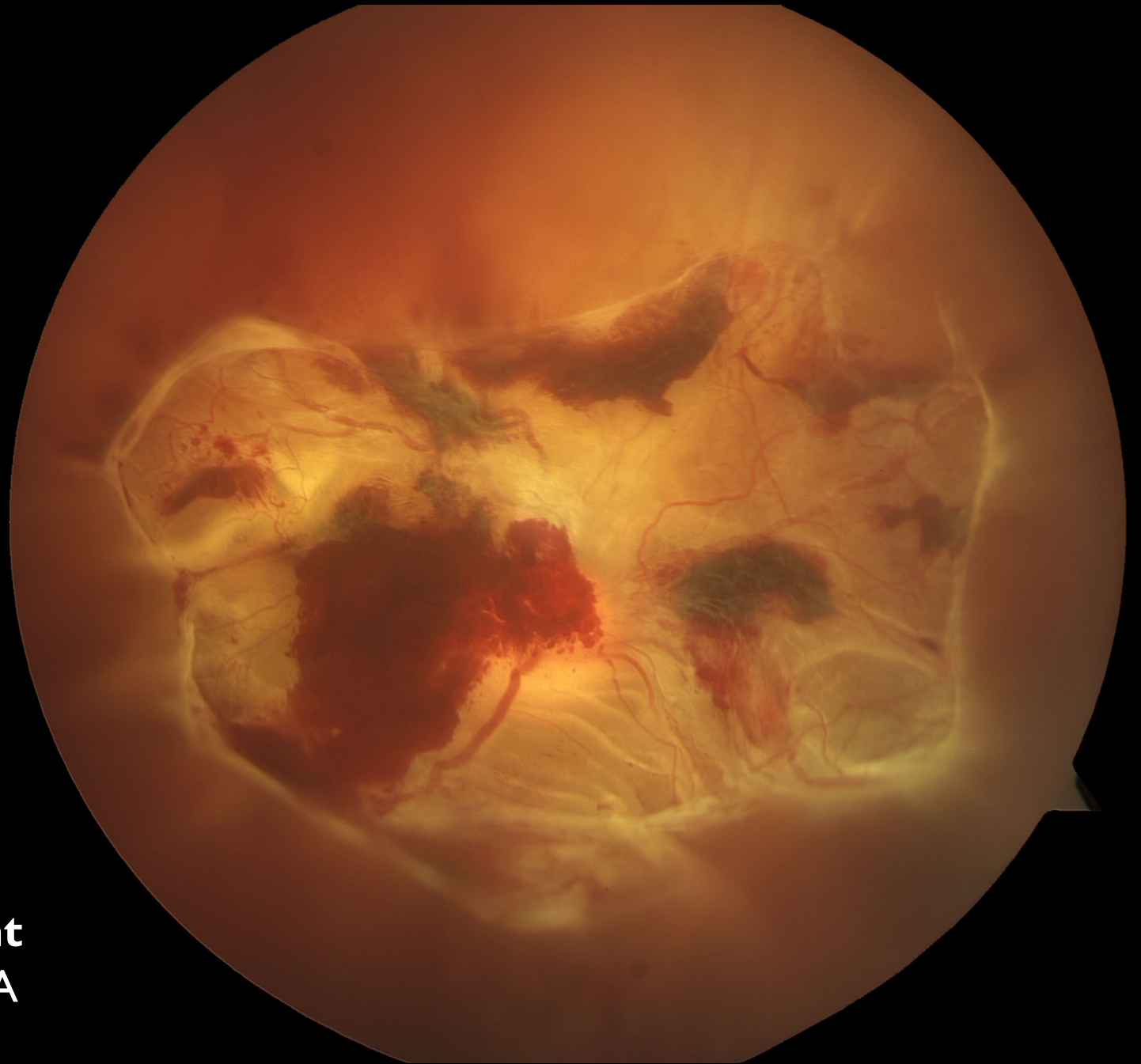
Wet ARMD
Megan Walsh, CRA



Weiss Ring
Jason Calhoun, COA

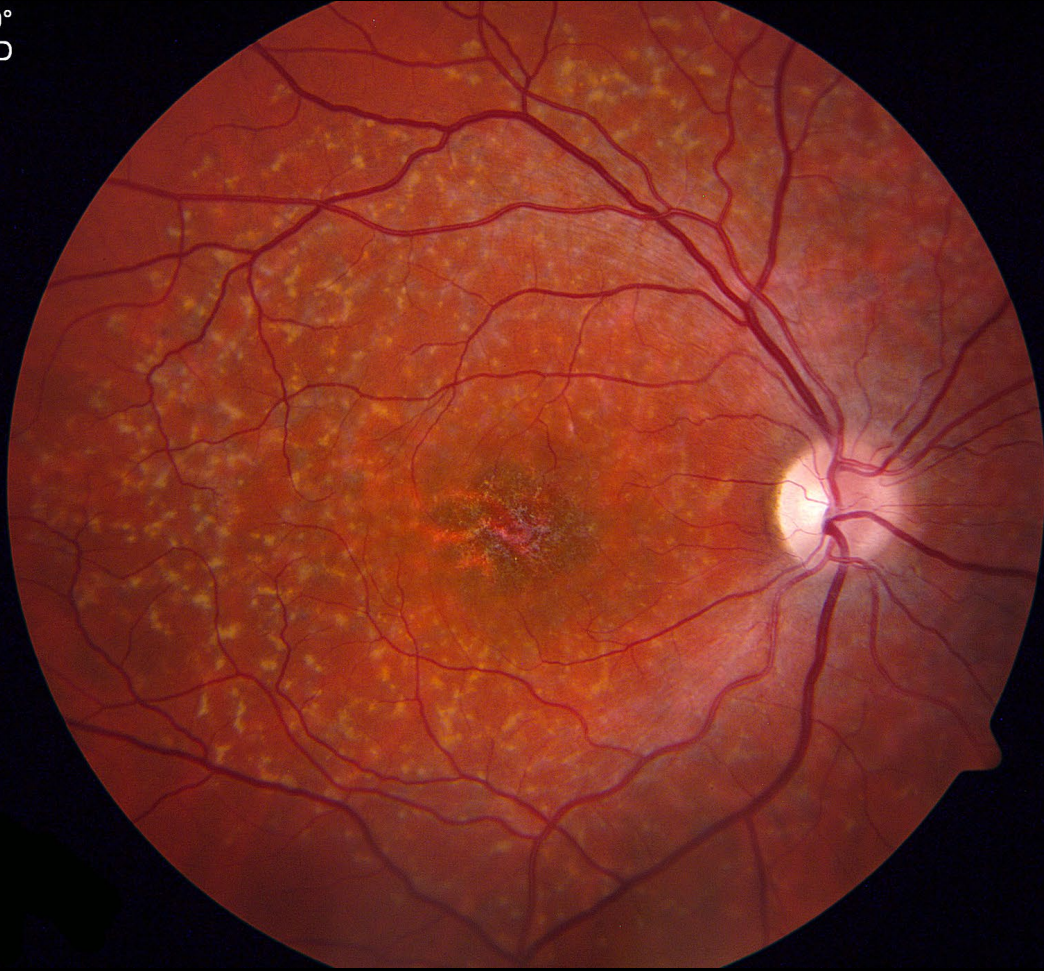A fundus photograph of the retina, showing a wide field of view. The image is dark with a blue-green tint. The optic disc is visible on the right side, and the macula is in the center. There are numerous small, bright spots scattered across the retina, which could be microaneurysms or other retinal lesions. The text is overlaid on the left side of the image.

**Fundus Photography, Wide Angle,
45° +**

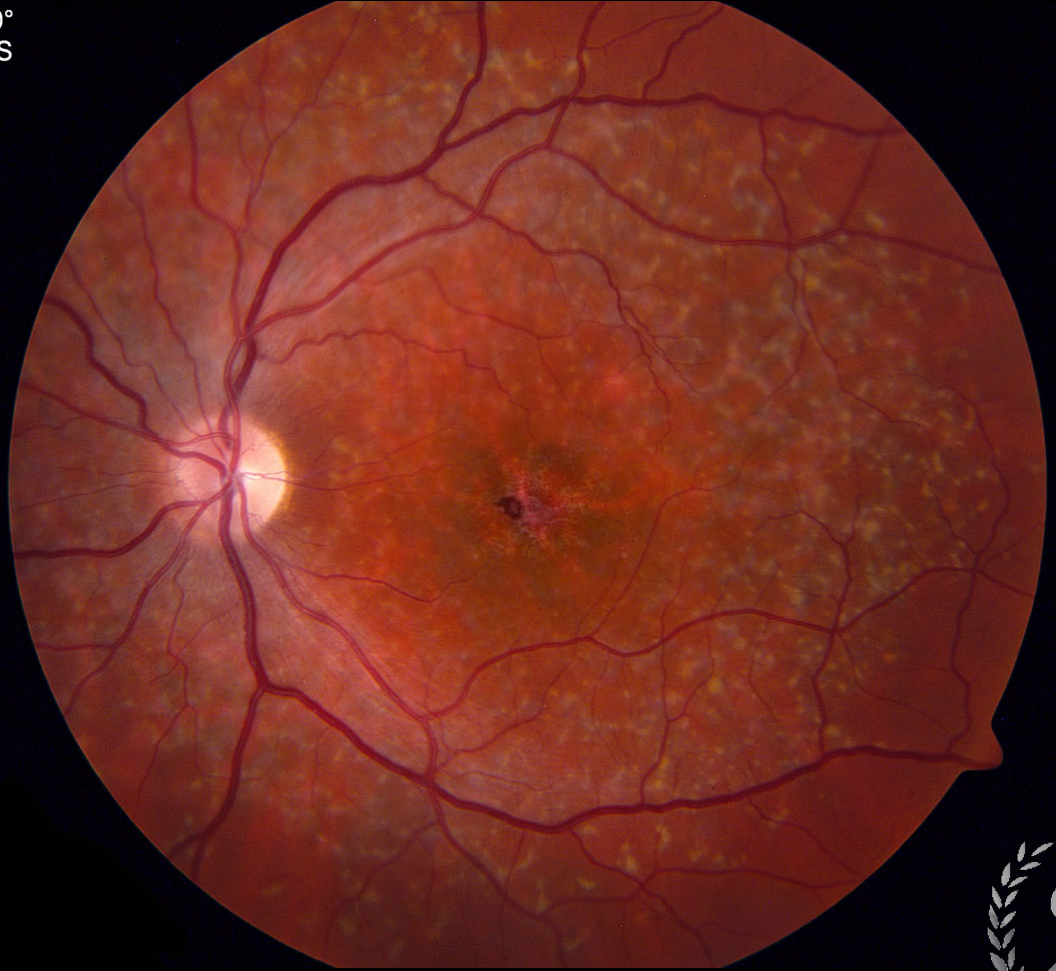

PDR with Retinal Detachment
Noelle Pensec Rovensky, BSc, CRA

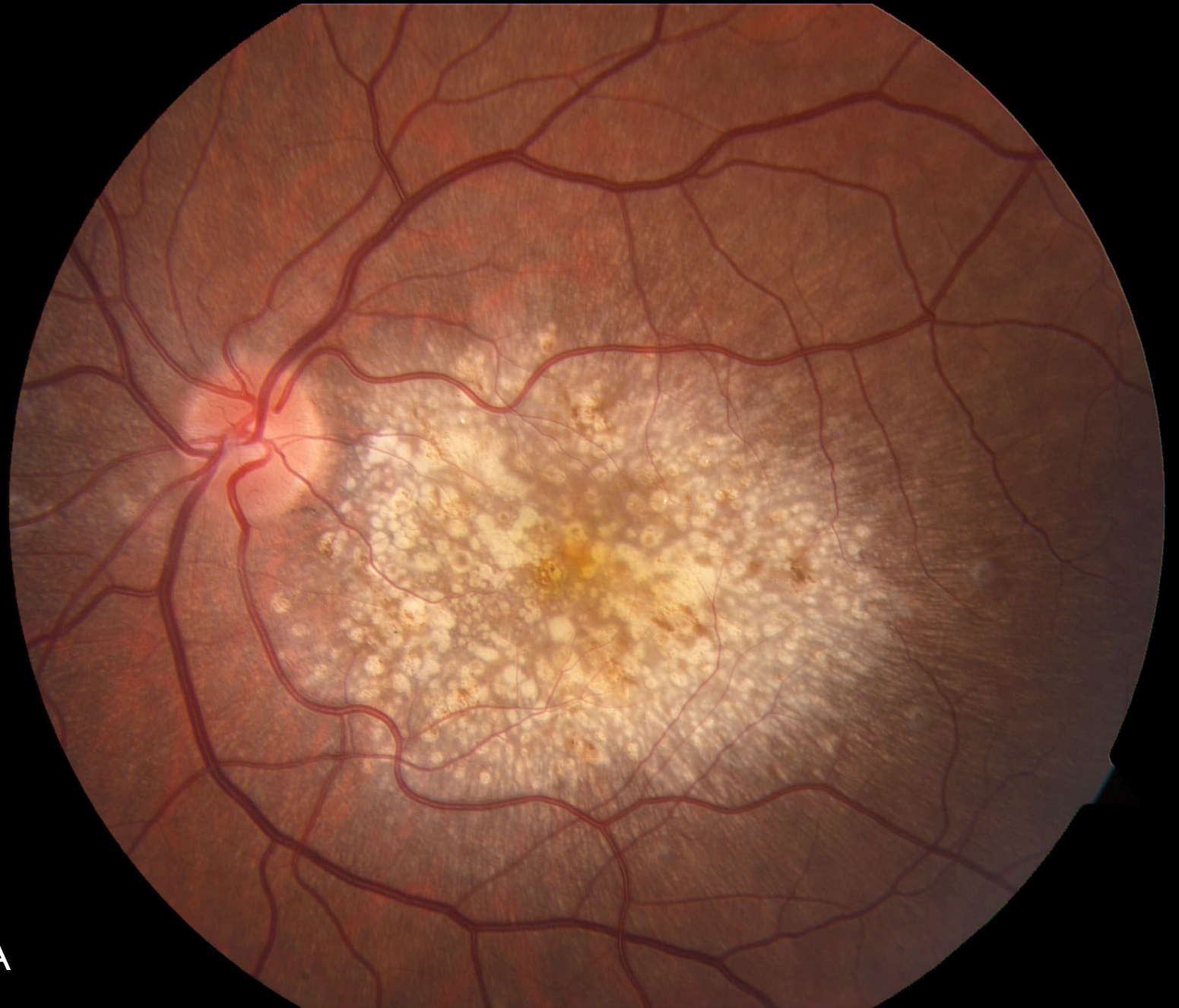
50°
OD



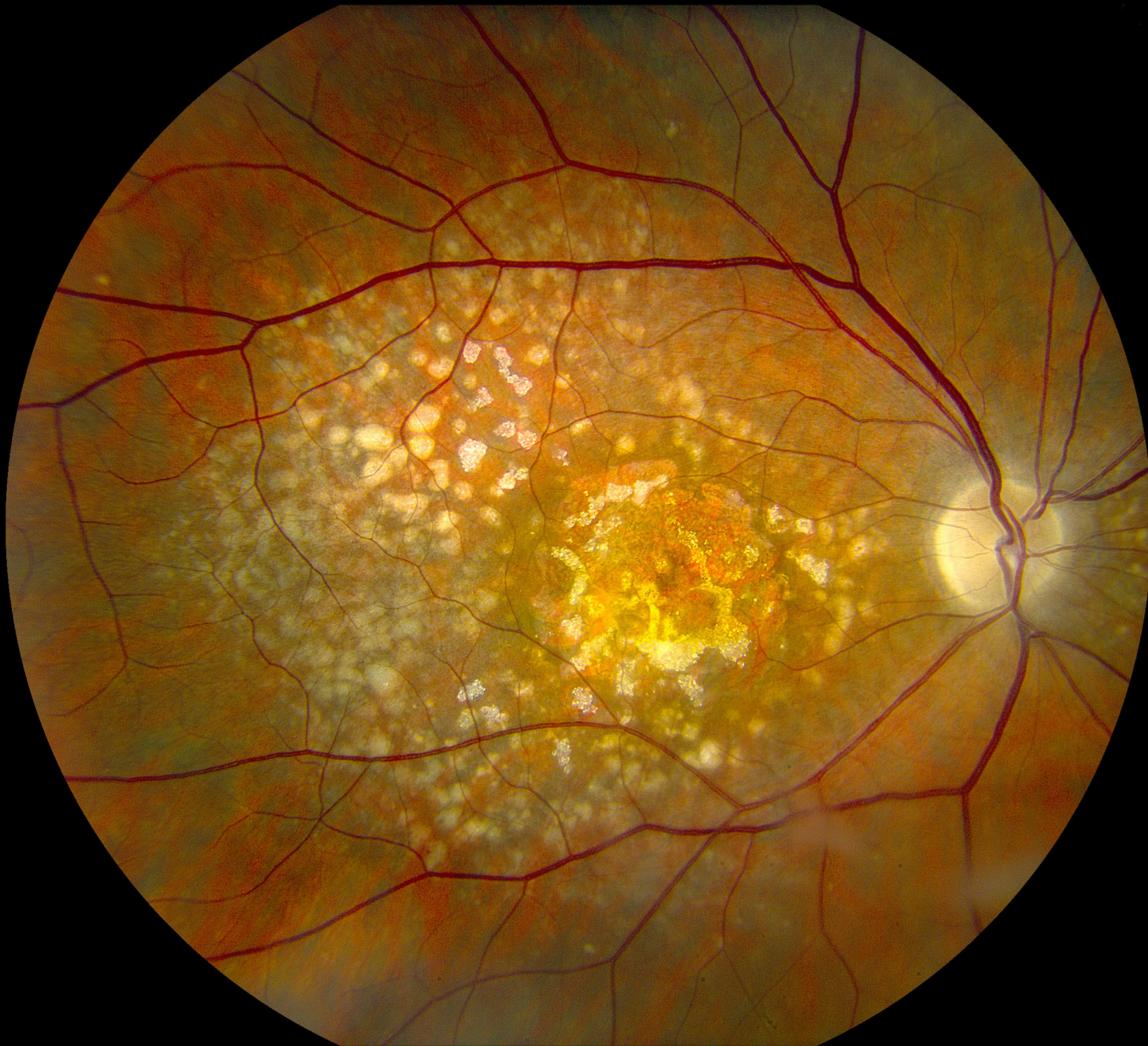50°
OS



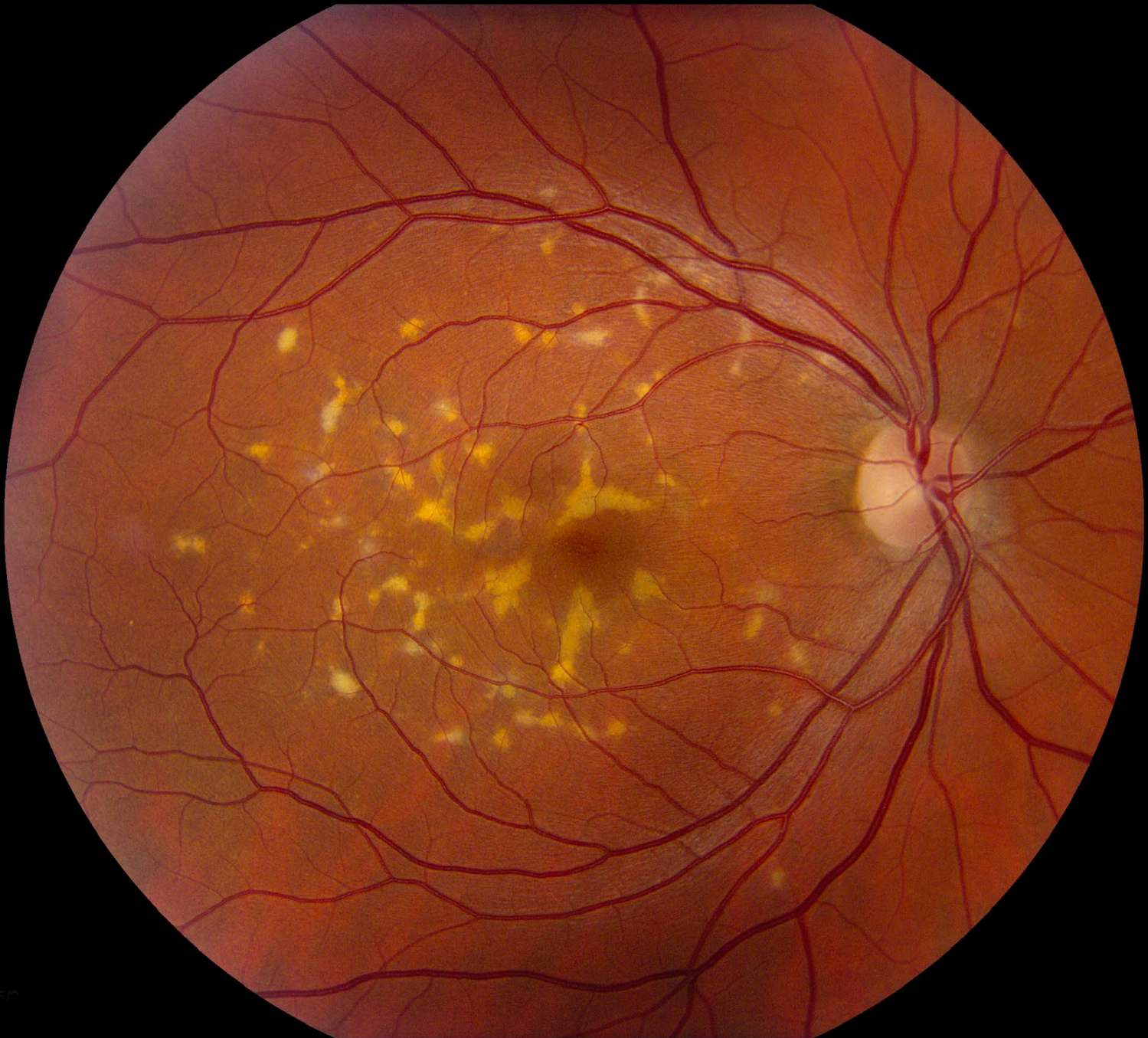Stargardt's Disease
Gary Miller, CRA



**Doyne's Honeycomb Retinal
Dystrophy**
Noelle Pensec Rovensky, BSc, CRA



Malattia Leveninese
Sarah Skiles, MA, BA, CRA



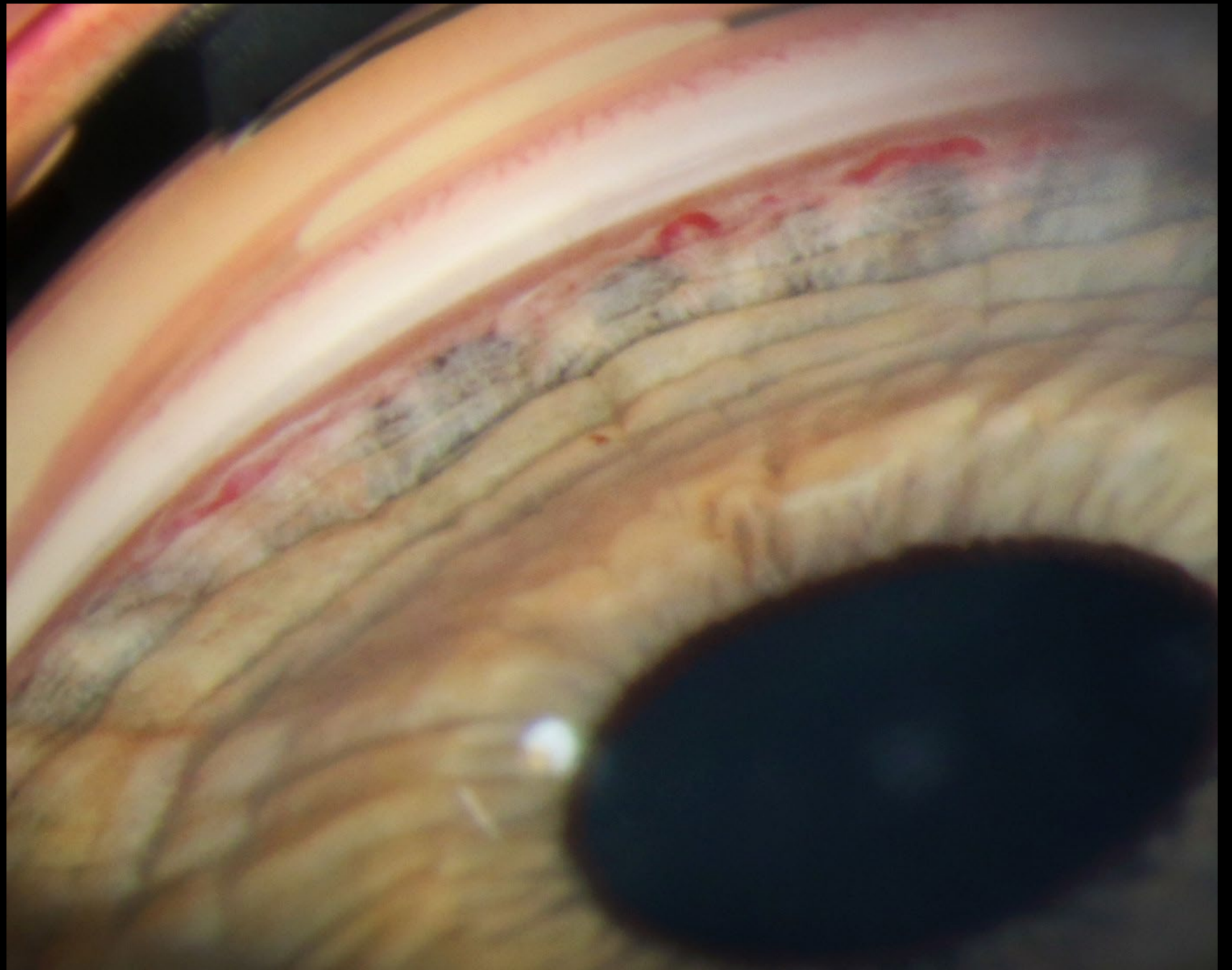
Stargardt's Disease
Jason Calhoun, COA

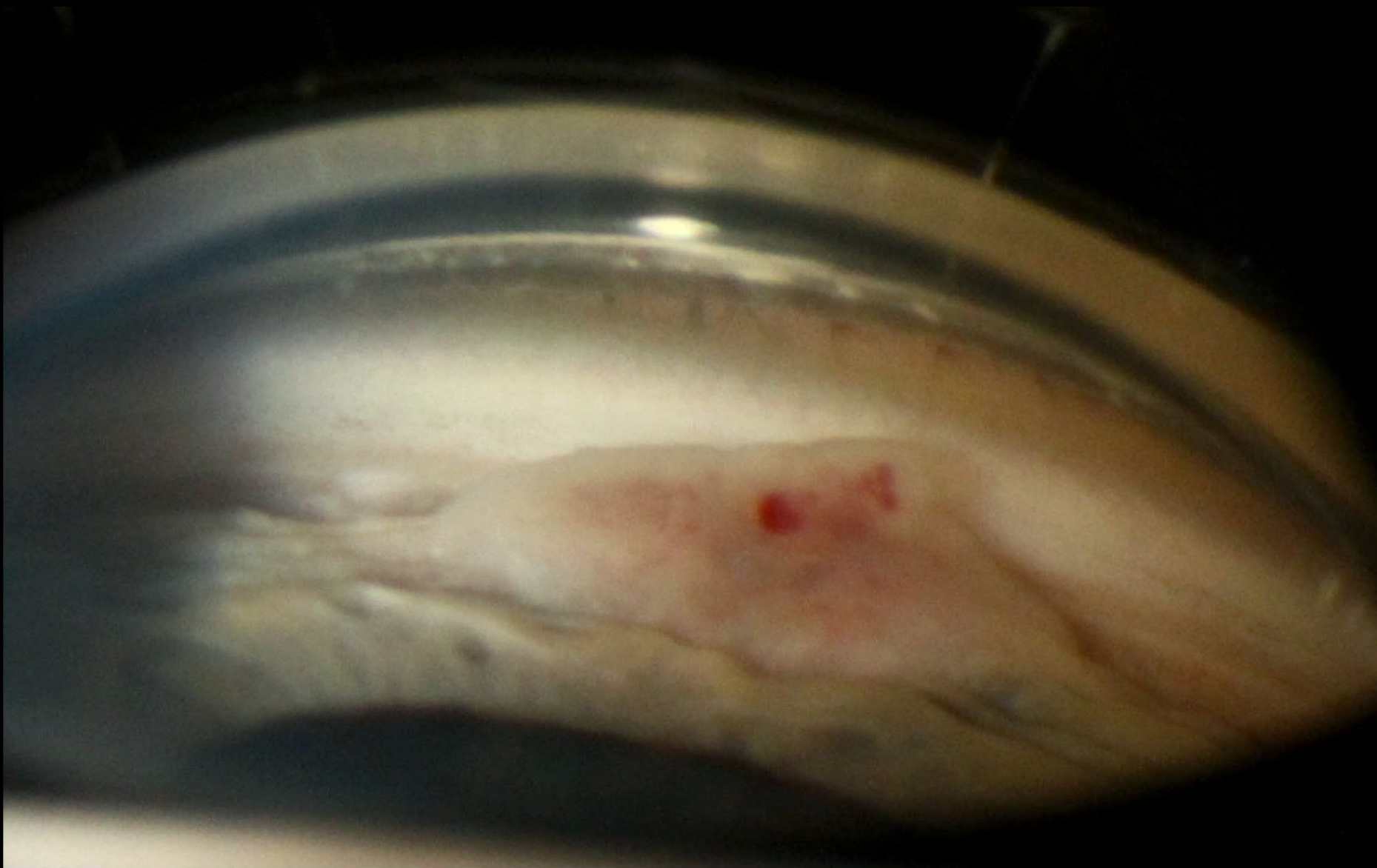
The background of the slide is a dark, teal-colored image showing a complex, circular pattern of light spots, likely representing a diffraction pattern or a microscopic view of a crystal structure. The spots are arranged in concentric rings and have a slight iridescent glow. The overall effect is abstract and scientific.

Gonio Photography

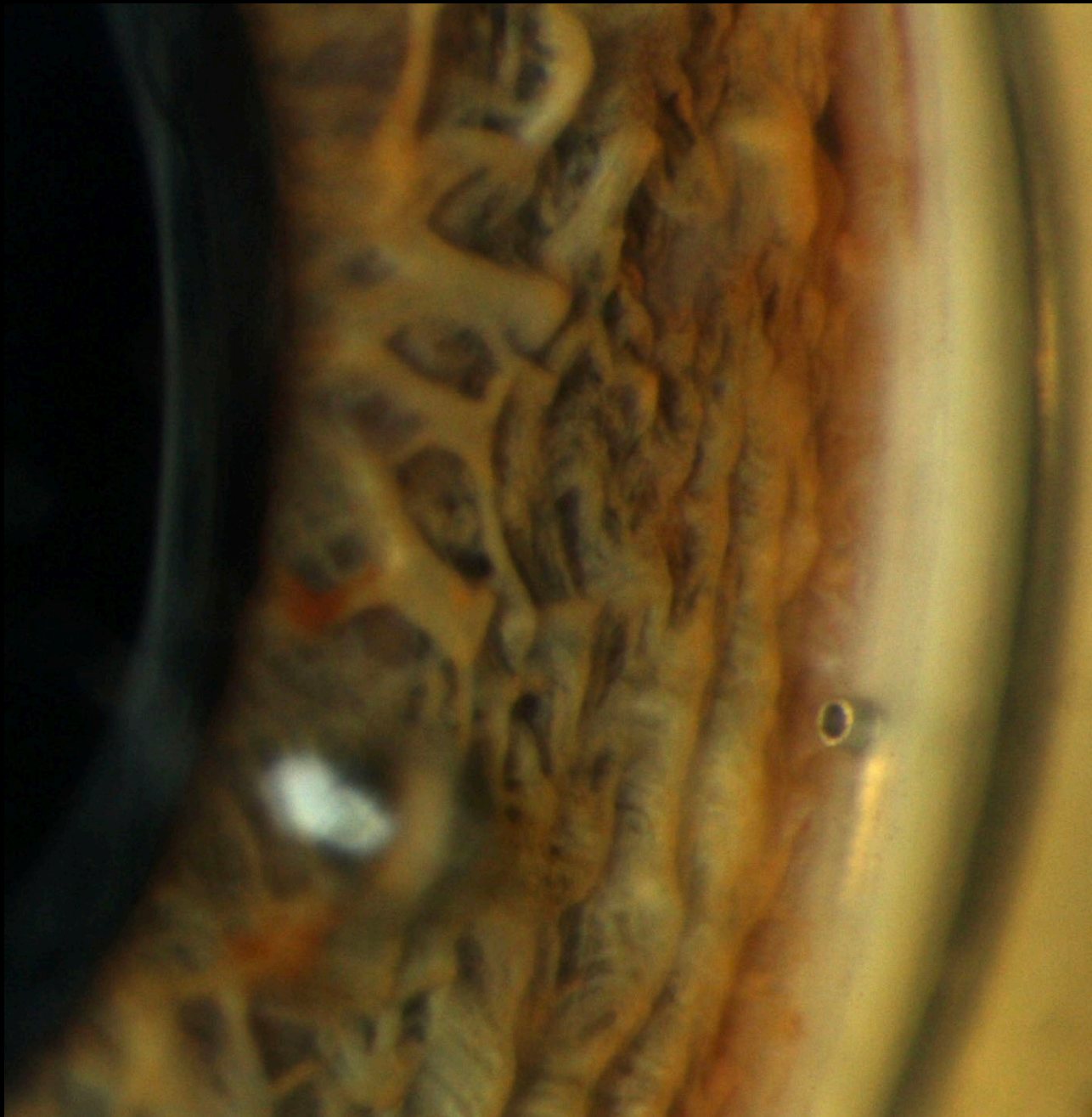


Iris neovascularization
Veronica Jones, BA

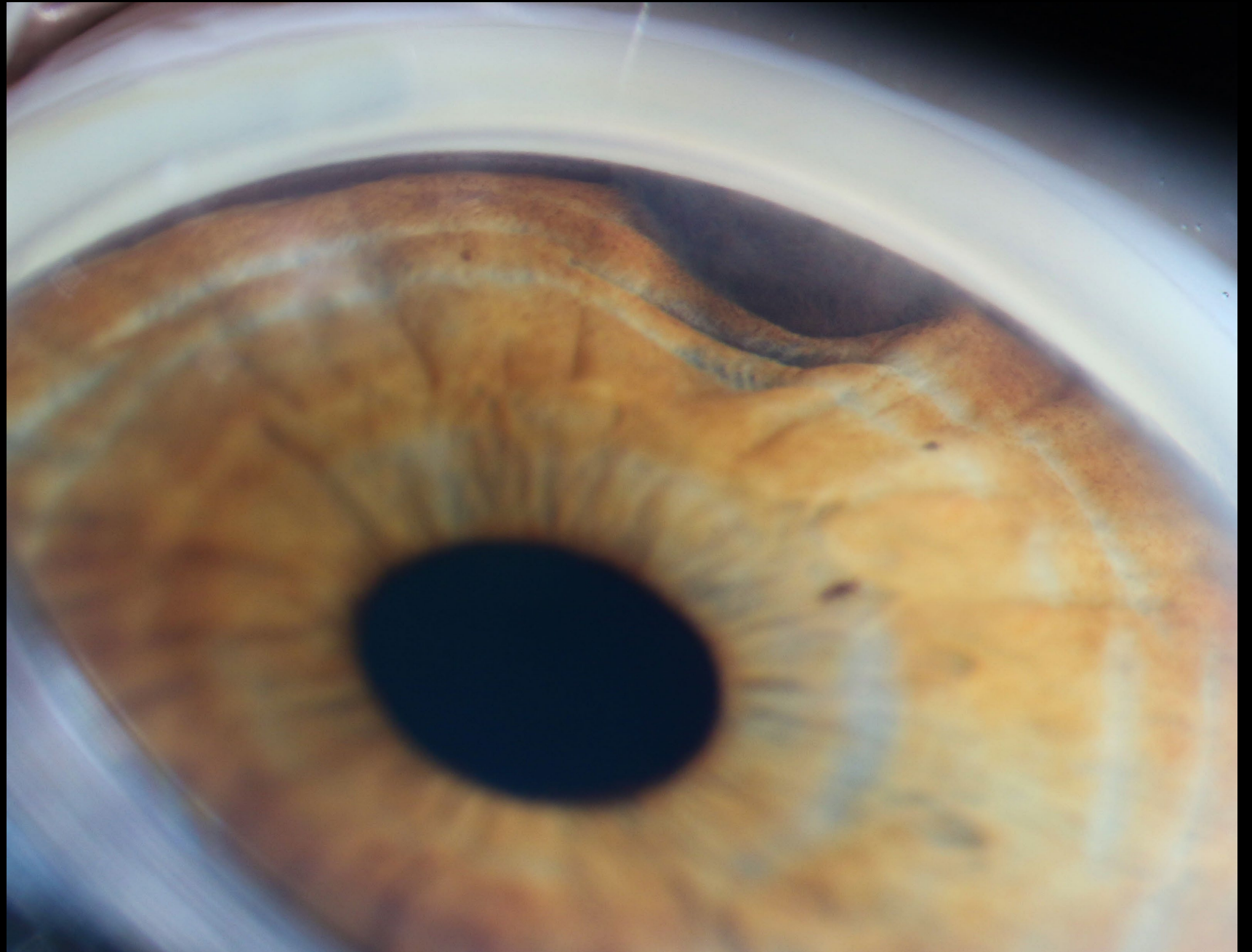




Iris Melanoma
Sarah Skiles, MA, BA, CRA



I stent
Jason Calhoun, COA



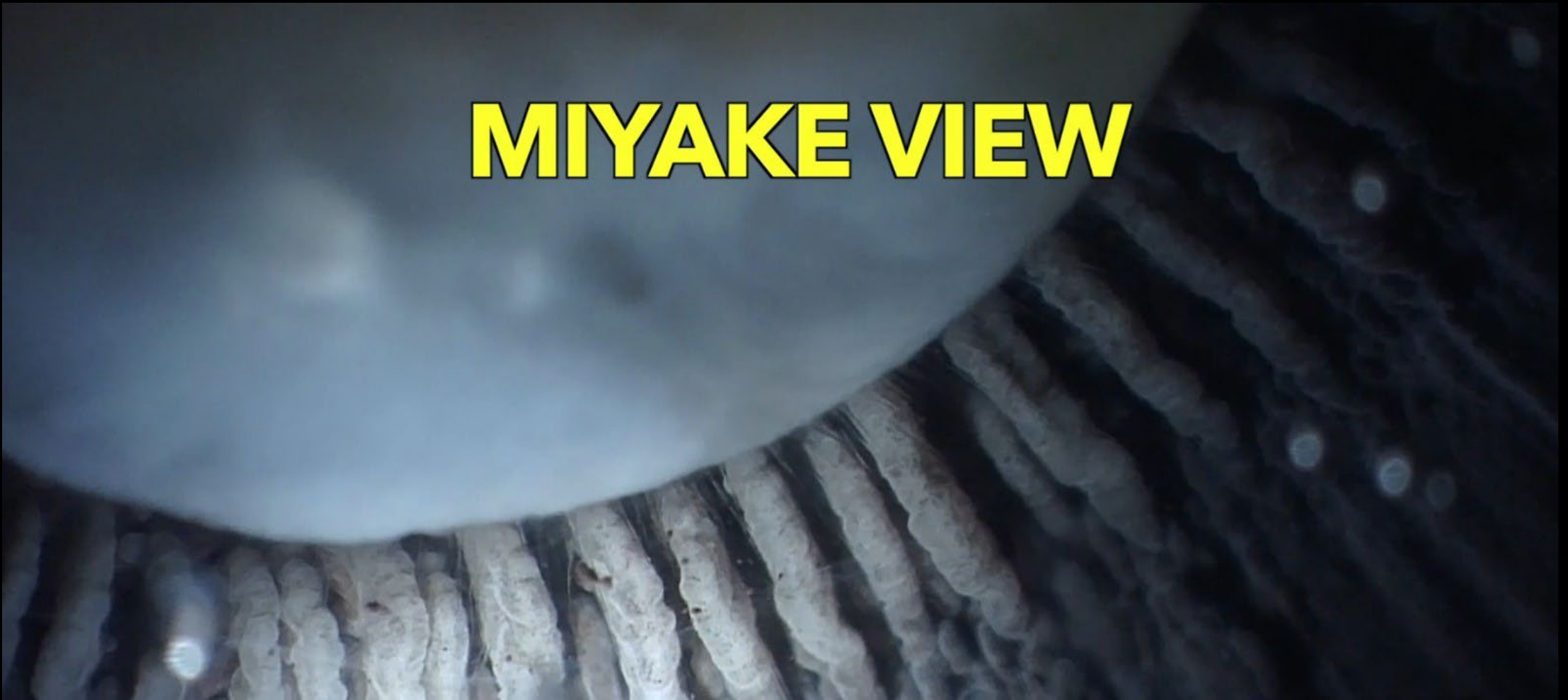Iris Nevus

Sarah Hugar, CRA

A microscopic image showing a central cluster of small, colorful, spherical particles. The particles are arranged in a roughly circular pattern and exhibit a variety of colors including yellow, orange, green, and blue. The background is dark and out of focus, with some faint, larger structures visible. The overall appearance is that of a biological or chemical specimen under a microscope.

Gross Specimen Photography

MIYAKE VIEW



Ciliary Processes and Posterior Zonule Insertion

Kumar Doctor, MD

Shivani Pattnaik, MS

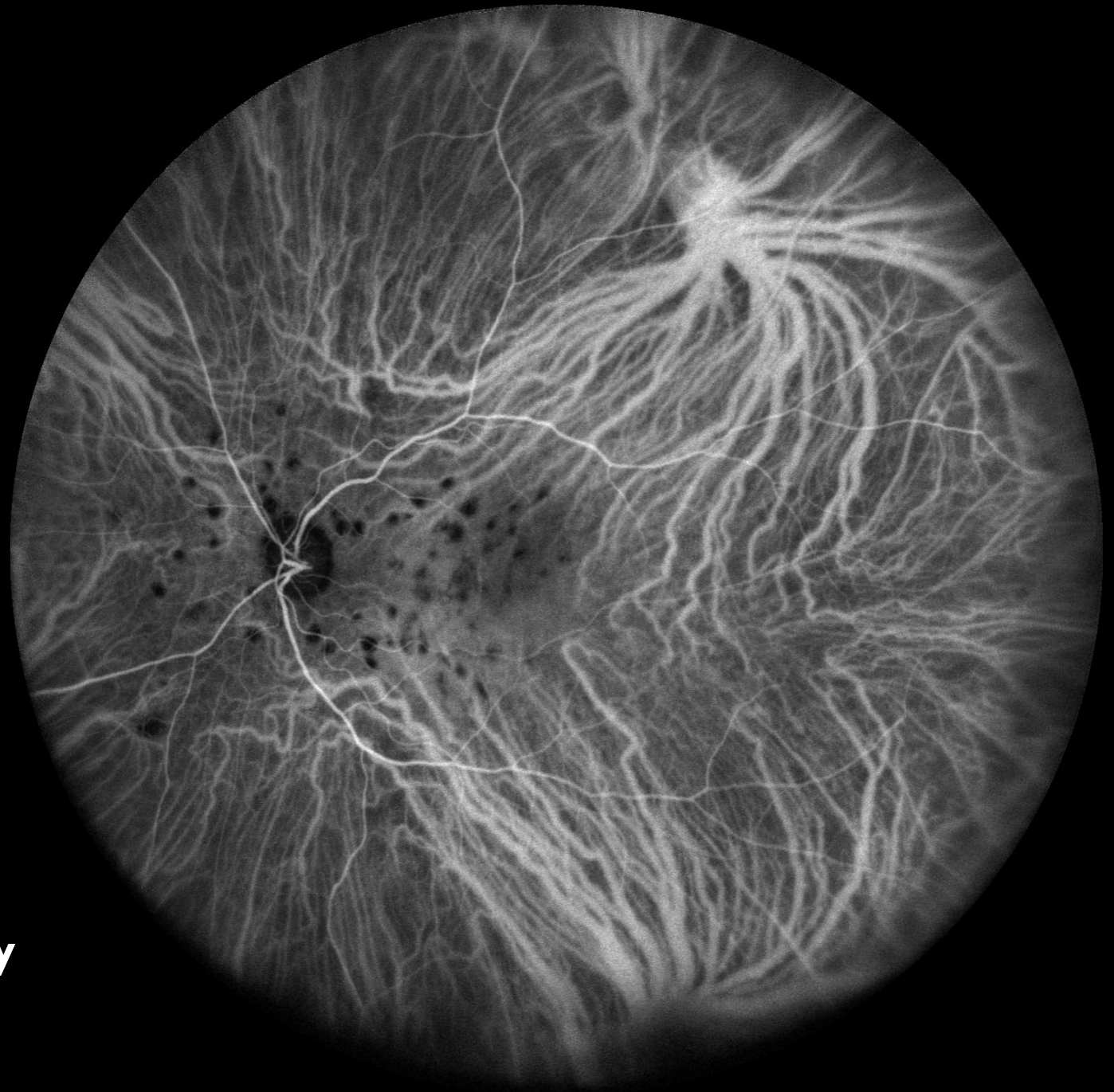
MIYAKE VIEW



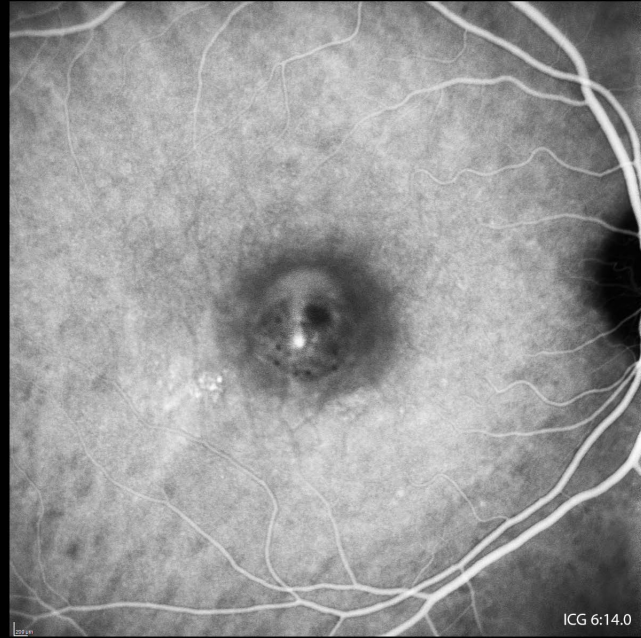
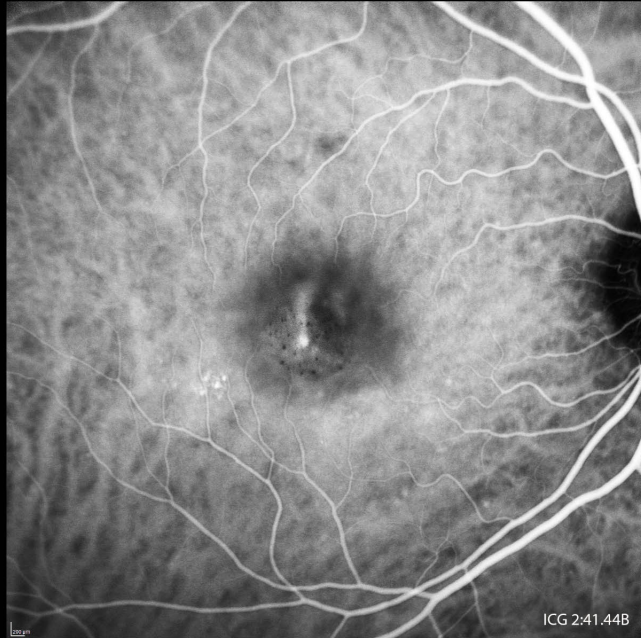
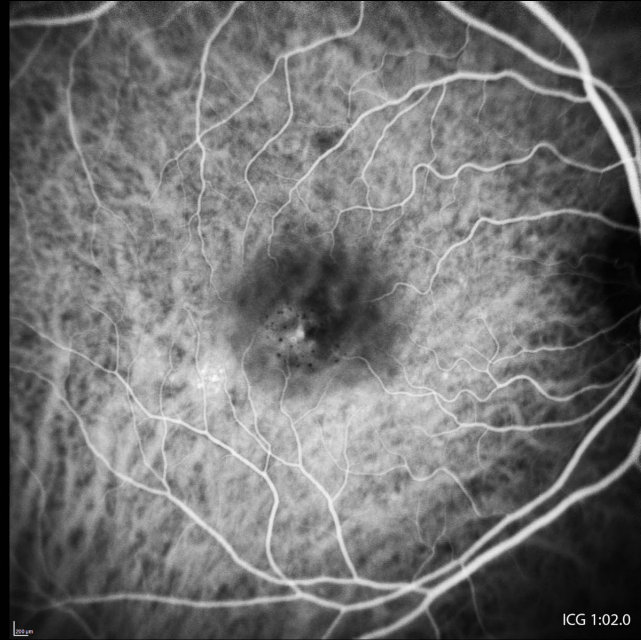
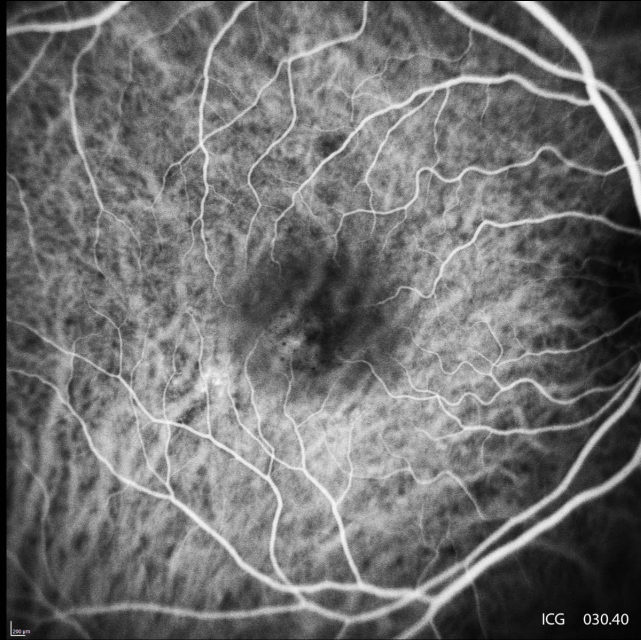Miyake-Apple view
Kumar Doctor, MD
Shivani Pattnaik, MS

The background features a dark teal and blue color palette. It contains a central circular pattern of small, glowing dots in various shades of teal, blue, and yellow, creating a bokeh effect. The overall aesthetic is modern and scientific.

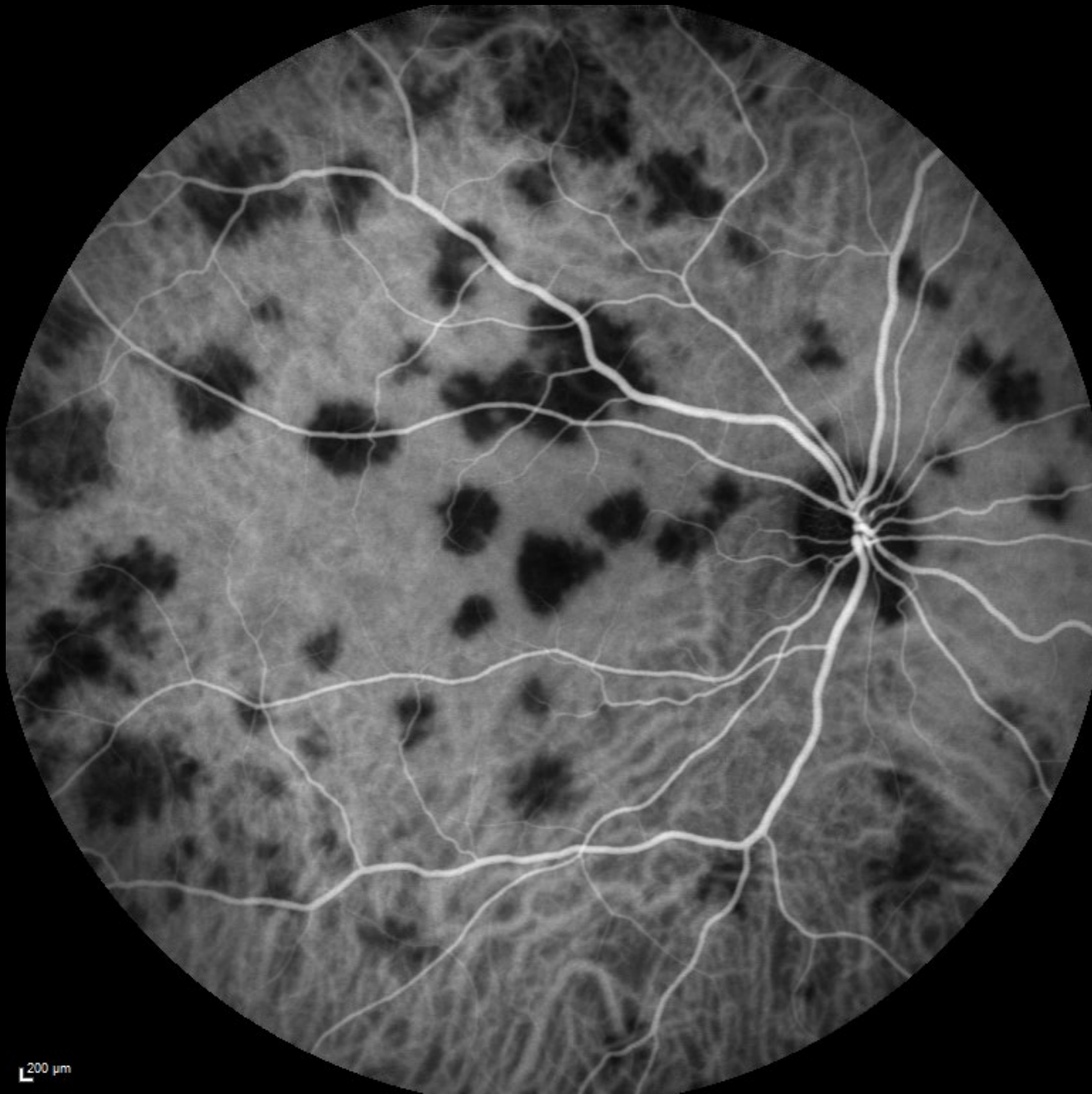
ICG Angiography



Punctate Inner Choroidopathy
Jessica Stephens, BA

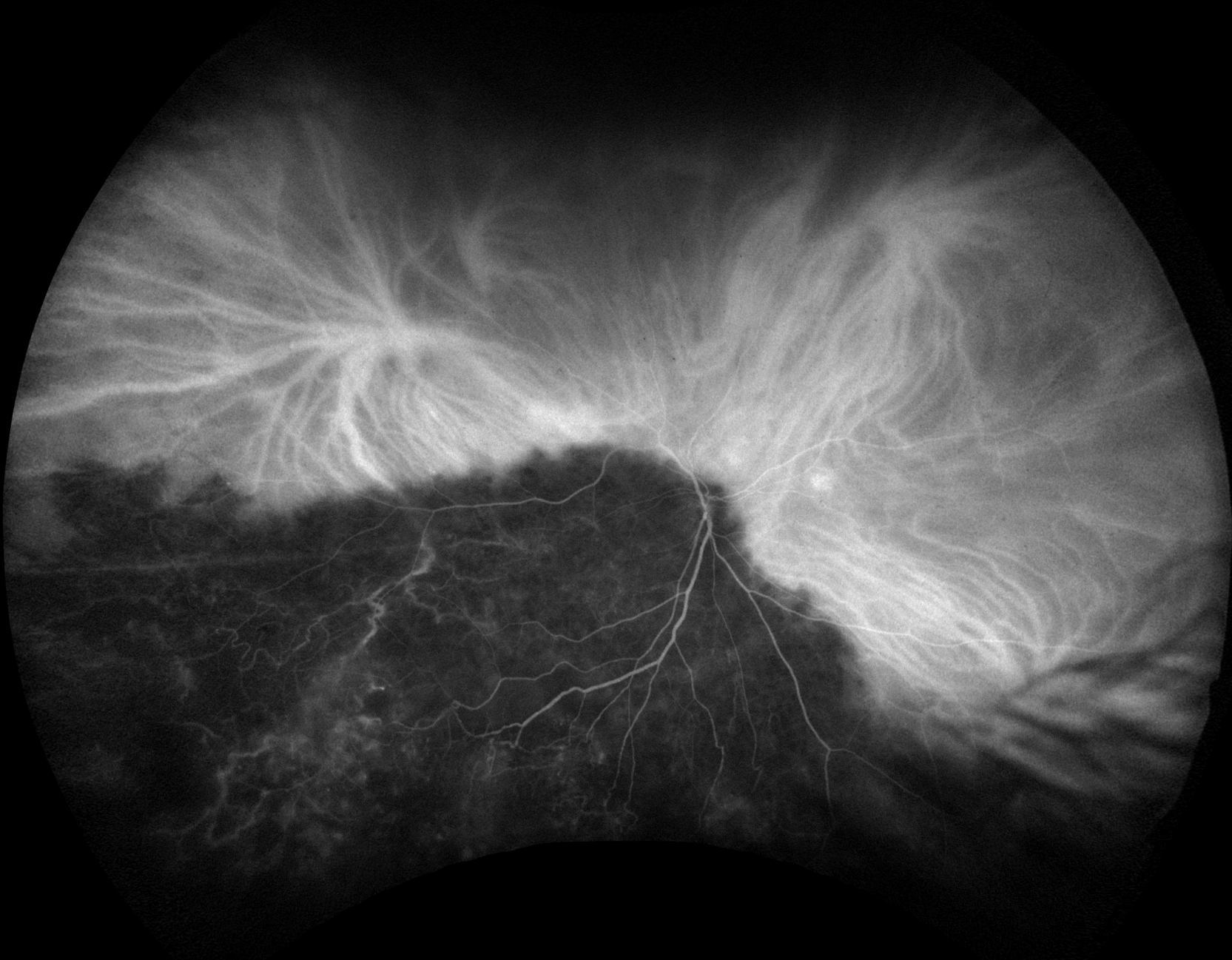

Smoke Stack
Brian Lutman, CRA



Number 3


Sarah Schmid-Ainsworth, BSc



Posterior Uveitis
Christopher Keth, BA, CRA

The background of the image is a dark, teal-toned photograph of a camera lens. The lens elements are visible, creating a bokeh effect with out-of-focus light spots in shades of blue, green, and yellow. The overall aesthetic is technical and artistic.

Instrumentation Photography



Honorable
Mention

LASIK / Contact Lens

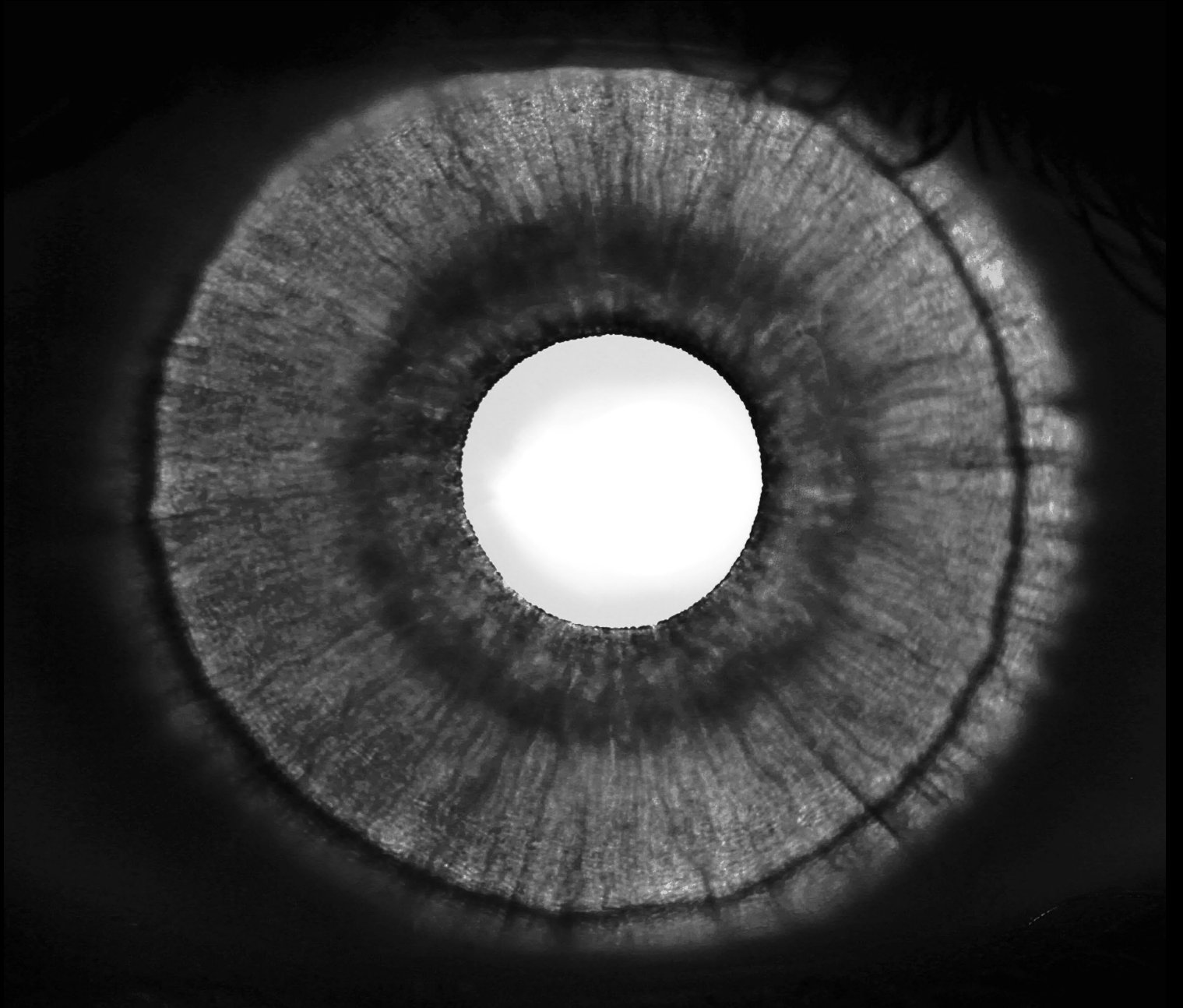
David Miller, BSc, CRA

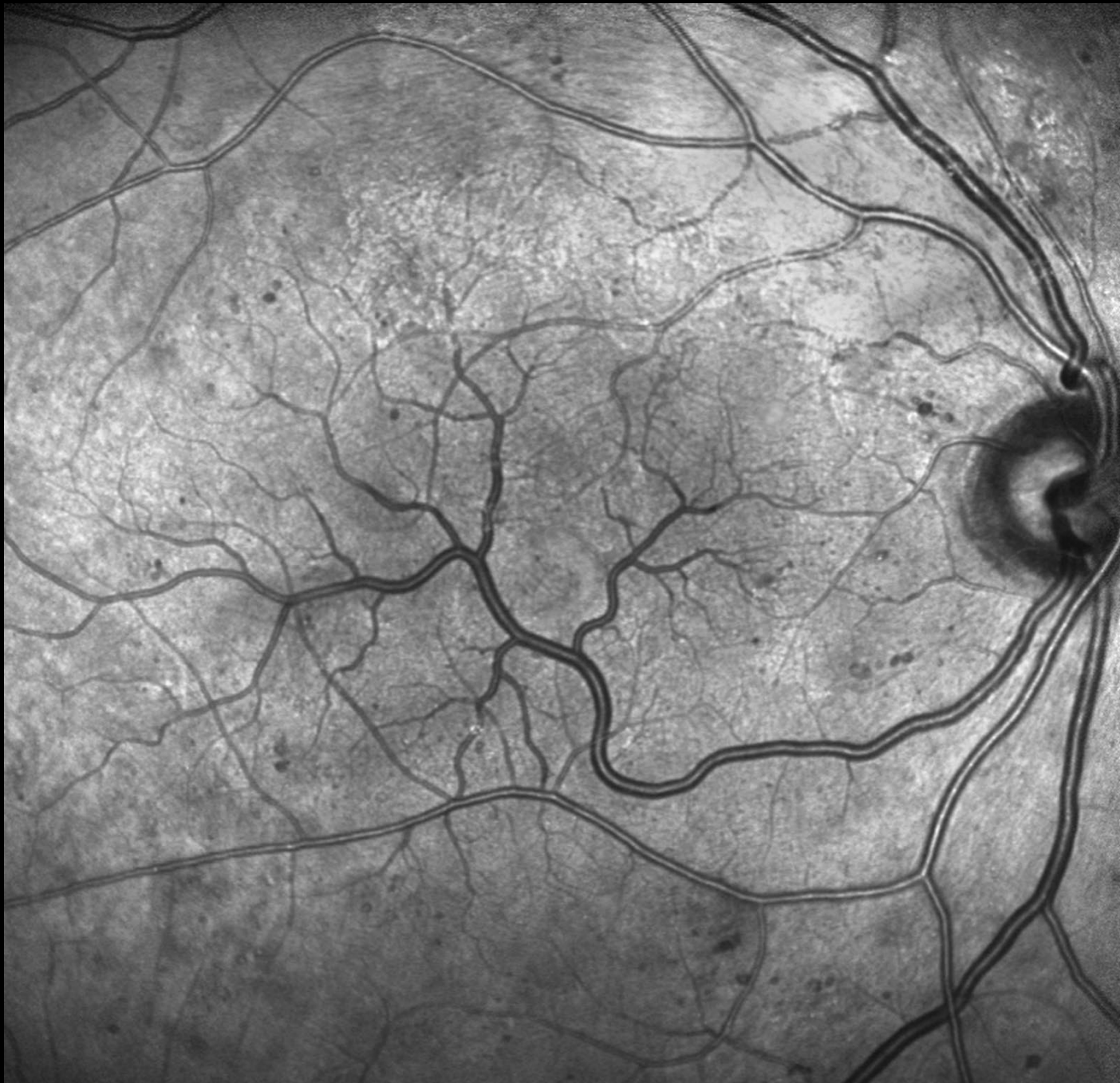


Monochromatic Photography

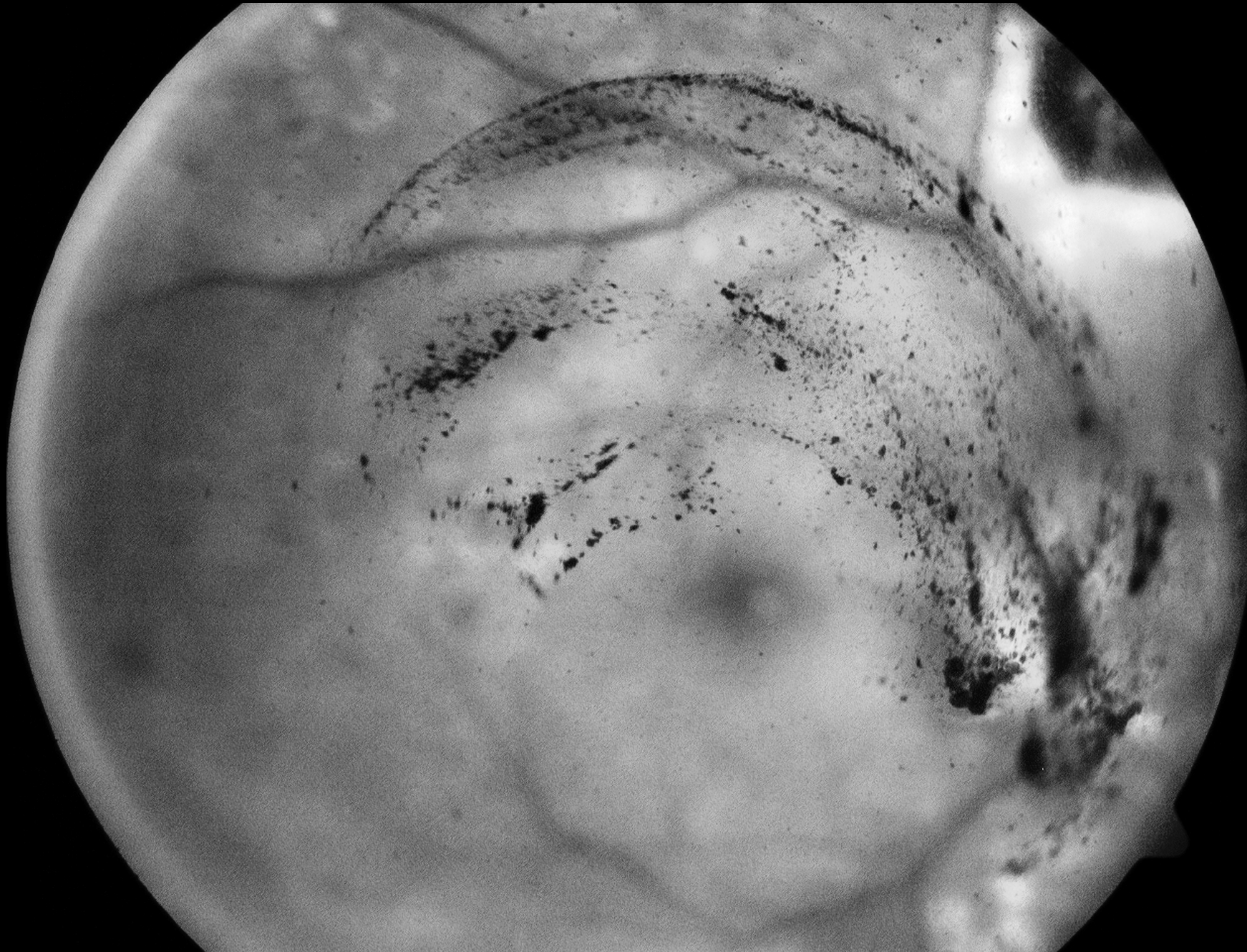

**Oculocutaneous Albinism w/
Iris Transillumination**
Nicole Mantel

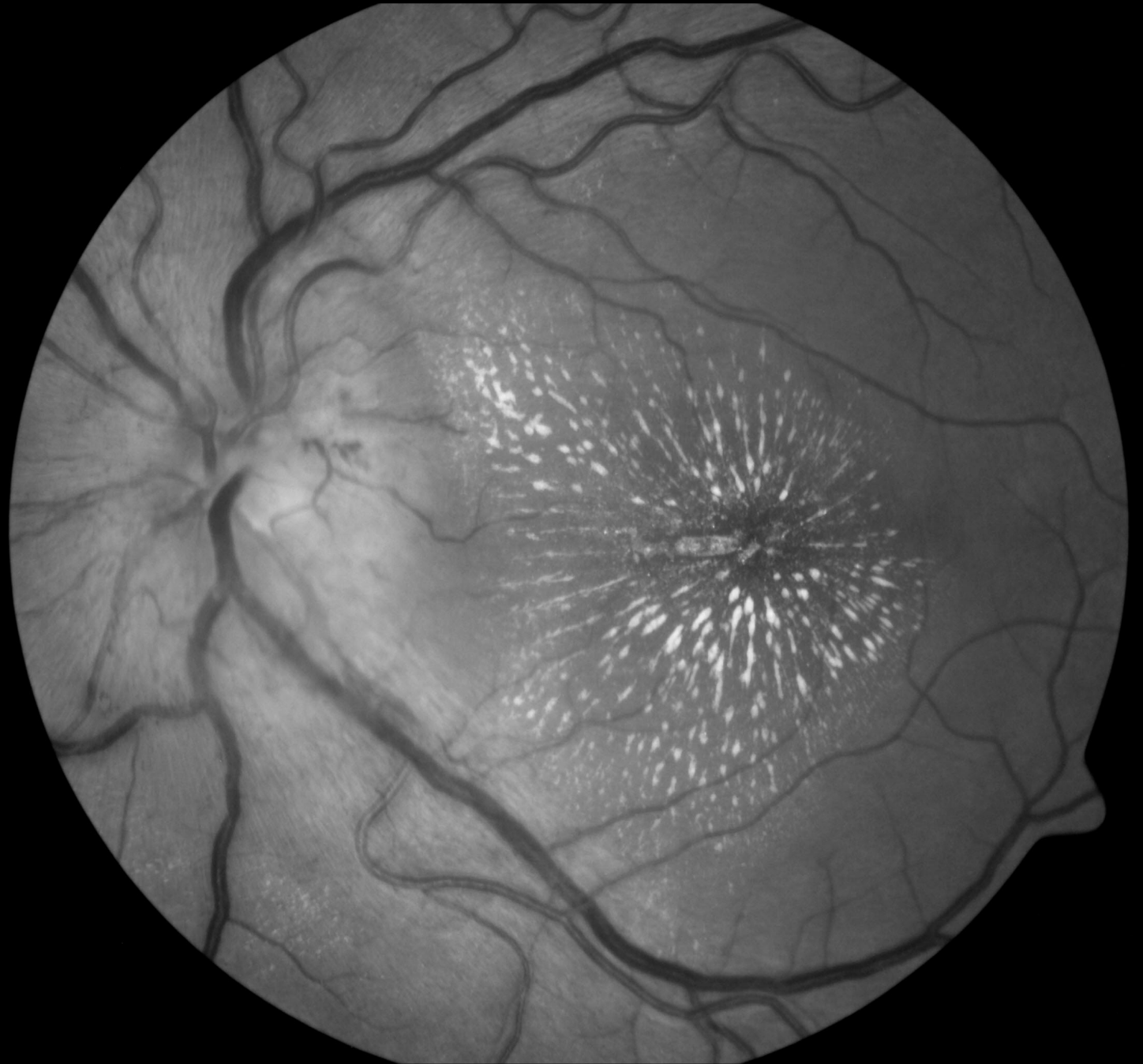




Congenital Retinal Macrovessel
Bridgette Barnes



Vitreous hemorrhage
John Leo, BSc

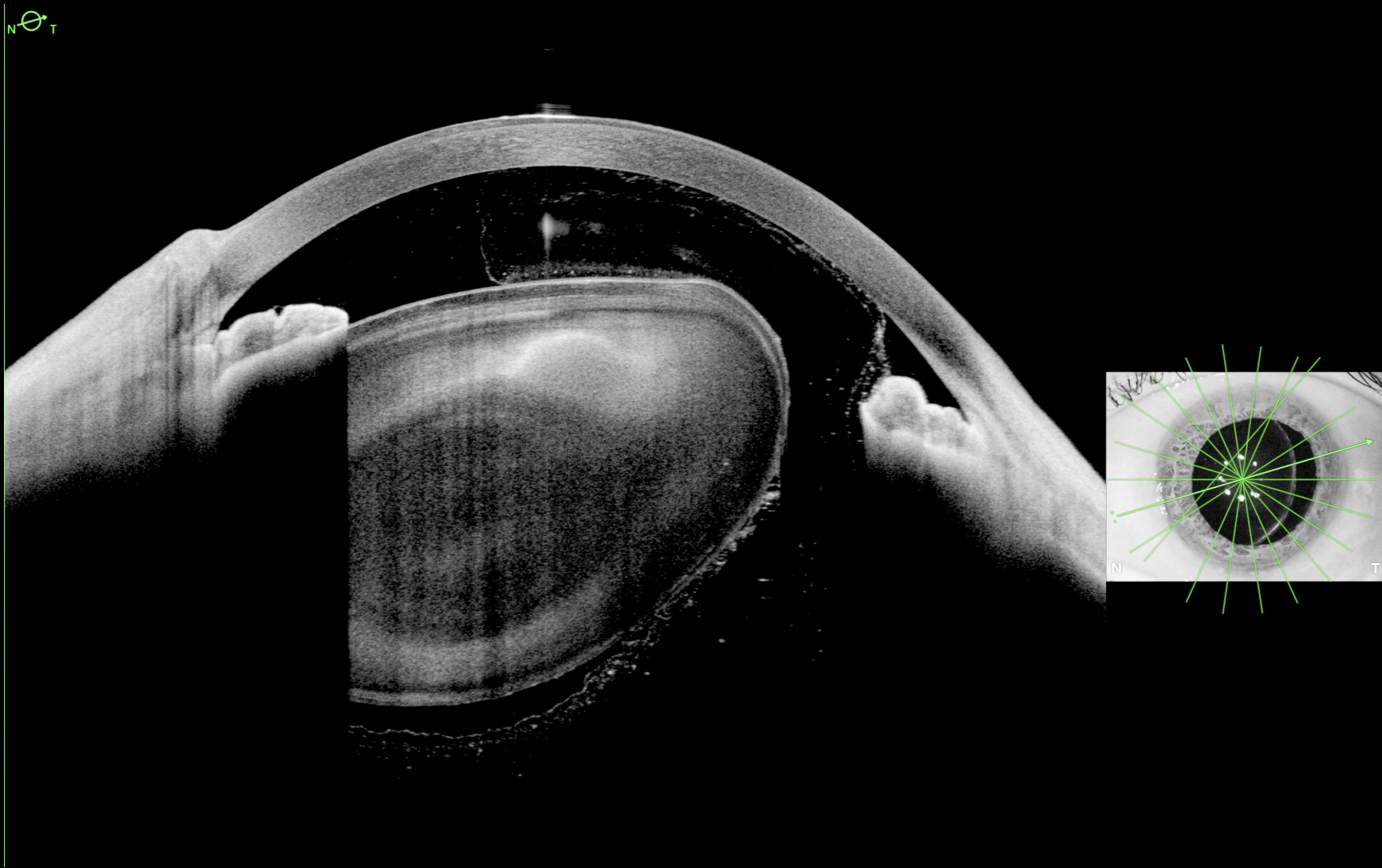


Honorable
Mention

Macular Star
Karla Woods, COA

The background of the slide is a blurred, circular cross-section of a human eye, showing the internal structures of the retina. The image is rendered in a monochromatic teal and blue color scheme, with some internal structures appearing as bright, multi-colored spots. The overall effect is a technical, scientific visualization of the eye's internal anatomy.

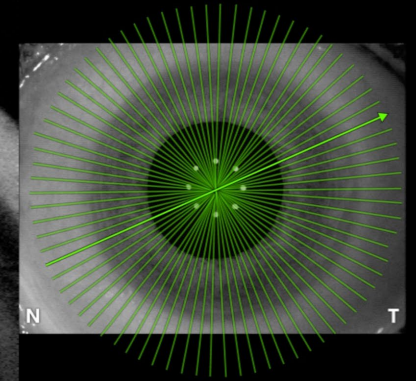

Optical Coherence Tomography



Subluxated lens w/ Vitreous in Anterior Chamber

Kumar Doctor, MD

Shivani Pattnaik, MS



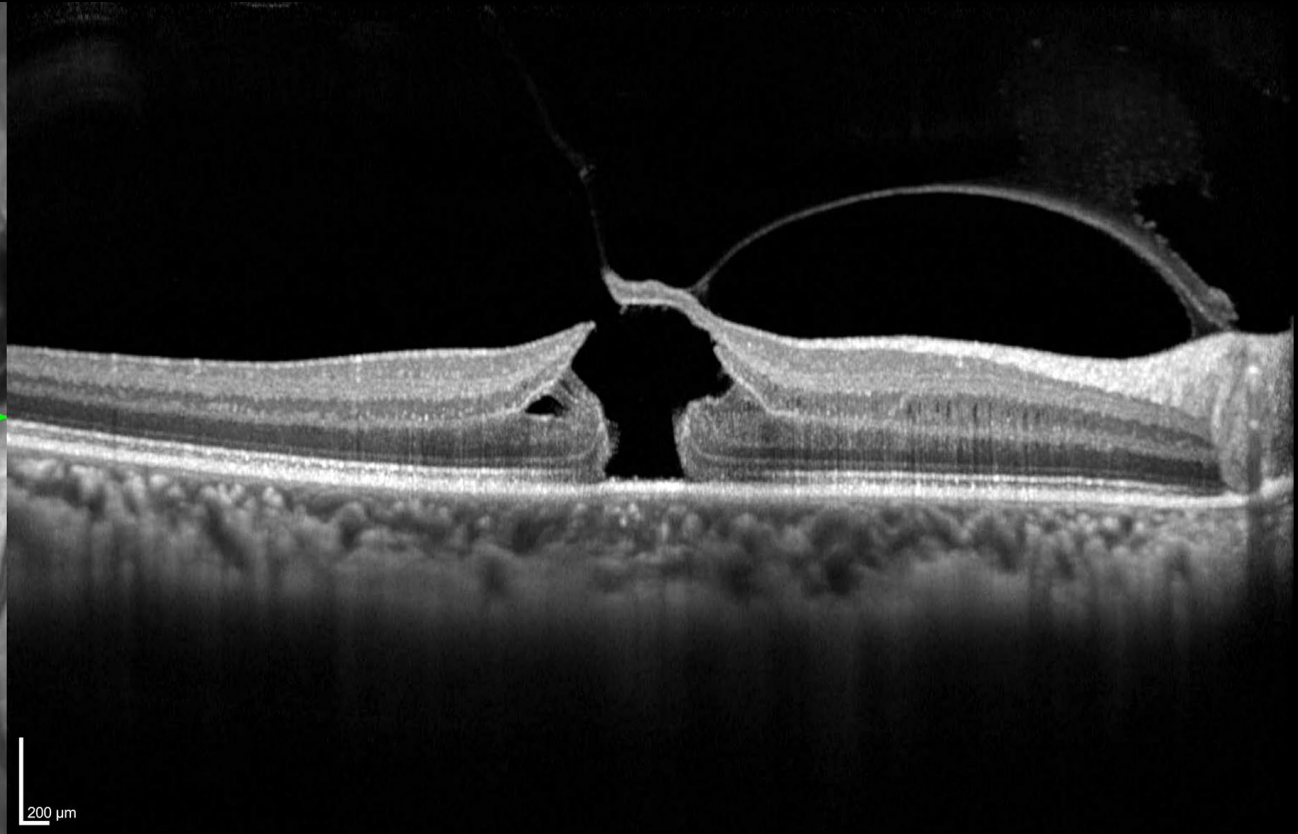
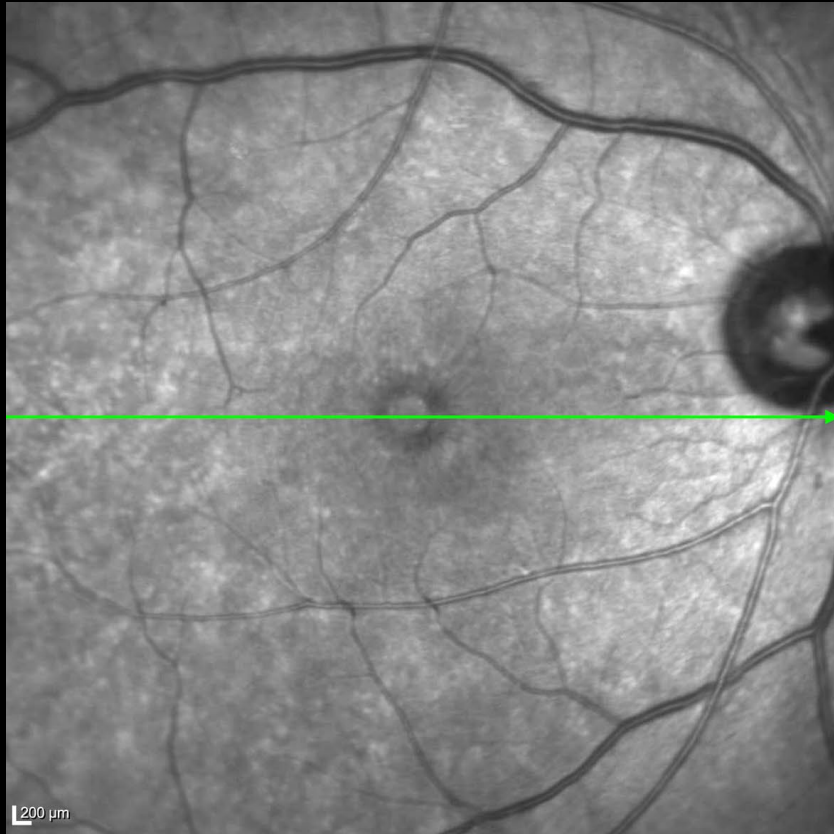
**Vogt Koyanagi Harada Syndrome - Anterior Segment Manifestation w/
Anterior Ciliary Body Dislocation & Angle Closure Acute Glaucoma**

Luca Gualdi, MD, COA



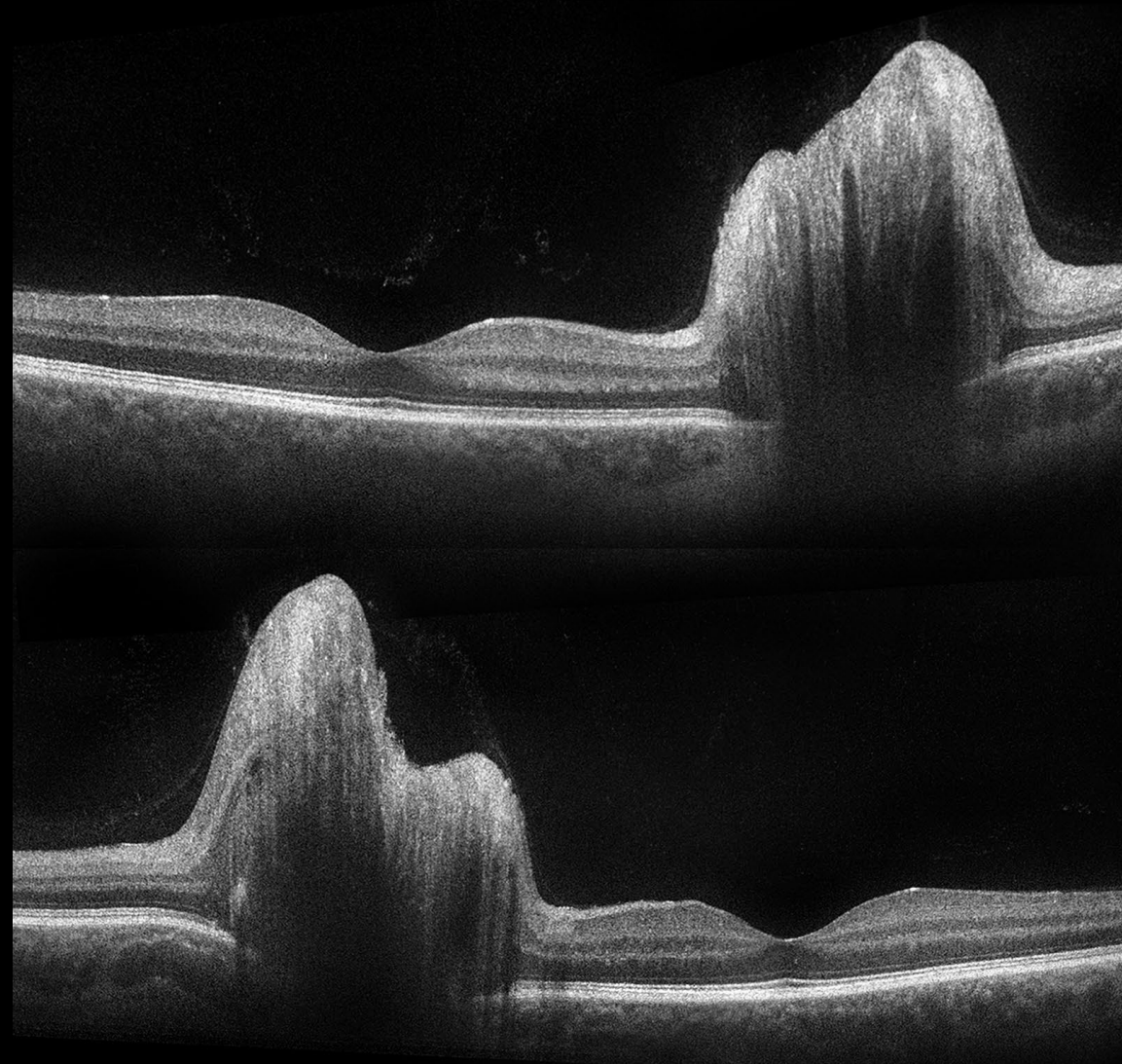
Macular Hole with Operculum

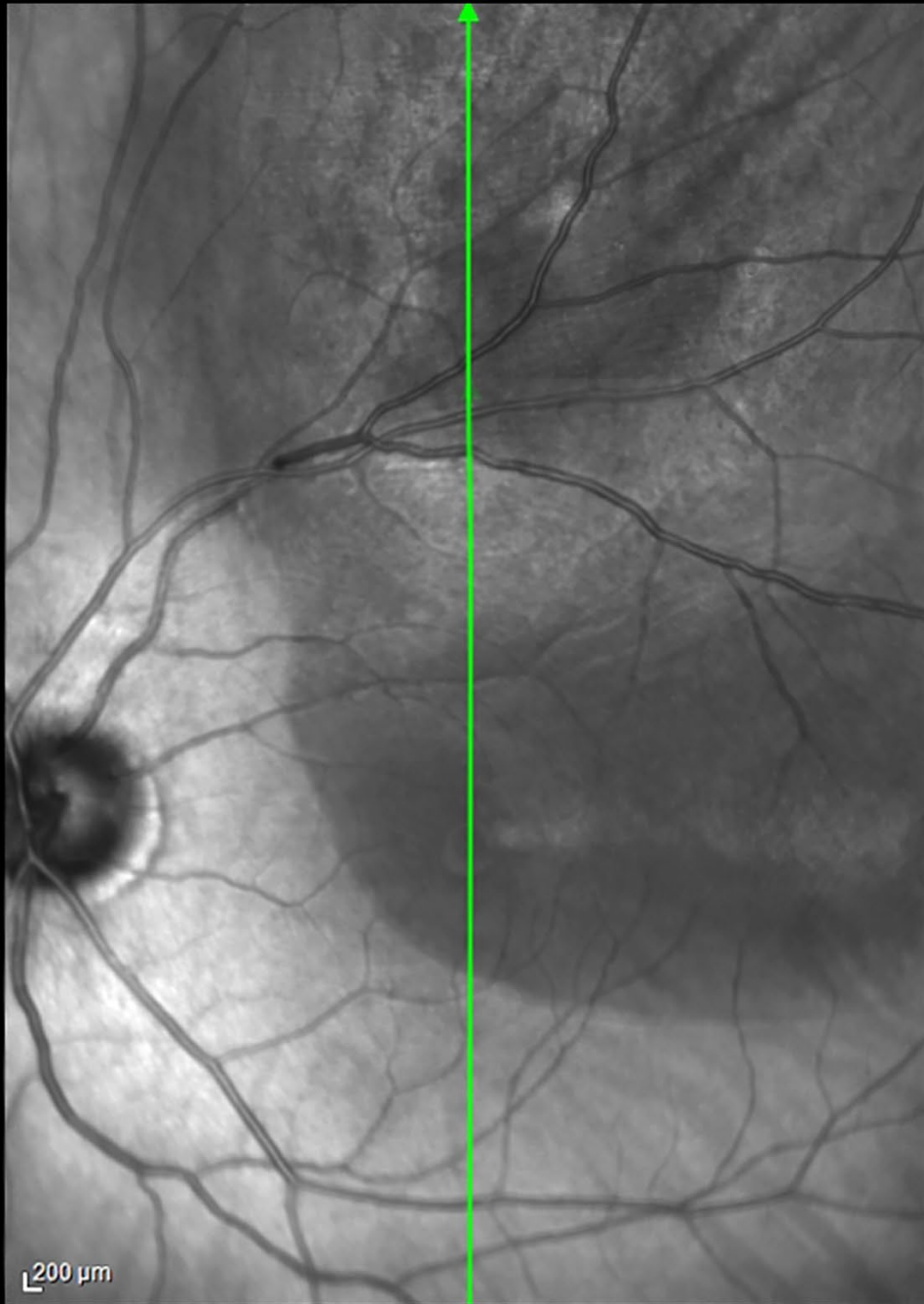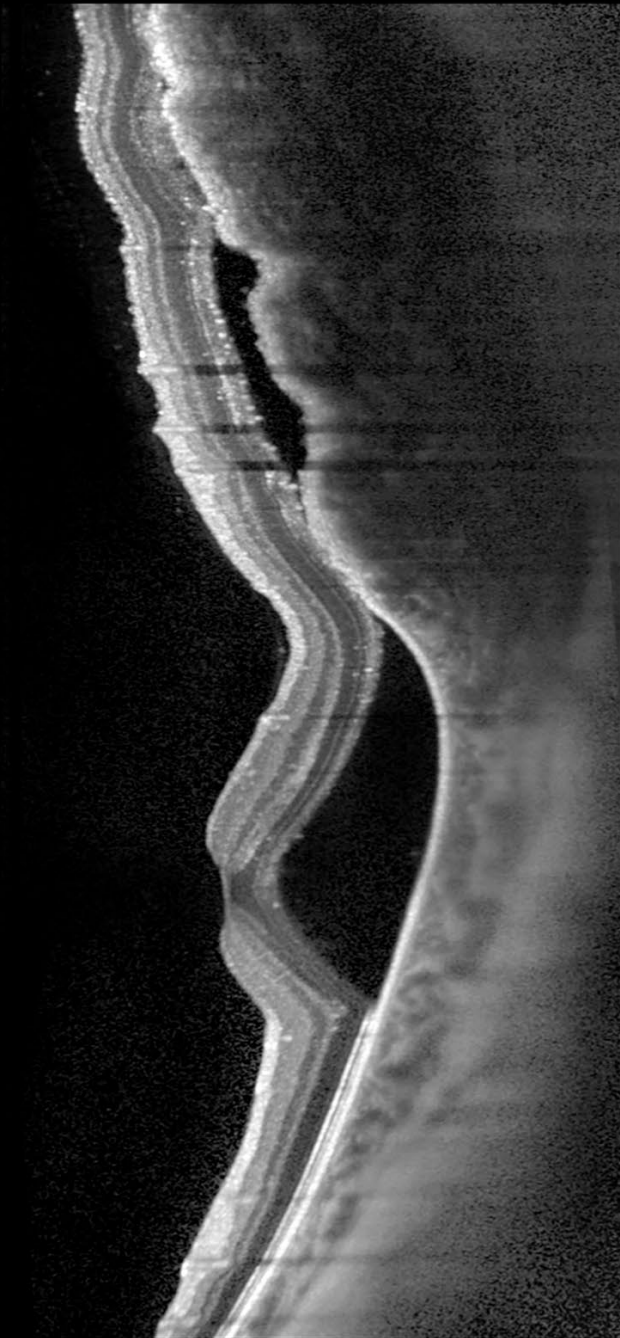
Bradley Stern, BA, CRA





Idiopathic Intracranial Hypertension
Sean Grout, OCT-C

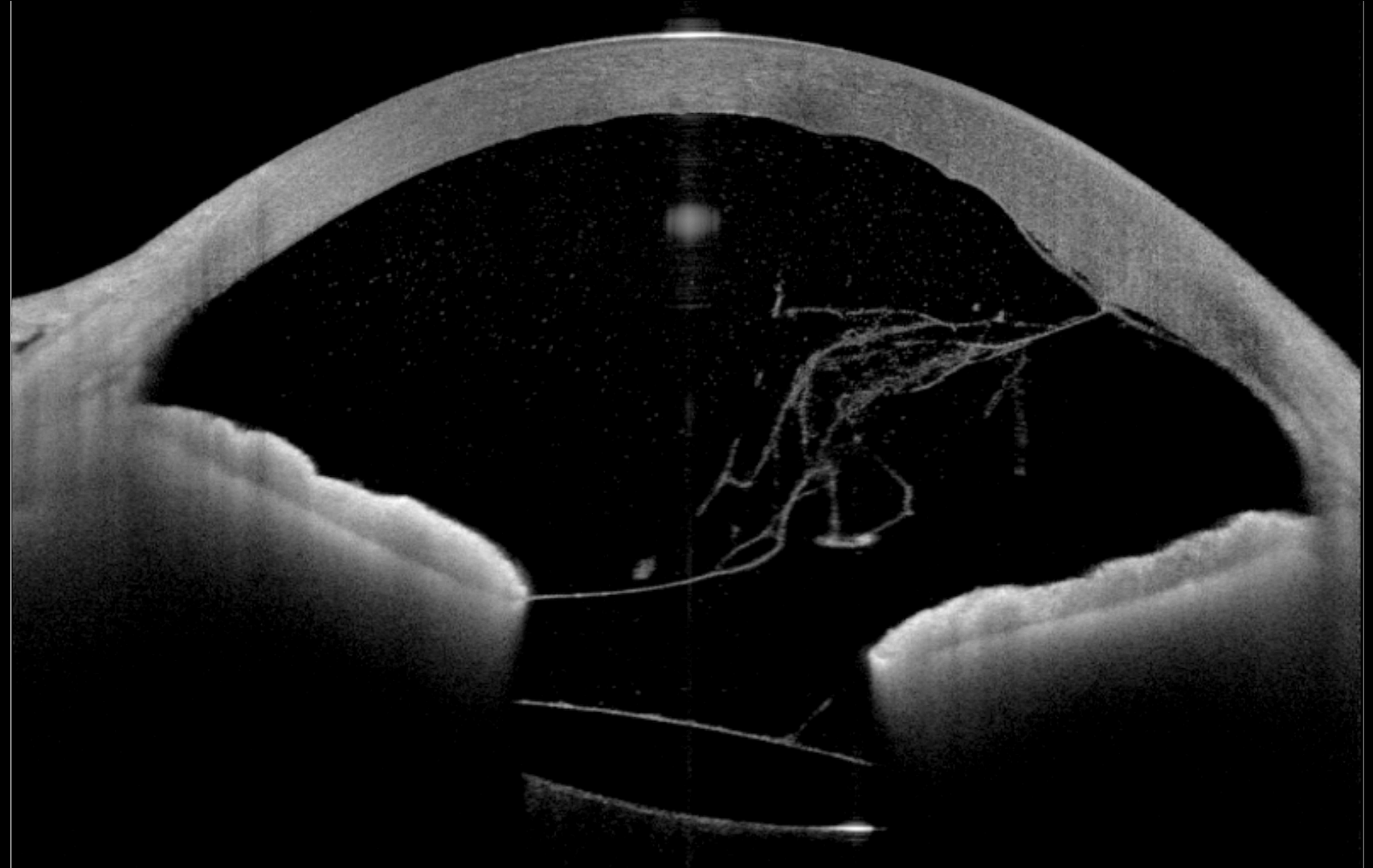


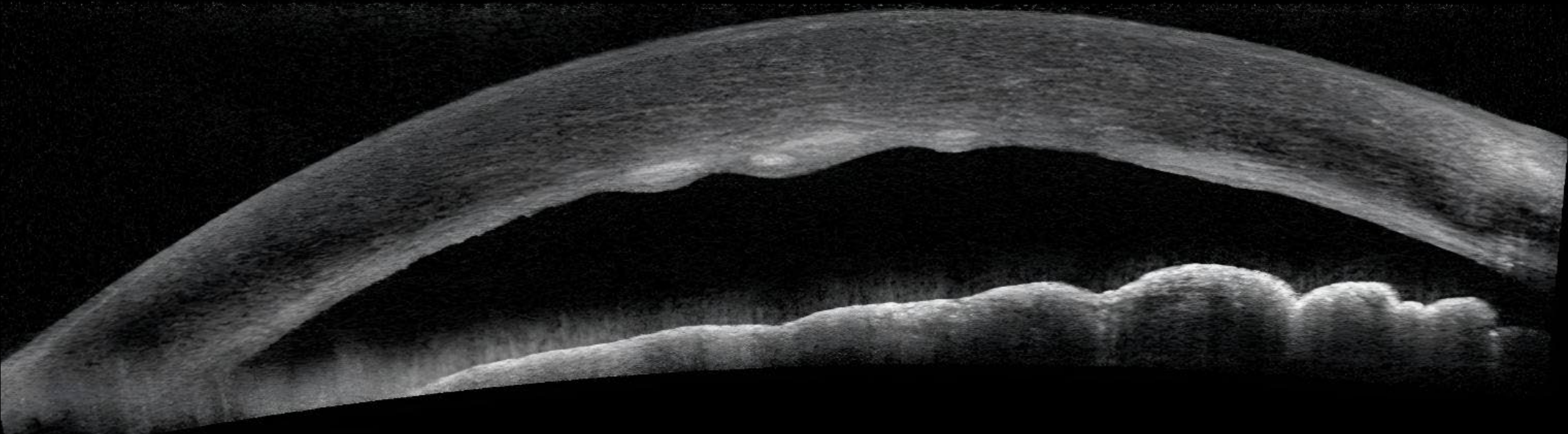


Choroidal Metastasis
Sean Grout, OCT-C



**Fibrin membrane - the
Frequent Complication**
Prasanna Ramesh, MS, DNB
Shruthy Ramesh, DNB, MS





Corneal Endothelial Dystrophy

Anugraha Balamurugan, MS

Prasanna Ramesh, MS, DNB

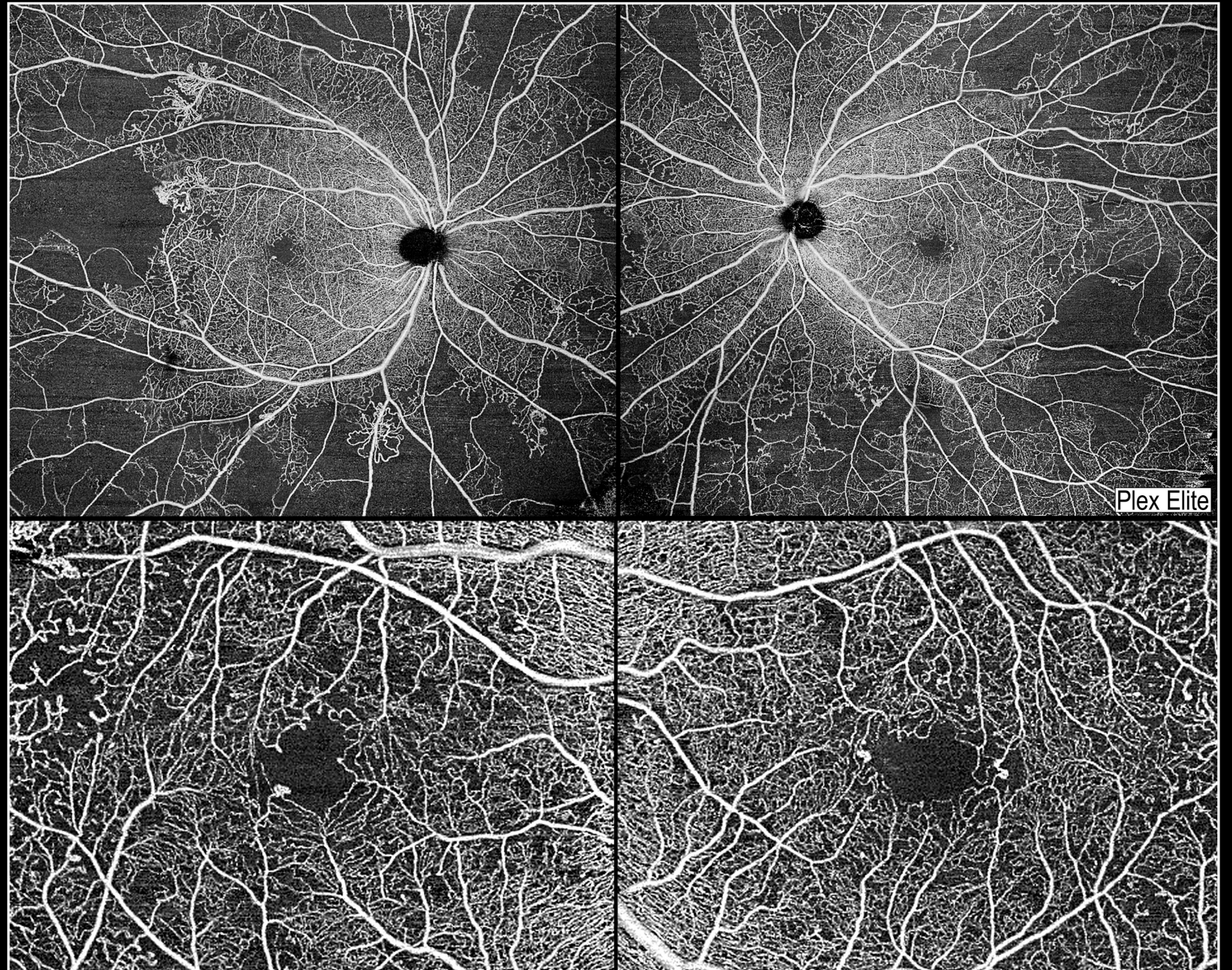




Optical Coherence Tomography Angiography

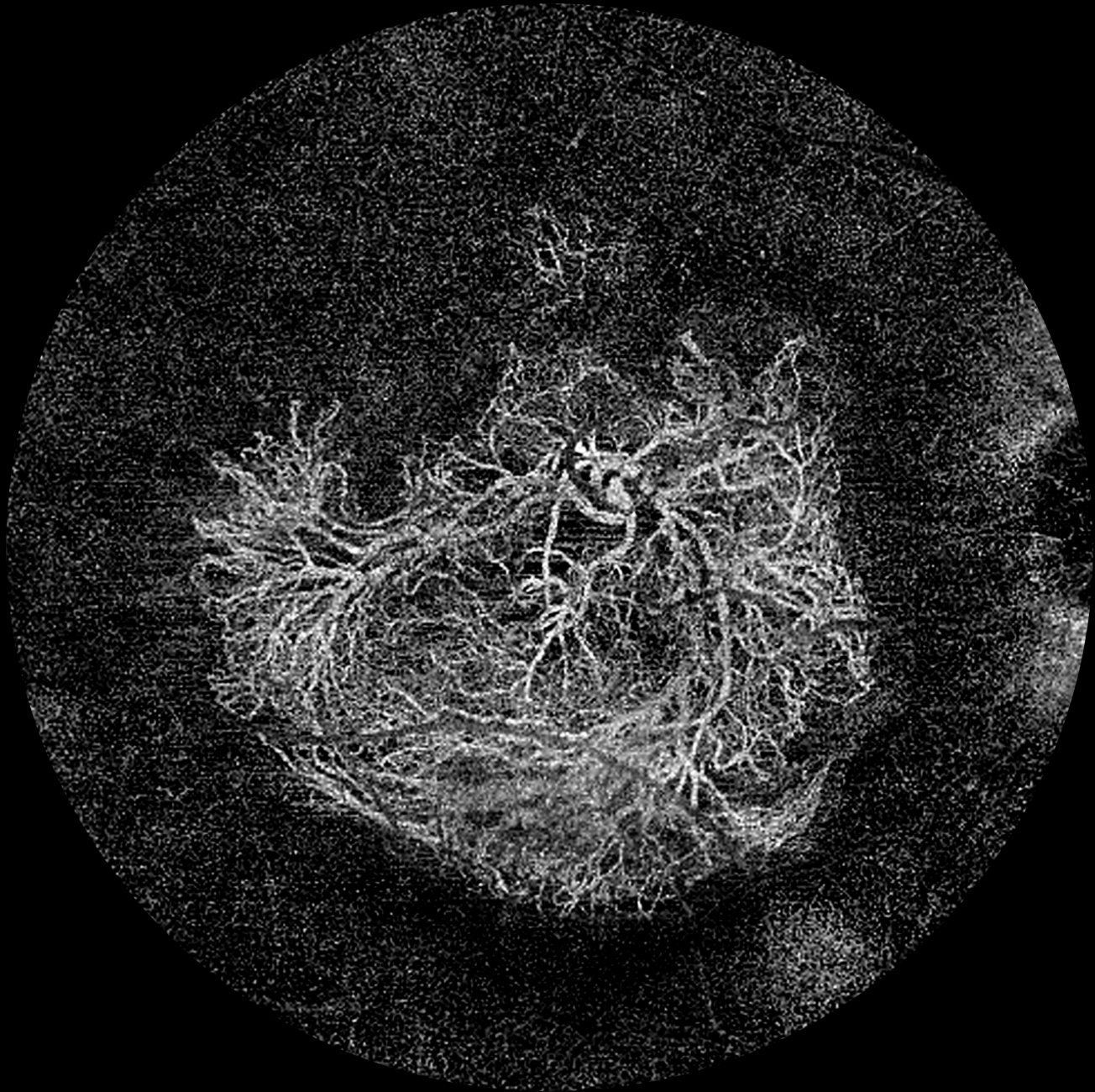


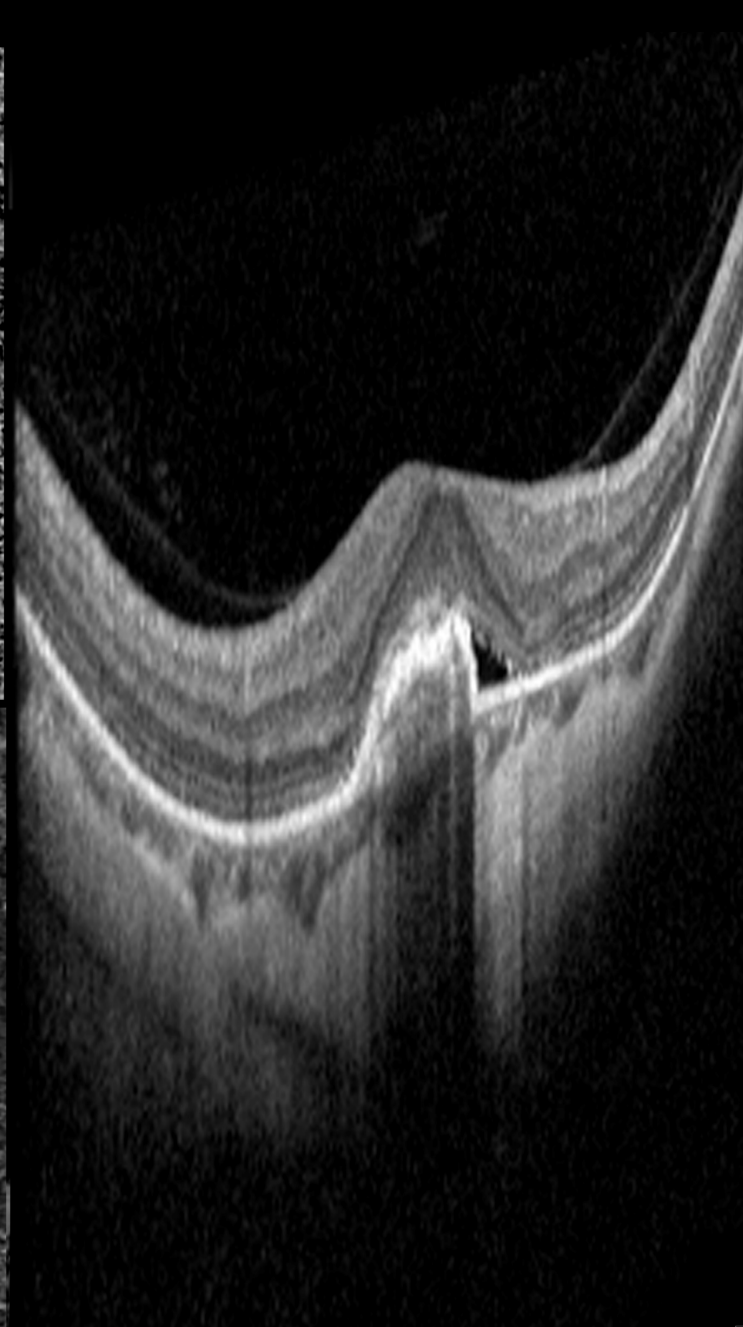
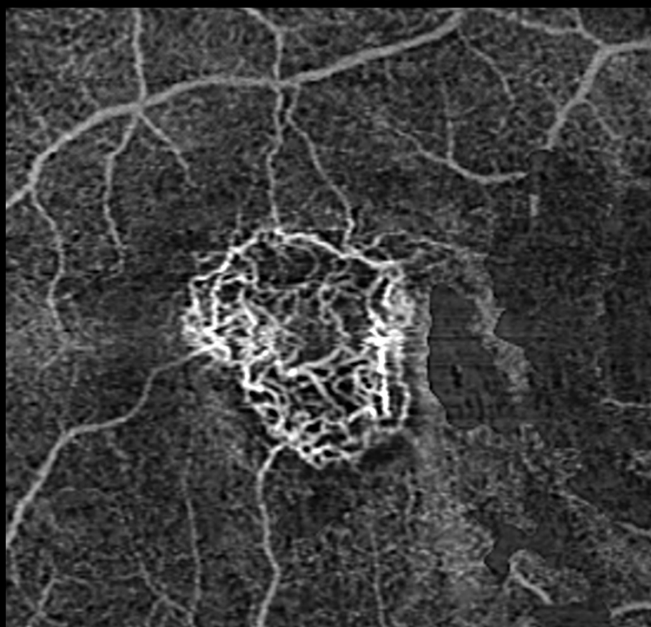
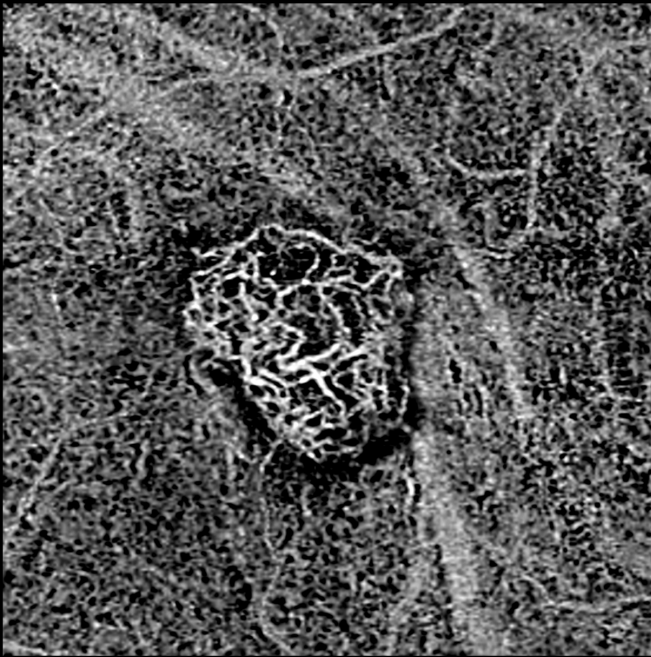
**Diabetic Retinopathy
w/ Neovascularization**
Kasi Sandhanam





Choroidal Neovascularization
Kasi Sandhanam





**Myopic Choroidal
Neovascularization**
Kasi Sandhanam

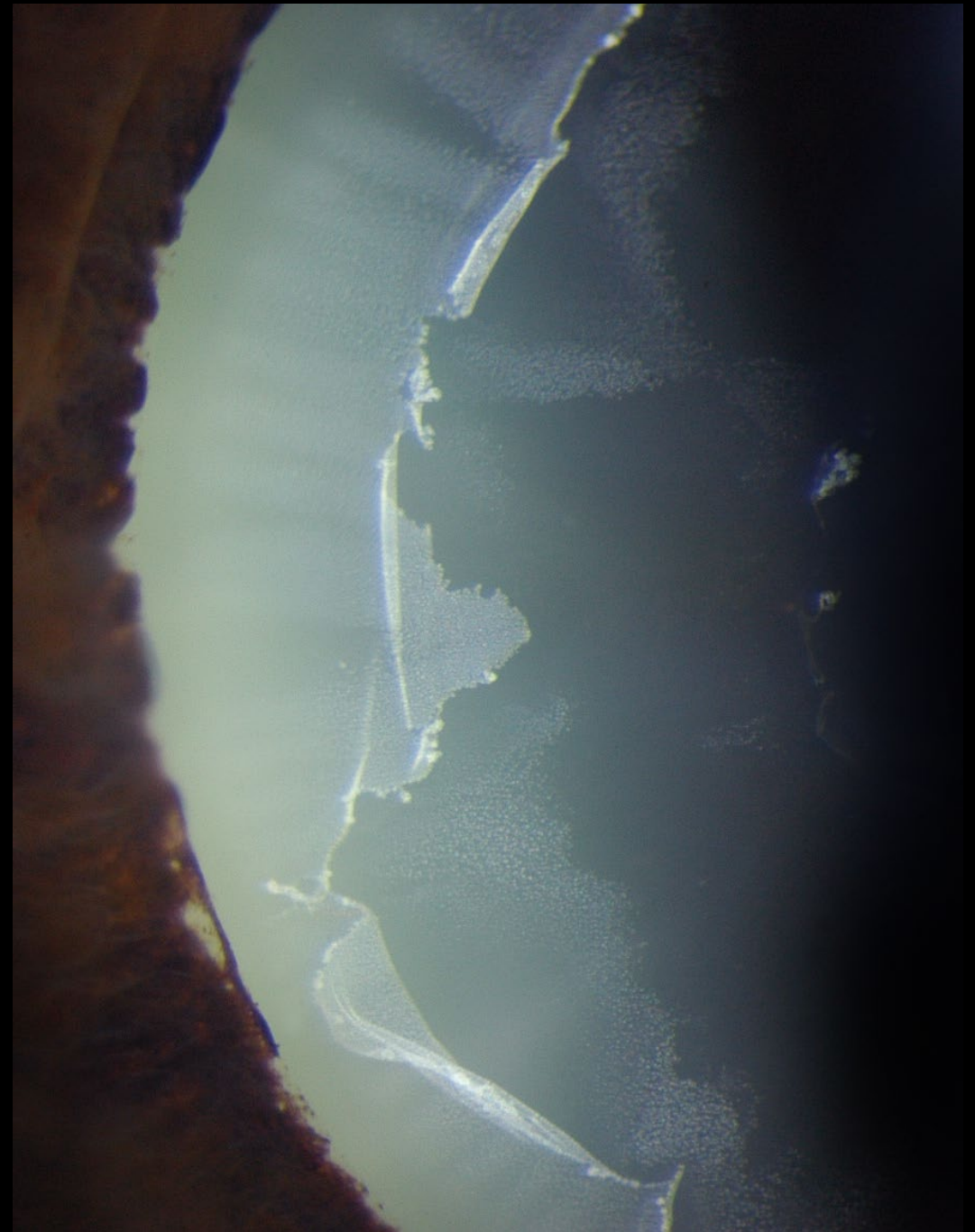


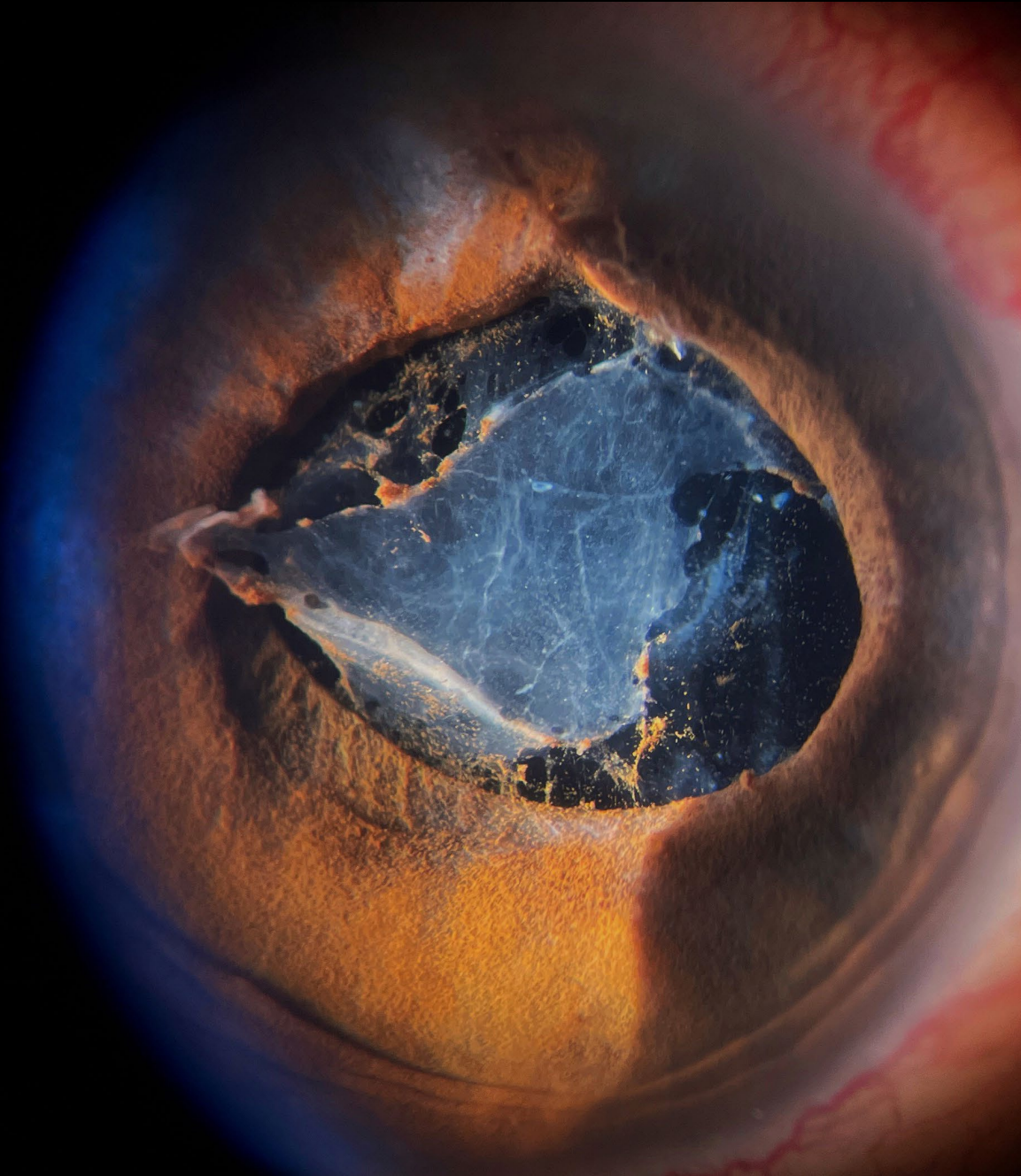
Slitlamp Photography



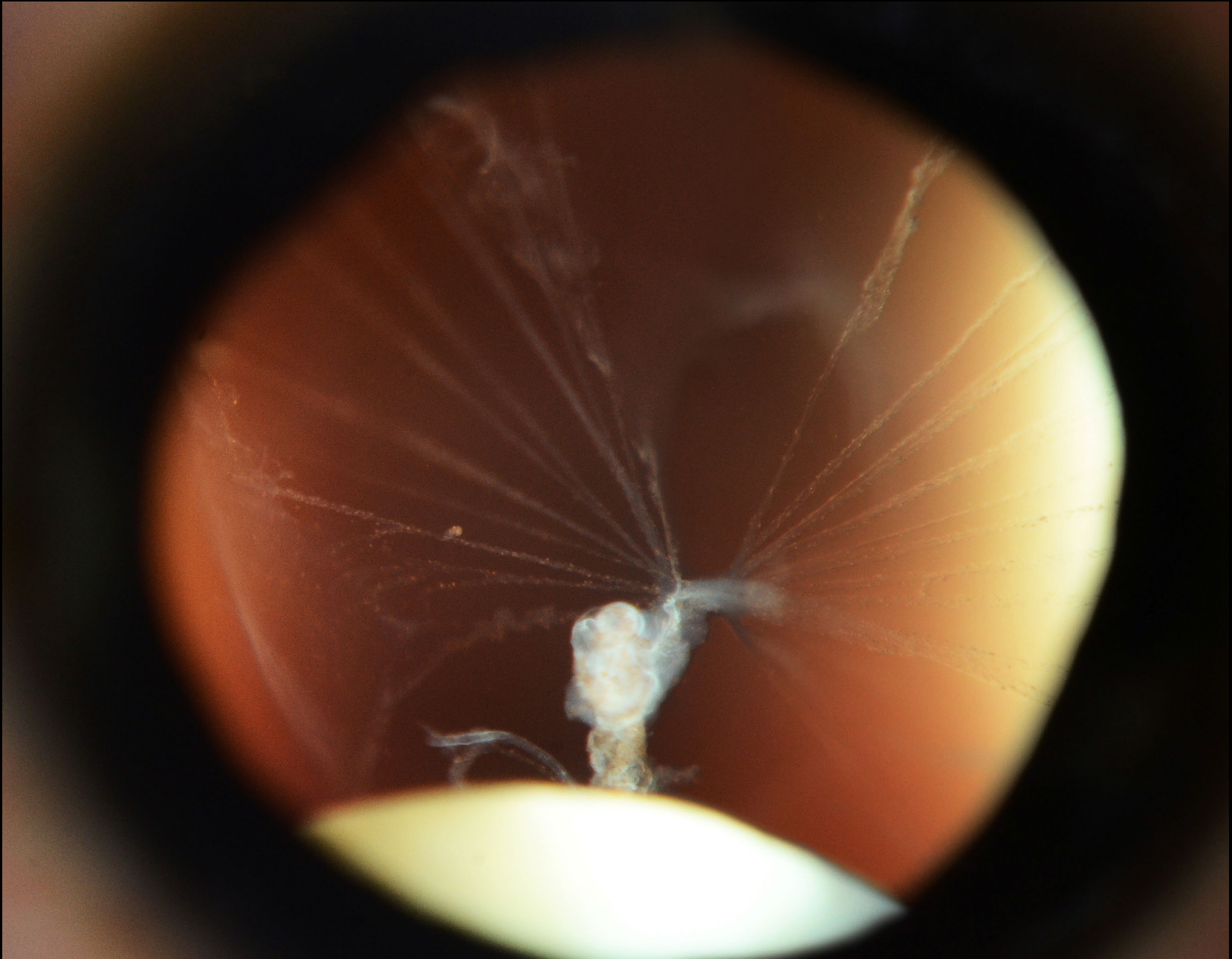Pseudoexfoliation of Lens Capsule

Gary Miller CRA, OCT-C





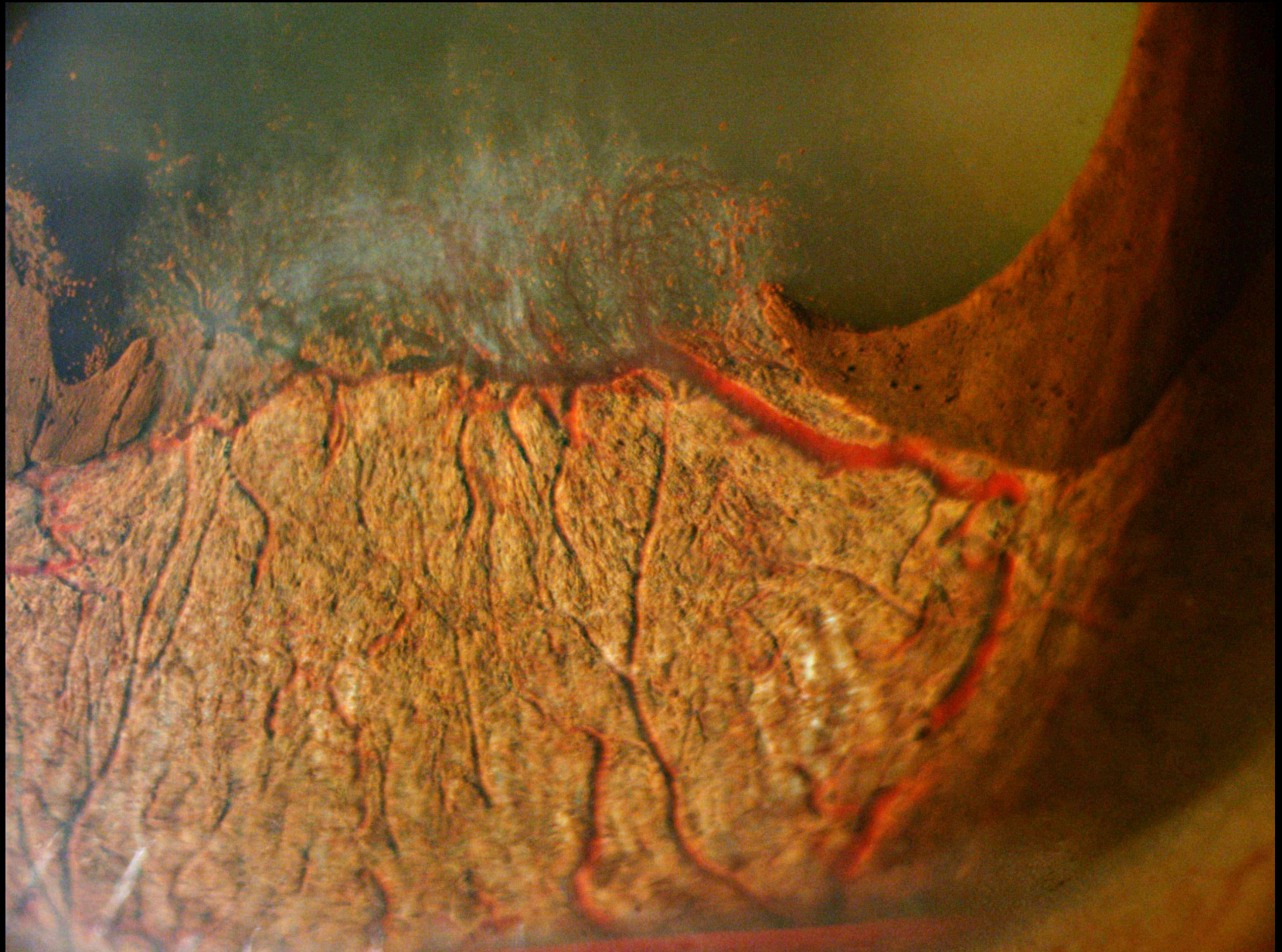
**Inflammatory Pupillary Membrane
in Patient with Endophthalmitis**
Kingston Rodolfo Ureña-Wong



Dislocated Lens
Kasi Sandhanam



Neovascularization of Iris
John Leo





Ciliary Body Melanoma
Noelle Pensec Rovensky
CRA

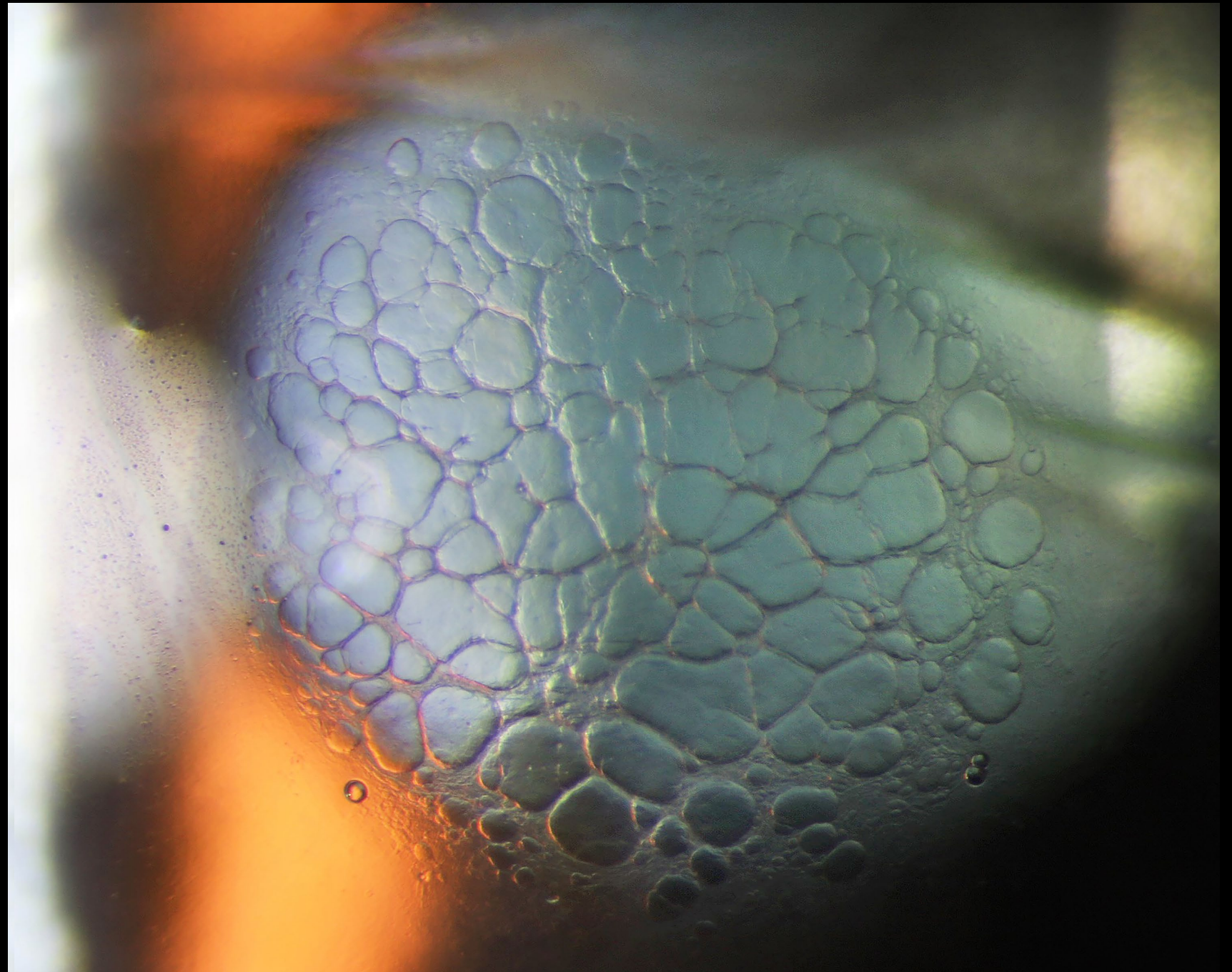


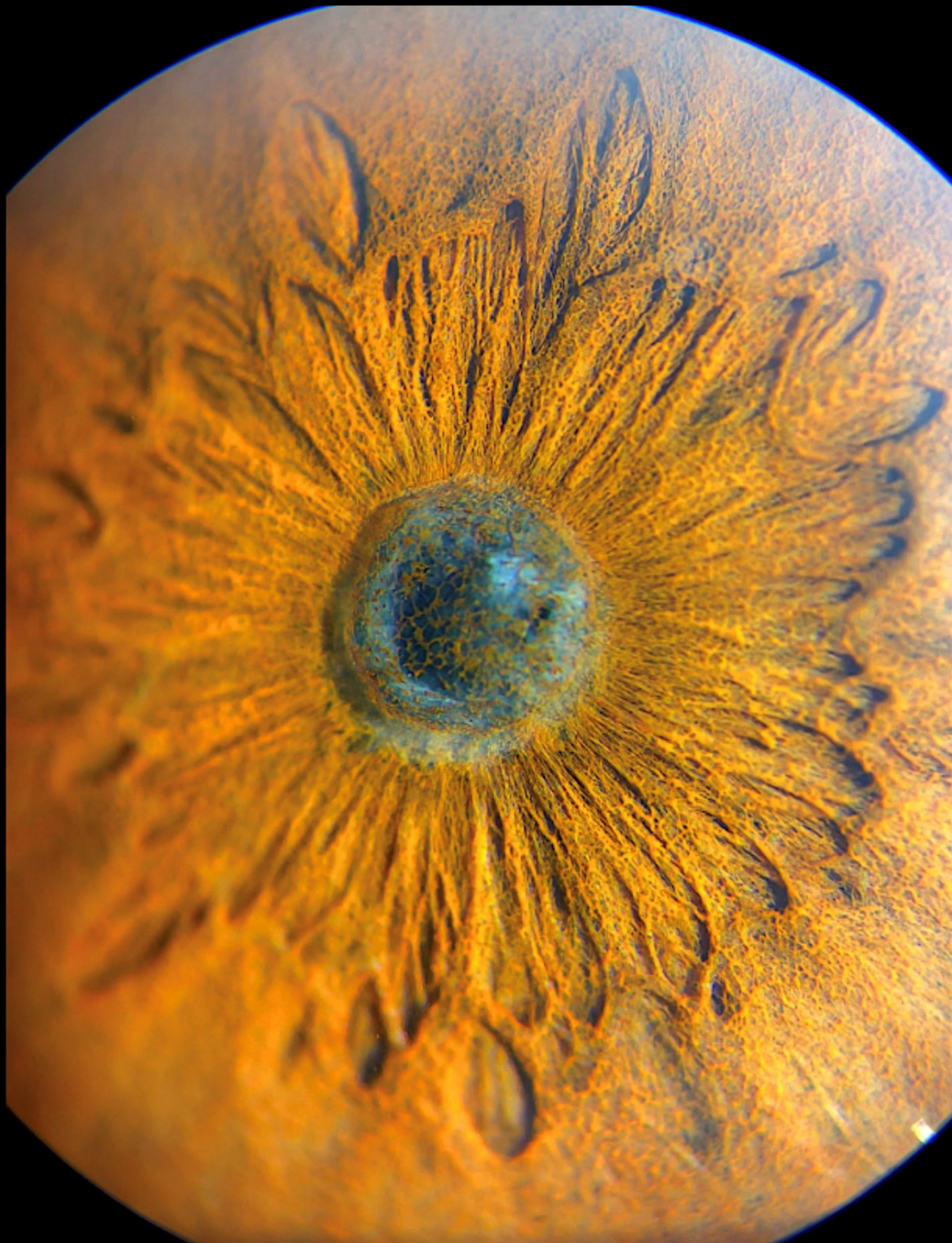Pseudoexfoliation
Jason Calhoun





**Netarsudil-Associated
Honeycomb Edema**
Sean Grout

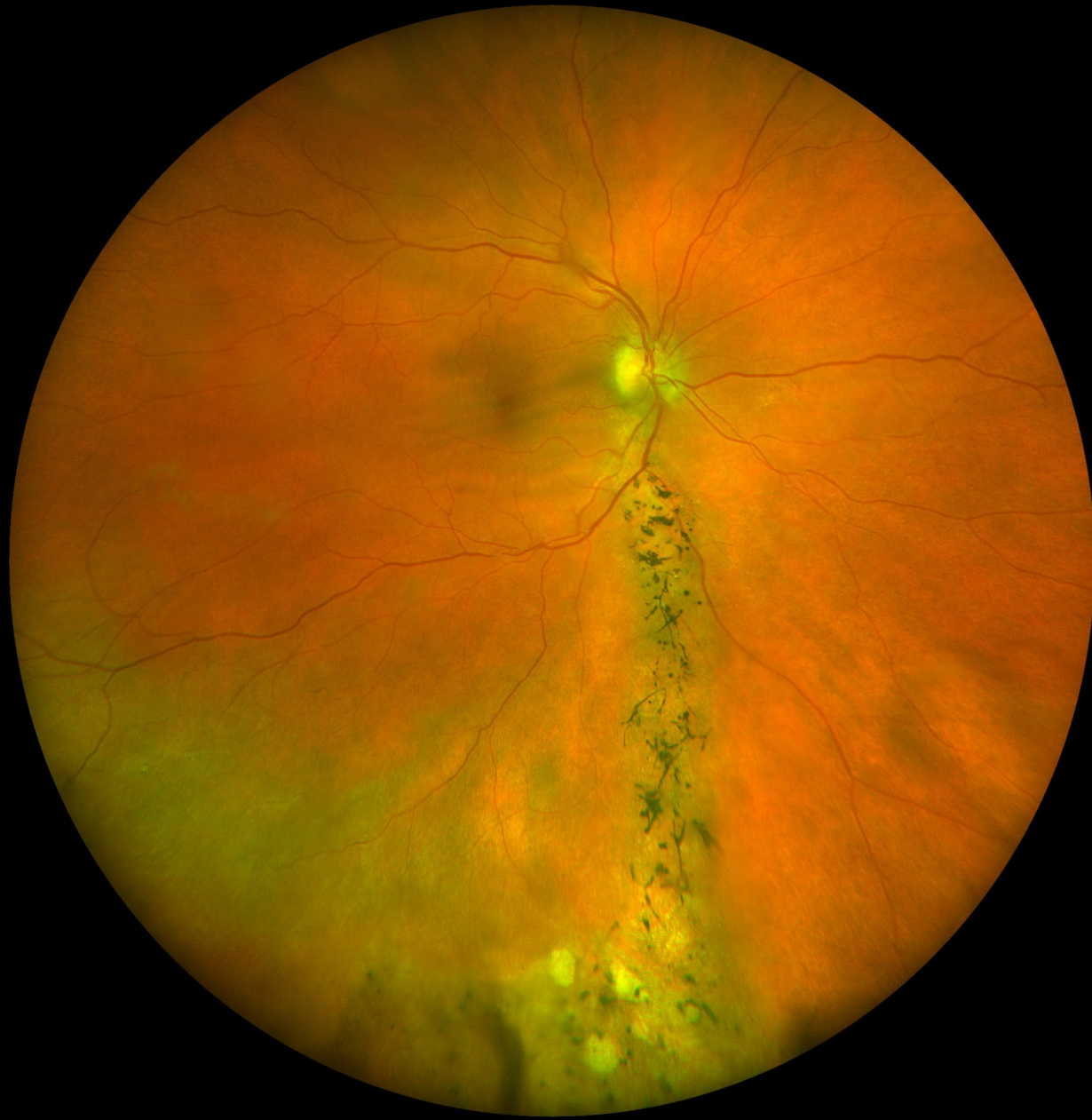



Occlusion Pupillae
Shruthy Vaishali Ramesh

A close-up, artistic view of a camera lens. The lens is the central focus, showing its intricate internal elements and the circular aperture. The background is a soft, out-of-focus bokeh of light spots in shades of blue, green, and yellow, creating a dreamy and ethereal atmosphere. The overall color palette is dominated by cool blues and greens, with warm highlights from the light flares.

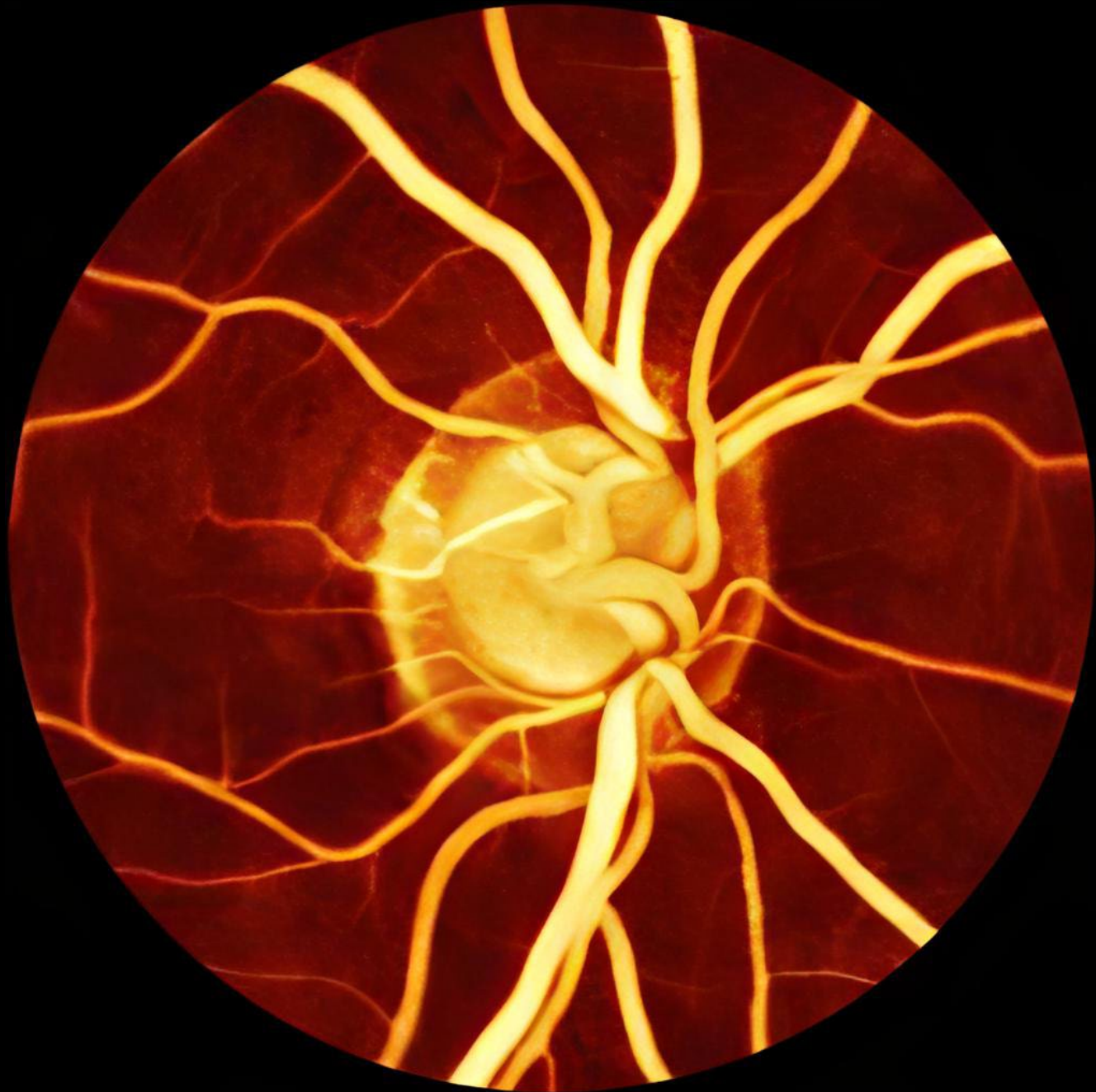
The Eye as Art



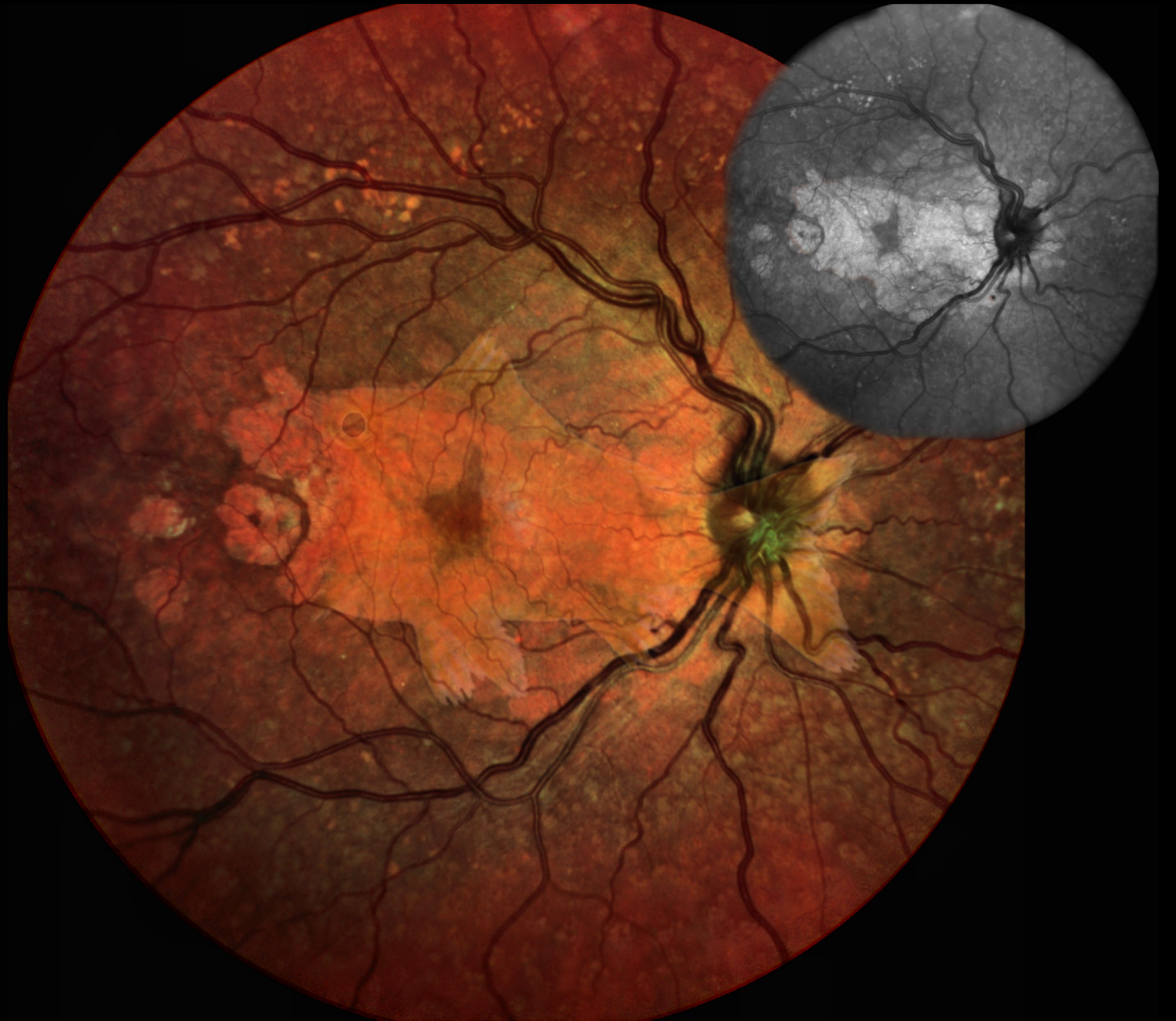Santos Klimt
Veronica Jones, BA



The Kiss, Gustav Klimt



The Flow of Molten Gold
Prasanna Ramesh, MS, DNB



Fish Food "Pisciform Lesion"

Bryan Carmichael BSc, OSA, CST, COT



The Arctic Circle:
Capsular Phimosis
Kumar Doctor, MD
Shivani Pattnaik, MS



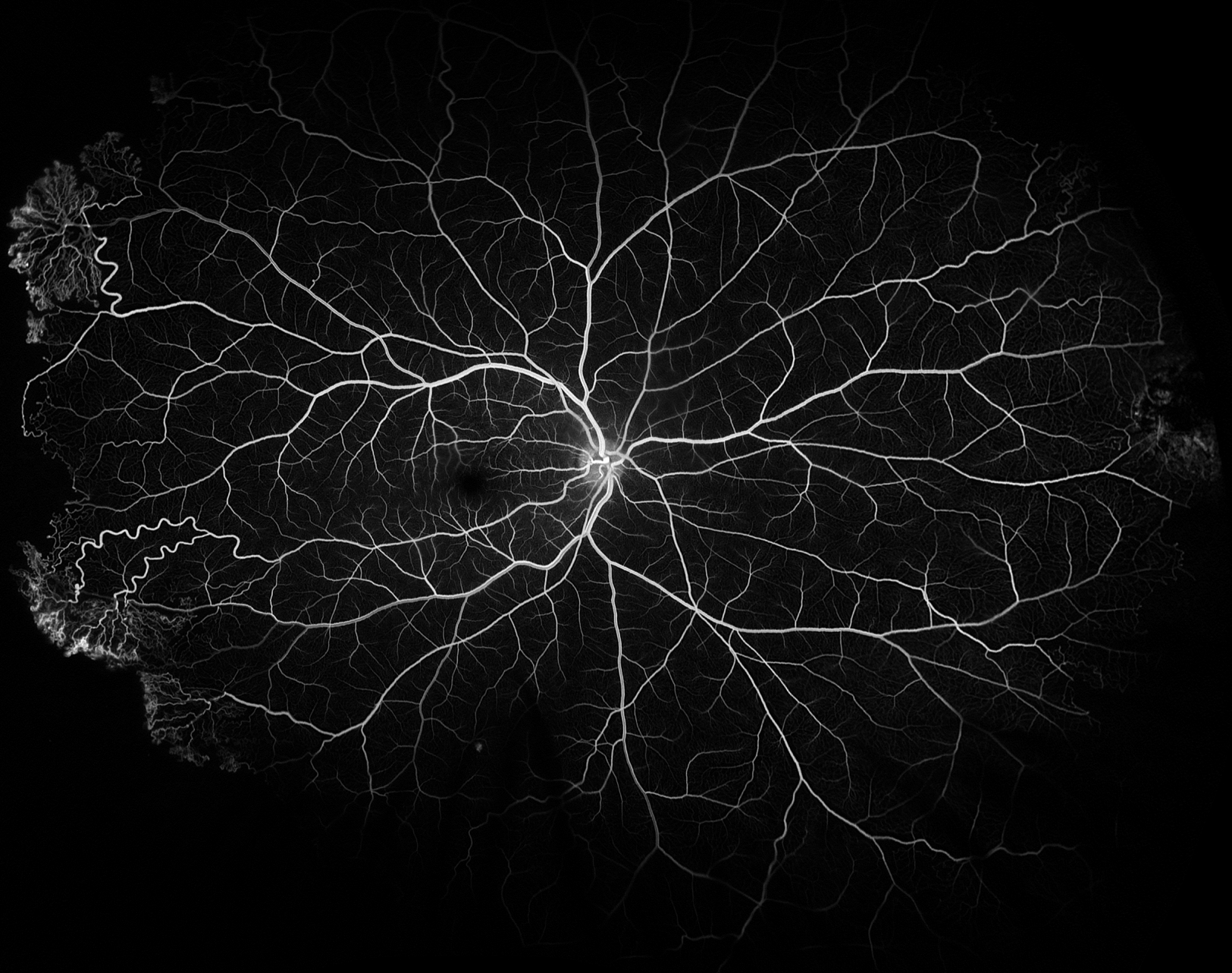
**Visual Flower - Iris Patterned
Petals**

Prasanna Ramesh, MS, DNB

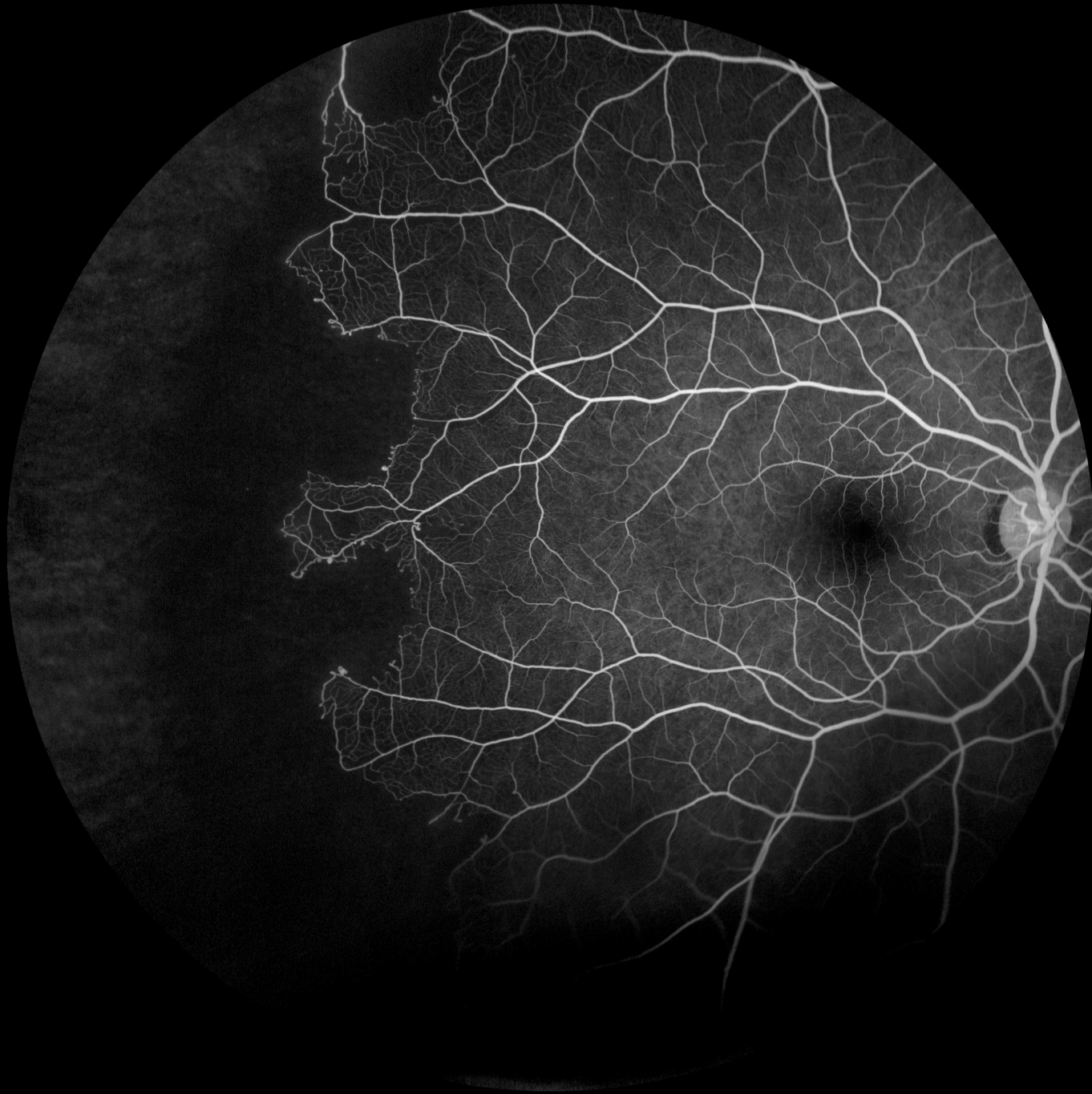




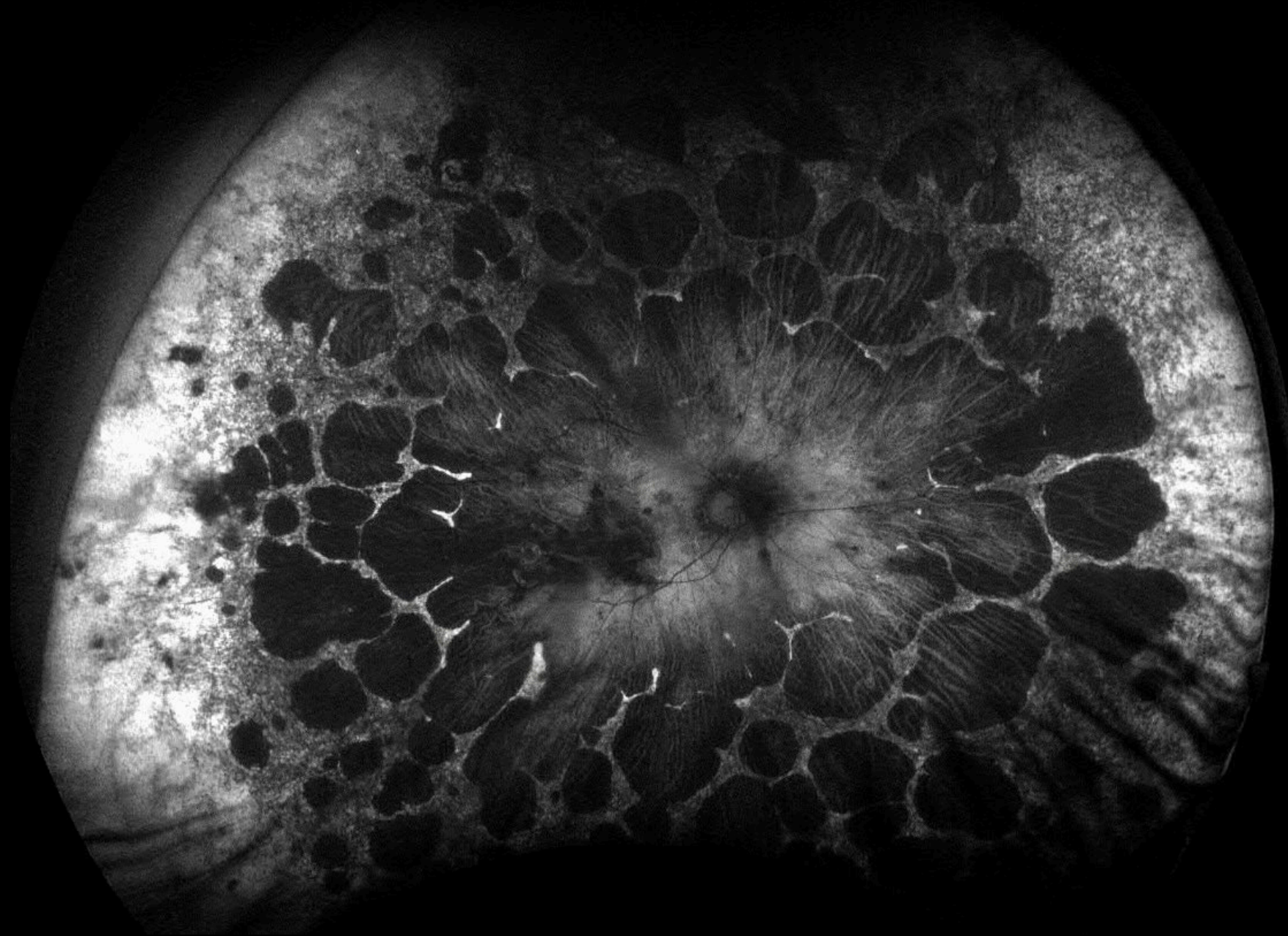
**Ultra-Widefield Imaging $>60^\circ$
(all modalities)**



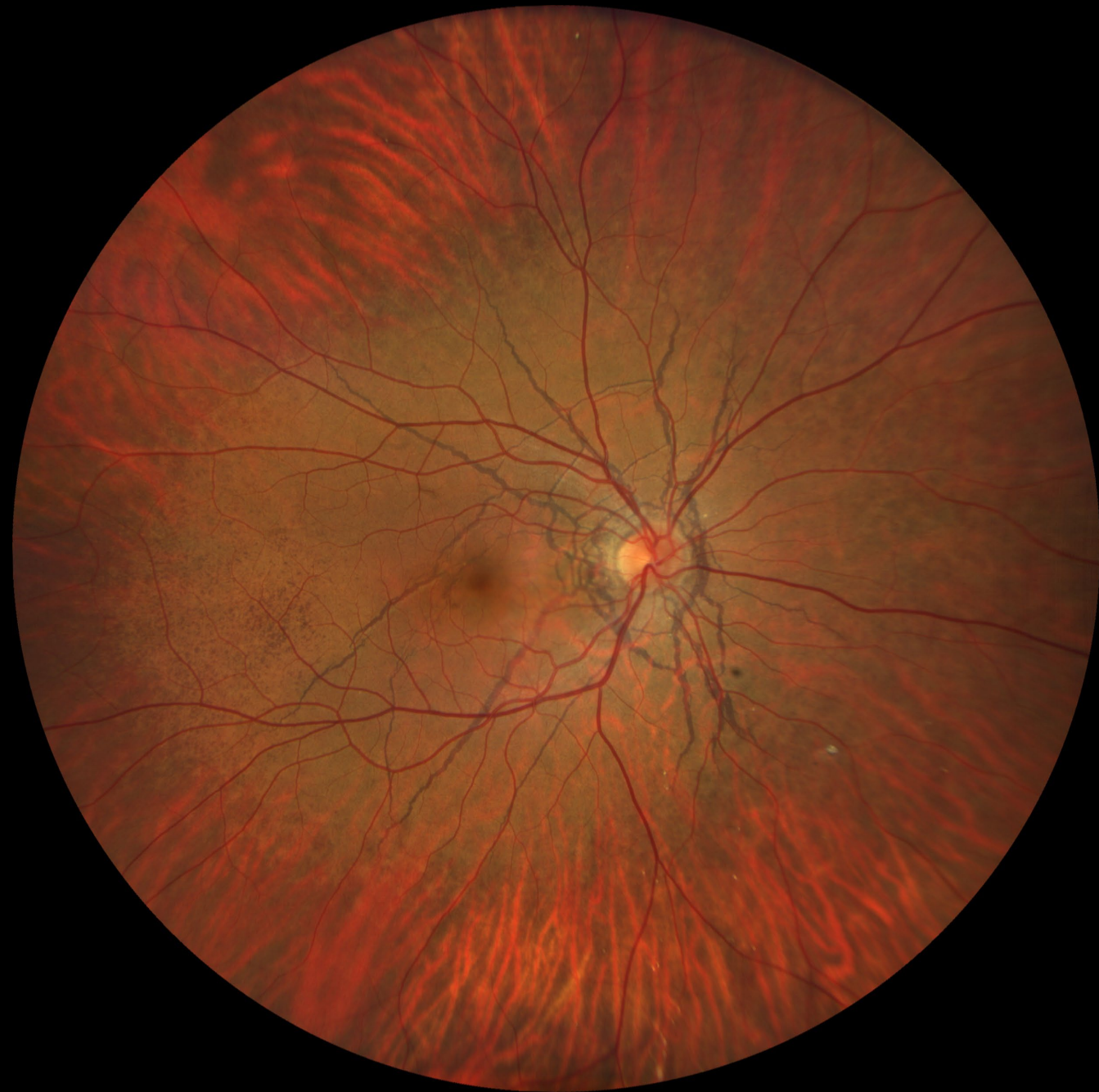Sickle Cell Disease
Judith Gulian, BSc



Capillary Dropout
Bradley Stern, BA, CRA

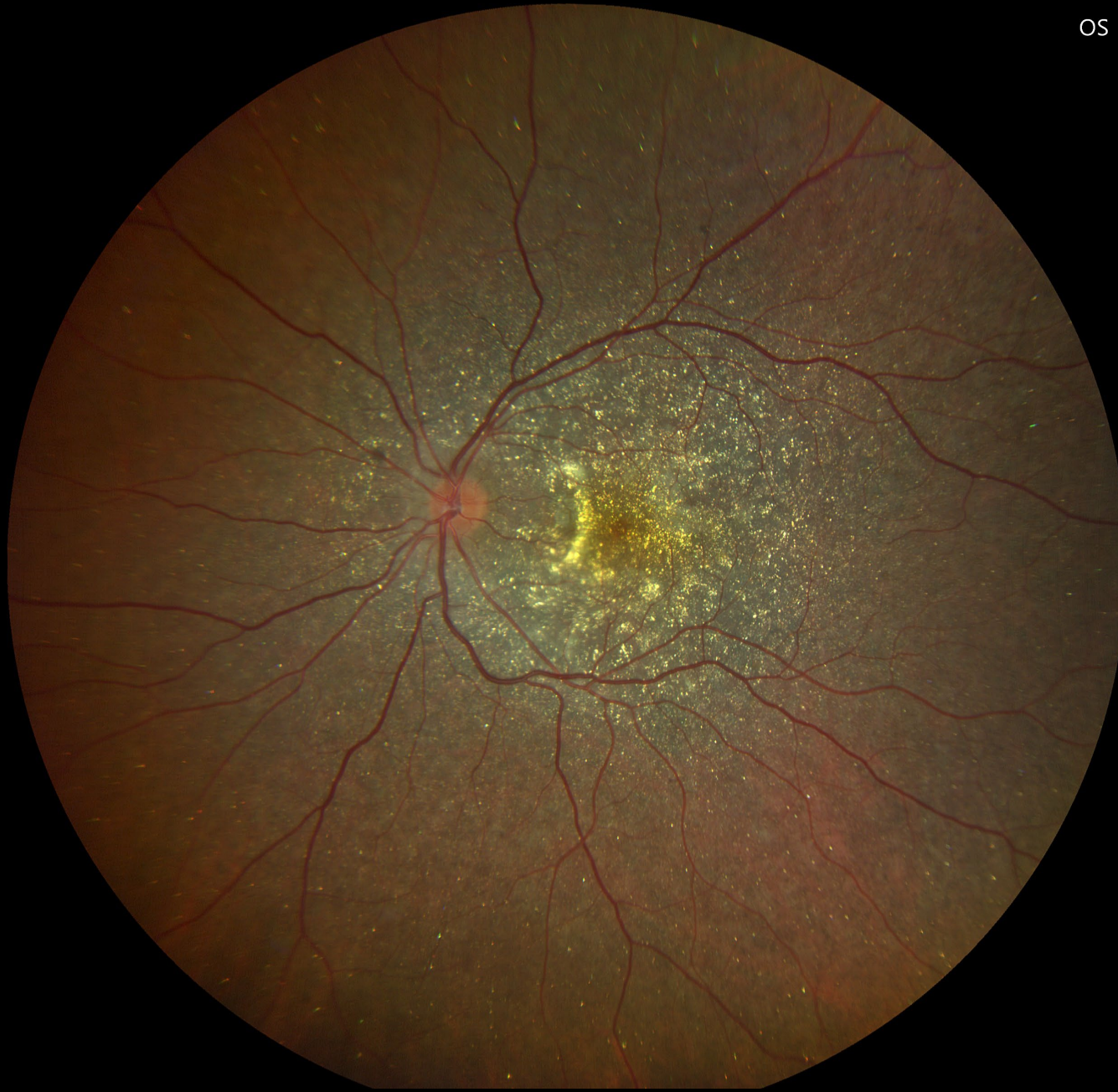

**Pigmented
Retinochoroidal Atrophy**
Jason Calhoun, COA

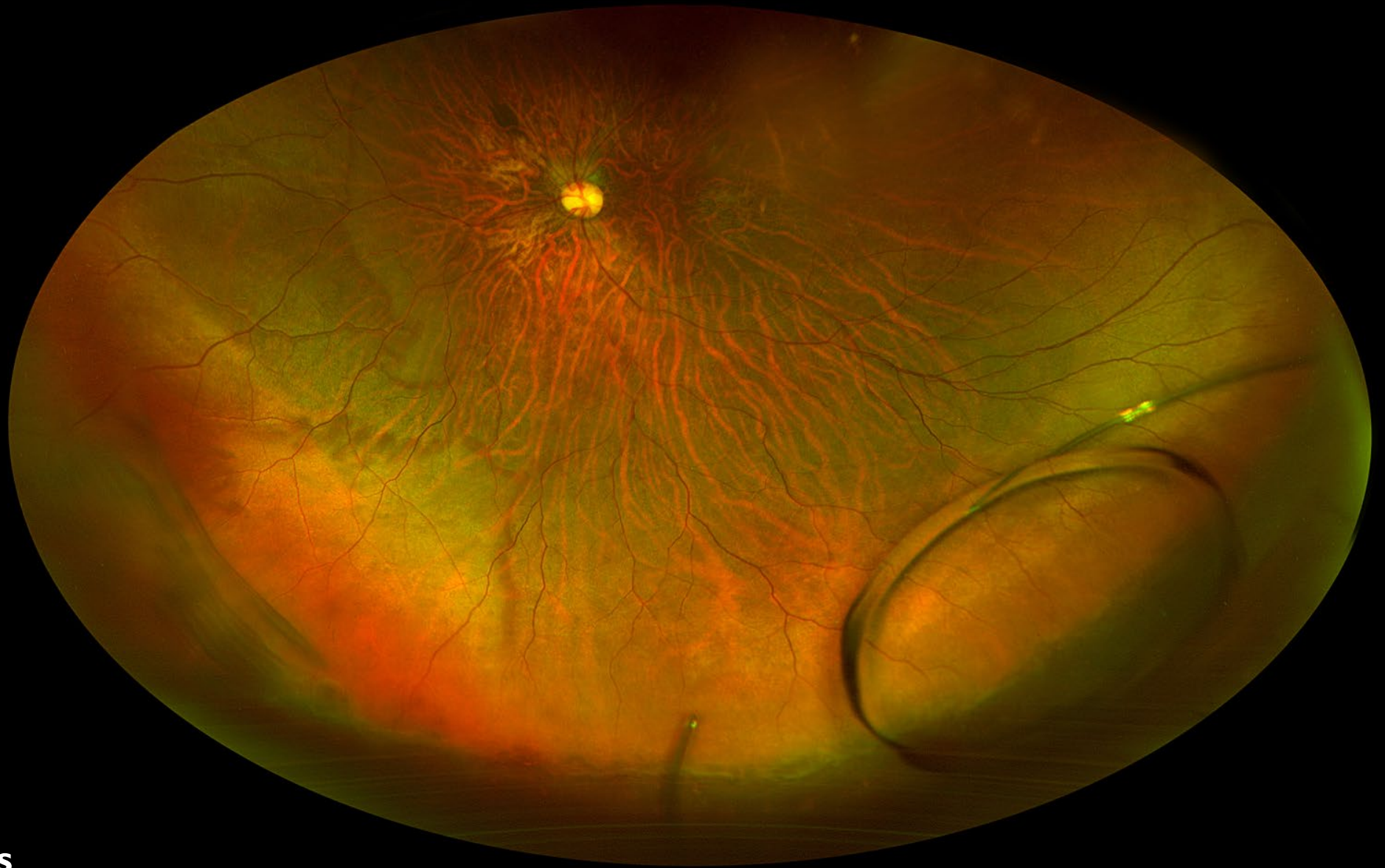

Angiod Streaks
Tracey Troszak, CRA

OS



Bietti's Crystalline Retinopathy
Lisa Spraragen, MA, COA



Dislocated Lens

Teesha McClam, BSc, OCT-C, COT

Thank you to the OPS Judges:

Lori Snyder, M.D.

Dennis Cain, CRA

Stuart Alfred, B.S.

James Strong, CRA, OCT-C